

## Communication

# Digit Entrapment Due to Plastic Waste in a Verreaux's Eagle Owl (*Bubo lacteus*)

Lindsay Thomas \*, Phillipa Dobbs and Samantha Ashfield

Twycross Zoo, A444 Burton Road, Junction 11, Atherstone CV9 3PX, UK

\* Correspondence: lindsay.thomas@twycrosszoo.org

**Abstract:** Plastic waste has become a hot topic in sustainability and conservation, helped in part by popular documentaries which have highlighted the issue to the general public. Much of the current literature focuses on the effect of microplastics in the marine environment, with very little information on macroplastic interactions or the terrestrial environment. In this report, the management of digit constriction due to macroplastic debris in a Verreaux's eagle owl (*Bubo lacteus*) is presented, and the role of zoos in decreasing littering behaviour both within the collection and in the wider global context is discussed.

**Keywords:** Verreaux's eagle owl; *Bubo lacteus*; macroplastic; litter; digit constriction



**Citation:** Thomas, L.; Dobbs, P.; Ashfield, S. Digit Entrapment Due to Plastic Waste in a Verreaux's Eagle Owl (*Bubo lacteus*). *J. Zool. Bot. Gard.* **2022**, *3*, 442–447. <https://doi.org/10.3390/jzbg3030033>

Academic Editors: Kris Descovich, Caralyn Kemp and Jessica Rendle

Received: 30 May 2022

Accepted: 12 September 2022

Published: 15 September 2022

**Publisher's Note:** MDPI stays neutral with regard to jurisdictional claims in published maps and institutional affiliations.



**Copyright:** © 2022 by the authors. Licensee MDPI, Basel, Switzerland. This article is an open access article distributed under the terms and conditions of the Creative Commons Attribution (CC BY) license (<https://creativecommons.org/licenses/by/4.0/>).

## 1. Introduction

The issue of plastic waste and its impact on wildlife species has become one of the most pressing environmental issues of recent times, in part due to popular documentaries such as *Blue Planet II* which have highlighted the issue to the general public [1,2]. The primary focus for both the public and policymakers has been marine microplastics, with relatively little focus on terrestrial and macroplastic pollution [3,4].

The effects of plastic pollution on wildlife species have been widely reported in the literature, from invertebrates [5] to megavertebrates [6], on both land [7] and in the oceans [8]. While microplastics can have a combination of chemical and physical effects on organisms which interact with them, macroplastics have primarily physical effects [7]. Birds appear particularly at risk of negative interactions with macroplastic debris, with ingestion and entrapment being the two most commonly reported negative interactions [4,9]. Accumulation of litter, including macroplastic debris, in nests is also very common and may have negative, positive or net neutral implications [4].

Although anecdotal interactions with litter are not uncommon in zoo-housed species, there is little published information available [10]. Whilst wildlife species residing in zoological collections are protected from most anthropogenic threats, for example, habitat degradation and climate change, they are also brought into close contact with humans and the risks associated therein, including exposure to anthropogenic litter. Furthermore, these species frequently demonstrate cryptic behaviour which can make it difficult to assess the need for intervention where an interaction has occurred.

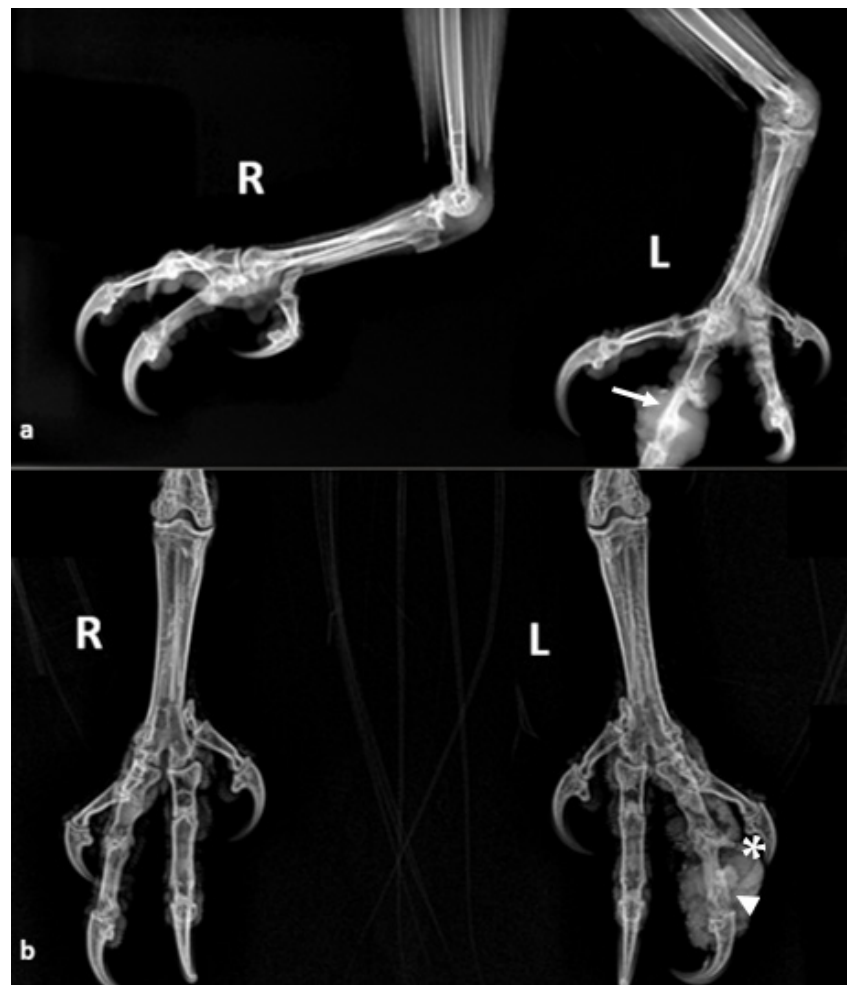
This report describes the management of a case of digit entrapment due to macroplastic debris in a zoo-housed Verreaux's eagle owl (*Bubo lacteus*) and discusses the wider issues of littering and how zoos can influence this behaviour amongst visitors.

## 2. Case Description

A male 14-months-old Verreaux's eagle owl was presented by keeping staff after blood was noticed around one of his digits. On examination, a white plastic cable was found embedded in the tissue around digit three on the left foot. Oral analgesia (meloxicam 0.2 mg/kg; Metacam, Boehringer Ingelheim, Berkshire, UK) and an antibiotic (enrofloxacin

10 mg/kg; Baytril, Bayer, Reading, UK) was prescribed by the locum vet who was on call and anaesthesia for further investigation and cable removal was scheduled for the following day.

Anaesthesia was induced with 8% sevoflurane in oxygen via a facemask. The animal was intubated with a size 3.5 mm endotracheal tube and anaesthesia maintained on 4–6% sevoflurane via a T-piece circuit. On examination, the animal was found to be in good body condition with no abnormalities other than the cable tie encircling digit three of the left foot. The tissue underlying the cable tie was necrotic and the surrounding tissue was inflamed and oedematous. Butorphanol was given by intramuscular injection at a dose of 1 mg/kg (Tobugesic, Zoetis UK, Surrey, UK) and radiographs were taken prior to removal of the cable tie (Figure 1).

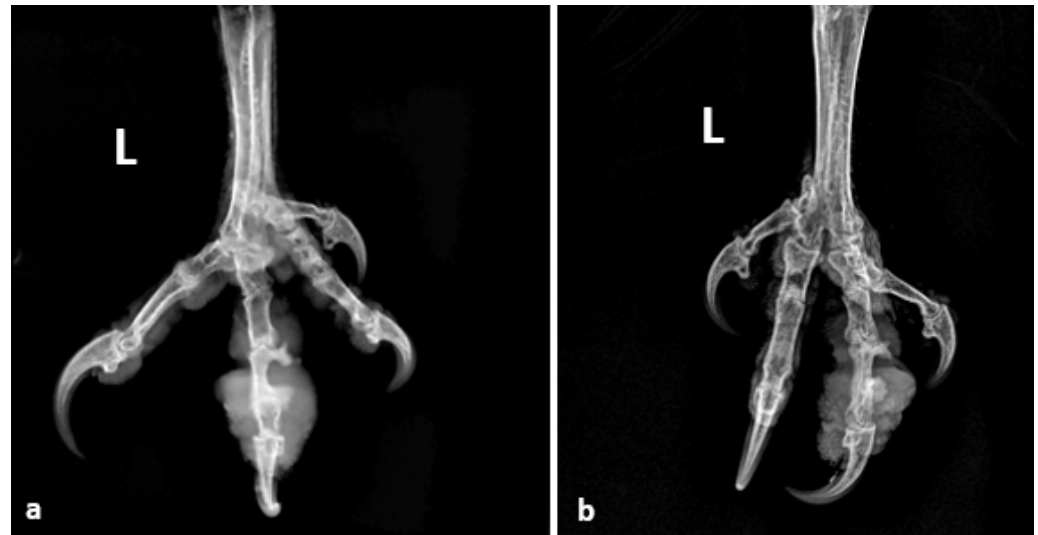


**Figure 1.** Verreaux's eagle owl feet pretreatment. Lateral (a) and dorsoplantar (b) radiographs taken prior to removal of the cable tie showing changes to phalanx 2 of digit three in the left foot. There is narrowing of the bone (white arrow) compared with the bone of the contralateral foot and osteolysis is present (white arrowhead). Osteophyte formation can be appreciated at both ends of the bone, particularly the proximal end (white asterisk).

Lateral and dorsoplantar views of both feet showed no abnormalities of the right foot; however, digit three of the left foot showed narrowing of the central part of phalanx 2 with some evidence of osteolysis and some osteophyte formation at the ends of phalanx 2, particularly the proximal end.

A low-speed dental burr (Cocoon spray dental unit, Eickmeyer, Surrey, UK) was used to carefully remove the embedded cable tie while flushing was performed with

room temperature Hartmann's solution (Aquapharm No.11, Animalcare UK, York, UK) to avoid overheating and thermal necrosis of the surrounding tissue. Once the cable tie was removed, the wound was flushed with 100 mL of additional fluid and laser treatment was performed with a class 3B laser (Xp mobile, Omega laser systems, Essex, UK). Very little tissue remained overlying P2 once the cable tie had been removed, so post-removal radiographs were performed to ensure the bone had remained intact (Figure 2).



**Figure 2.** Verreaux's eagle owl feet immediately following removal of the cable tie. Lateral (a) and DP (b) radiographs taken following removal of the cable tie to ensure no fractures had occurred during the removal process.

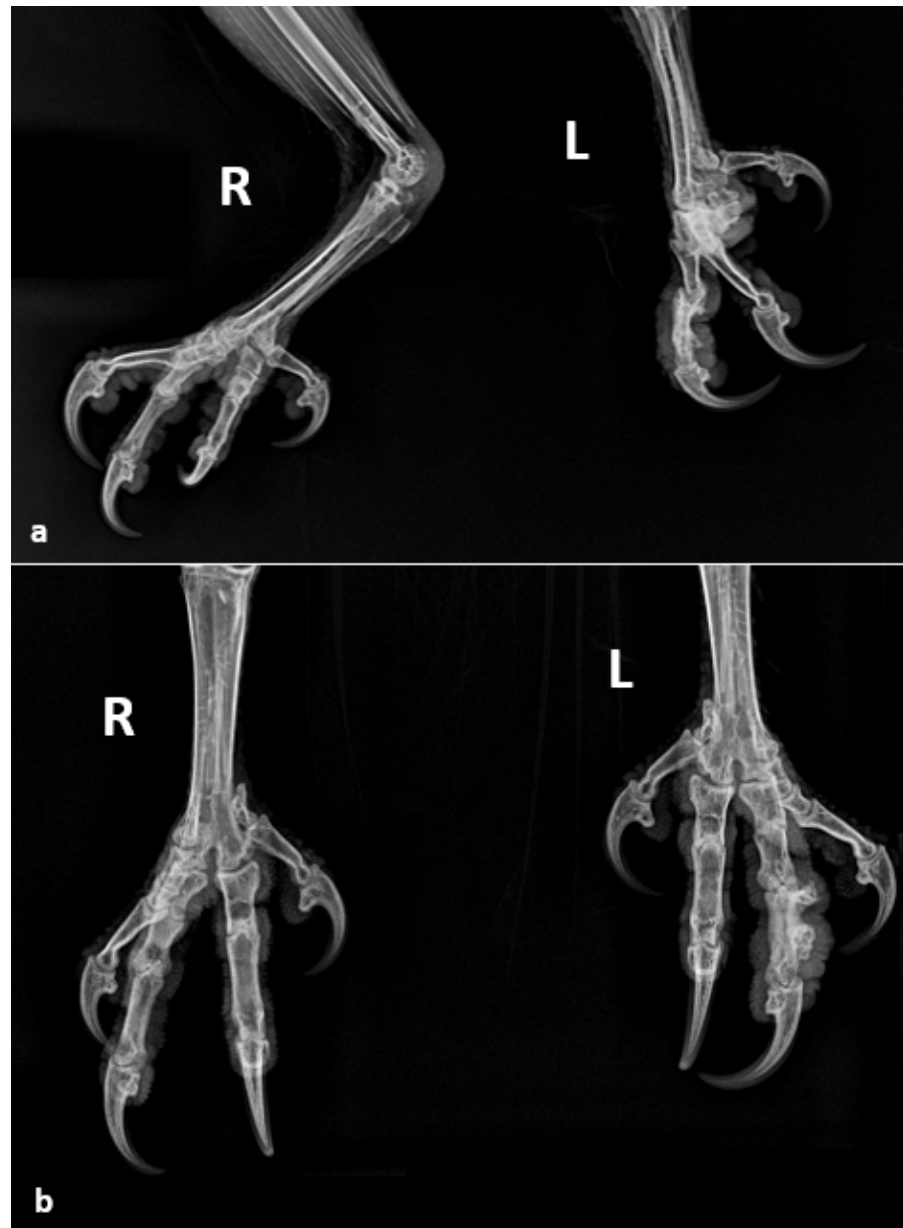Postoperatively, the animal was given oral meloxicam 0.5 mg/kg (Loxicom, Norbrook, Corby, UK), tramadol 10 mg/kg (Tramadol oral drops, MercuryPharma, Croydon, UK), marbofloxacin 12 mg/kg (Marbocare, Animalcare UK, York, UK), and prophylactic itraconazole 10 mg/kg (Itraconazole capsules, Glenmark Pharmaceuticals Europe Ltd., Watford, UK) while receiving antibiotic treatment. Medication was administered in food to minimise stress from handling; however, due to the feeding ecology of this species, this did mean that the medication could be administered only once daily. For this reason, the antibiotic was switched from enrofloxacin, which should be administered twice daily in most avian species, to marbofloxacin, to reduce the risk of antimicrobial resistance with inappropriate dosing intervals. He was kept separate from his mate to allow accurate monitoring of medication intake.

The animal was monitored closely in the postoperative period to ensure the digit swelling was reducing, primarily through the use of binoculars to allow visual assessment of the wound without stressing him through regular capture events. Appetite was also monitored closely, as stress from both capture events and foot injuries have the potential to decrease food intake in owls (J. Mihr, personal communication). Food pieces were counted in and out, with appetite remaining stable throughout the treatment period. Every fourteen days, he was captured for physical examination of the affected digit. Six weeks postoperatively, anaesthesia was repeated using the same protocol and repeat radiographs were taken of both feet (Figure 3), as well as standard right lateral and ventrodorsal whole-body views.

Radiographs revealed no abnormalities of the right foot. On the left foot, phalanx 2 of digit three had increased in width and now exceeded that seen on the same bone in the right foot. The osteolysis which had been apparent six weeks previously appeared to have resolved, and while osteophytes were still present at both ends of phalanx 2 and, in particular, the proximal end, they appeared less obvious than previous. The tissue deficit

was largely resolved by this point, and clinically there was no evidence of any further infection, necrotic tissue or pain.

The osteolysis of phalanx 2 in digit three on the left foot had resolved. Osteophytes were still appreciable, particularly at the proximal end of the bone, but the width of the bone had increased to exceed that of the contralateral foot.



**Figure 3.** Verreaux's eagle owl feet six weeks post-treatment. Lateral (a) and DP (b) follow-up radiographs taken six weeks post-removal of the cable tie.

### 3. Discussion

Constriction injuries in captive birds are most commonly seen as a result of improperly placed identification rings, which can cause significant trauma, and, in some cases, even result in the loss of affected limbs [11]. Digit constriction in captive avian species is most commonly reported as a result of fibres wrapping around the digit, low humidity leading to annular ring formation and circumferential wounds leading to scab/fibrotic tissue formation [12]. Entrapment and constriction injuries have previously been reported in free-living wildlife species, for example, plastic strings incorporated into nests were reported

to cause entrapment and degeneration of leg bones in juvenile white storks presented to two wildlife rehabilitation centres in Poland [13]. However, to the author's knowledge, this is the first published report of a constriction injury in a zoo-housed wildlife species due to anthropogenic litter.

The source of the cable tie was unknown in this case, as it did not match the type used by collection staff and no cable ties were in use within the enclosure that the animal inhabited. Possible sources include accidental inclusion in wood chip bedding material used in the enclosure or littering by a member of the public. Other cases of interactions with anthropogenic litter have previously been observed in this collection. A metal coin was found in the ventriculus on postmortem examination of a Humboldt penguin (*Spheniscus humboldti*) but was not a contributing factor to mortality. The source of the coin was thought to be visitors throwing money into the penguin pool, as this had been observed on multiple occasions despite signage discouraging this behaviour. In another case, a De Brazza monkey (*Cercopithecus neglectus*) was found to have a plastic bottle cap impacted into a cheek pouch. The source of the bottle cap was, again, thought to be littering by members of the public.

Littering is a major global issue with widespread consequences for both human and non-human health and welfare [14]. There are many published studies available investigating a variety of factors which influence littering behaviour, including situational factors, such as the presence of litter bins or the amount of pre-existing litter in an area, and societal/psychological factors, such as the behaviour of other individuals or the presence of signage discouraging littering behaviour [14].

Signs have been shown to be effective deterrents for antisocial behaviour such as littering [14]; however, littering continues to be a problem within the collection despite the presence of signage. Research has shown that including a brief explanation as to why a behaviour is prohibited and the addition of 'watching eyes' images can increase the efficacy of signage but will not completely eliminate the antisocial behaviour [15] and may increase the incidence of other 'displacement' behaviours which may also be antisocial [16]. The presence of litter bins has been shown to decrease littering; however, the design and positioning of the litter bin as well as associated signage may have a significant impact on their use [17,18]. Review of current signage and litter bins may aid in decreasing incidences of littering within the collection.

Anthropogenic litter can impact wildlife species via various routes. Senko et al. (2020) reviewed studies published between 1969 and 2020 reporting the effects of plastic pollution of marine megafauna and highlighted nine 'pathways' for interactions between marine megafauna and plastic pollution, including entanglement, ingestion and increased exposure to contaminants [19]. Bletter and Mitchell 2021 documented 90 individual cases of encounters between macroplastic waste and freshwater and terrestrial species and noted that plastic entanglement was the second most common encounter, the most common being the use of plastic for nesting material [4]. Entanglements may have negative effects by reducing mobility and, therefore, the ability to ingest food or escape predation, or, as in this case, leading to physical injury via constriction [4].

In addition to decreasing on-site littering and, therefore, the potential negative effects on collection animals, zoos can also play an important role in educating the public on the wider issues of littering and plastic pollution. Mellish et. al. (2019) reported a positive change in attitudes towards balloon litter and the use of balloons at outdoor events after visitors viewed an exhibit, with or without an accompanying presentation, on this issue [20]. However, few other studies have specifically looked at the effect and outcome of targeted pollution education programmes, despite studies suggesting that the majority of zoo visitors are willing to engage with learning during their visit [21].

#### 4. Conclusions

Zoos have an important role to play in highlighting the dangers of anthropogenic litter and the effect this can have on wildlife species, both in captivity and in the wild. The cryptic behaviour displayed by many wildlife species housed in zoos can make management of



cases such as the one discussed here difficult, and so risk reduction by both decreasing littering on an individual collection basis and by educating the public on the wider risks associated with litter and plastic pollution is of paramount importance.

**Funding:** This research received no external funding.

**Institutional Review Board Statement:** Not applicable.

**Data Availability Statement:** Not applicable.

**Acknowledgments:** The authors would like to give thanks to the bird team at Twycross zoo, without whose care this case would have had a very different outcome.

**Conflicts of Interest:** The authors declare no conflict of interest.

## References

1. Males, J.; Van Aelst, P. Did the Blue Planet set the Agenda for Plastic Pollution? An Explorative Study on the Influence of a Documentary on the Public, Media and Political Agendas. *Environ. Commun.* **2020**, *15*, 40–54. [\[CrossRef\]](#)
2. Bailey, I. Media coverage, attention cycles and the governance of plastics pollution. In *Environmental Policy and Governance*; Wiley: Hoboken, NJ, USA, 2022; pp. 1–13. [\[CrossRef\]](#)
3. Malizia, A.; Monmany-Garzia, A.C. Terrestrial ecologists should stop ignoring plastic pollution in the Anthropocene time. *Sci. Total Environ.* **2019**, *668*, 1025–1029. [\[CrossRef\]](#) [\[PubMed\]](#)
4. Blettler, M.C.; Mitchell, C. Dangerous traps: Macroplastic encounters affecting freshwater and terrestrial wildlife. *Sci. Total Environ.* **2021**, *798*, 149317. [\[CrossRef\]](#) [\[PubMed\]](#)
5. Sussarellu, R.; Suquet, M.; Thomas, Y.; Lambert, C.; Fabioux, C.; Pernet, M.E.; Le Goïc, N.; Quillien, V.; Mingant, C.; Epelboin, Y.; et al. Oyster reproduction is affected by exposure to polystyrene microplastics. *Proc. Natl. Acad. Sci. USA* **2016**, *113*, 2430–2435. [\[CrossRef\]](#) [\[PubMed\]](#)
6. Fossi, M.C.; Panti, C.; Baini, M.; Lavers, J.L. A review of plastic-associated pressures: Cetaceans of the Mediterranean Sea and eastern Australian shearwaters as case studies. *Front. Mar. Sci.* **2018**, *5*, 173. [\[CrossRef\]](#)
7. De Souza Machado, A.A.; Kloas, W.; Zarfl, C.; Hempel, S.; Rillig, M.C. Microplastics as an emerging threat to terrestrial ecosystems. *Glob. Chang. Biol.* **2018**, *24*, 1405–1416. [\[CrossRef\]](#) [\[PubMed\]](#)
8. Li, W.C.; Tse, H.F.; Fok, L. Plastic waste in the marine environment: A review of sources, occurrence and effects. *Sci. Total Environ.* **2016**, *566*, 333–349. [\[CrossRef\]](#) [\[PubMed\]](#)
9. Battisti, C.; Staffieri, E.; Poeta, G.; Sorace, A.; Luiselli, L.; Amori, G. Interactions between anthropogenic litter and birds: A global review with a ‘black-list’ of species. *Mar. Pollut. Bull.* **2019**, *138*, 93–114. [\[CrossRef\]](#) [\[PubMed\]](#)
10. Malepa, P.L. Visitor Perceptions and Awareness of Litter at the Johannesburg ZOO. Doctoral Dissertation, University of South Africa, Pretoria, South Africa, 2014.
11. Montesinos, A. Basic techniques. In *BSAVA Manual of Avian Practice*; BSAVA Library: Gloucester, UK, 2018; pp. 215–231. [\[CrossRef\]](#)
12. Guzman, D.S. Avian soft tissue surgery. *Vet. Clin. Exot. Anim. Pract.* **2016**, *19*, 133–157. [\[CrossRef\]](#) [\[PubMed\]](#)
13. Kwieciński, Z.; Kwiecińska, H.; Botko, P.; Wysocki, A.; Jerzak, L.; Tryjanowski, P. Plastic strings as the cause of leg bone degeneration in the White Stork (*Ciconia ciconia*). In *White Stork Study in Poland: Biology, Ecology and Conservation*; Bogucki Wydawnictwo Naukowe: Poznań, Poland, 2006.
14. Chaudhary, A.H.; Polonsky, M.J.; McClaren, N. Littering behaviour: A systematic review. *Int. J. Consum. Stud.* **2021**, *45*, 478–510. [\[CrossRef\]](#)
15. Ernest-Jones, M.; Nettle, D.; Bateson, M. Effects of eye images on everyday cooperative behavior: A field experiment. *Evol. Hum. Behav.* **2011**, *32*, 172–178. [\[CrossRef\]](#)
16. Parker, E.N.; Bramley, L.; Scott, L.; Marshall, A.R.; Slocombe, K.E. An exploration into the efficacy of public warning signs: A zoo case study. *PLoS ONE* **2018**, *13*, 0207246. [\[CrossRef\]](#)
17. Portman, M.E.; Behar, D. Influencing beach littering behaviors through infrastructure design: An in situ experimentation case study. *Mar. Pollut. Bull.* **2020**, *156*, 111277. [\[CrossRef\]](#)
18. Johannes, H.P.; Maulana, R.; Herdiansyah, H. Prevention of Littering through Improved Visual Design. *Environ. Res. Eng. Manag.* **2021**, *77*, 86–98. [\[CrossRef\]](#)
19. Senko, J.F.; Nelms, S.E.; Reavis, J.L.; Witherington, B.; Godley, B.J.; Wallace, B.P. Understanding individual and population-level effects of plastic pollution on marine megafauna. *Endanger. Species Res.* **2020**, *43*, 234–252. [\[CrossRef\]](#)
20. Mellish, S.; Pearson, E.L.; McLeod, E.M.; Tuckey, M.R.; Ryan, J.C. What goes up must come down: An evaluation of a zoo conservation-education program for balloon litter on visitor understanding, attitudes, and behaviour. *J. Sustain. Tour.* **2019**, *27*, 1393–1415. [\[CrossRef\]](#)
21. Roe, K.; McConney, A. Do zoo visitors come to learn? An internationally comparative, mixed-methods study. *Environ. Educ. Res.* **2015**, *21*, 865–884. [\[CrossRef\]](#)