



## Case Report

# Bilateral Achilles Tendon Rupture: A Case Report and Review of the Literature

Christian A. Cruz <sup>1</sup>, Jeffrey L. Wake <sup>1</sup>, Ryan J. Bickley <sup>1</sup> , Logan Morin <sup>2</sup> , Brian J. Mannino <sup>1</sup>, Kevin P. Krul <sup>1</sup> and Paul Ryan <sup>1,\*</sup>

<sup>1</sup> Tripler Army Medical Center, Department of Orthopedic Surgery, Oahu, HI 96859, USA; chcruz93@gmail.com (C.A.C.); jeffrey.l.wake.mil@mail.mil (J.L.W.); ryan.j.bickley@gmail.com (R.J.B.); manninob@gmail.com (B.J.M.); kevin.krul@gmail.com (K.P.K.)

<sup>2</sup> Chicago College of Osteopathic Medicine, Midwestern University, Downers Grove, IL 60515, USA; lmorin62@midwestern.edu

\* Correspondence: paul.m.ryan.mil@mail.mil

**Abstract:** While Achilles tendon injuries are common amongst the general population, there are very few cases in which simultaneous bilateral injuries occur. Medial malleolar fractures at the time of Achilles tendon rupture have been cited in the literature and are commonly missed. The following case outlines the presentation, treatment, and outcome of a United States Army Soldier with simultaneous bilateral Achilles tendon ruptures in addition to a unilateral right medial malleolar fracture. This patient was able to completely return to duty within 1 year after being treated with ORIF of the medial malleolus, bilateral end-to-end repair of the AT, and accelerated rehabilitation beginning at 2 weeks on the left and 6 weeks on the right.

**Keywords:** bilateral Achilles tendon rupture; medial malleolus fracture; military return to duty; Achilles tendon rupture without risk factors



**Citation:** Cruz, C.A.; Wake, J.L.; Bickley, R.J.; Morin, L.; Mannino, B.J.; Krul, K.P.; Ryan, P. Bilateral Achilles Tendon Rupture: A Case Report and Review of the Literature. *Osteology* **2022**, *2*, 70–76. <https://doi.org/10.3390/osteology2020008>

Academic Editor: Rodolfo Gómez Bahamonde

Received: 23 January 2022

Accepted: 20 April 2022

Published: 26 April 2022

**Publisher's Note:** MDPI stays neutral with regard to jurisdictional claims in published maps and institutional affiliations.



**Copyright:** © 2022 by the authors. Licensee MDPI, Basel, Switzerland. This article is an open access article distributed under the terms and conditions of the Creative Commons Attribution (CC BY) license (<https://creativecommons.org/licenses/by/4.0/>).

## 1. Introduction

Achilles tendon (AT) rupture is a common sport-related injury which results in sudden and severe disability. Studies have demonstrated that AT injuries are most common in men aged 30 to 50 but have been increasing across all age groups [1]. The AT is the largest and strongest tendon in the human body and is integral in knee flexion, foot plantar flexion, and hind foot inversion [2]. The gastrocnemius and soleus converge into the AT approximately 5 to 6 cm from its insertion at the calcaneal tuberosity. The tendon rotates 90 degrees about a vertical axis so that the medial fibers end posteriorly; this creates an efficient elastic recoil. While this is energy efficient, it also creates a stress riser 2 to 5 cm proximal to the calcaneal insertion. This area of the tendon coincides with the vascular watershed which is compromised in 75% of acute AT ruptures [3].

Injuries to the AT are often multifactorial, involving intrinsic and extrinsic factors. Intrinsic factors include age, weight, functional status, and chronic degeneration. Extrinsic factors include participation in sport, use/overuse, fluoroquinolone antibiotic use, and corticosteroid use [4]. Traditionally, two mechanisms have been proposed to explain the etiology of AT rupture. First, Arner et al. suggested that chronic degeneration can lead to rupture without the need for excessive force [5]. Barfred et al. proposed that AT rupture in healthy, non-degenerated tendons is most likely to occur when the tendon is obliquely loaded at a short initial length with maximal muscle contraction, such as in pushing off activities [6].

Bilateral traumatic AT ruptures are rare, with an overall incidence of <1% [7]. The majority of previous case reports identify a known risk factor that has predisposed a patient to this rare occurrence [8–13]. There are limited reports of bilateral AT ruptures in young, healthy individuals [14]. The management of these injuries is notoriously difficult due

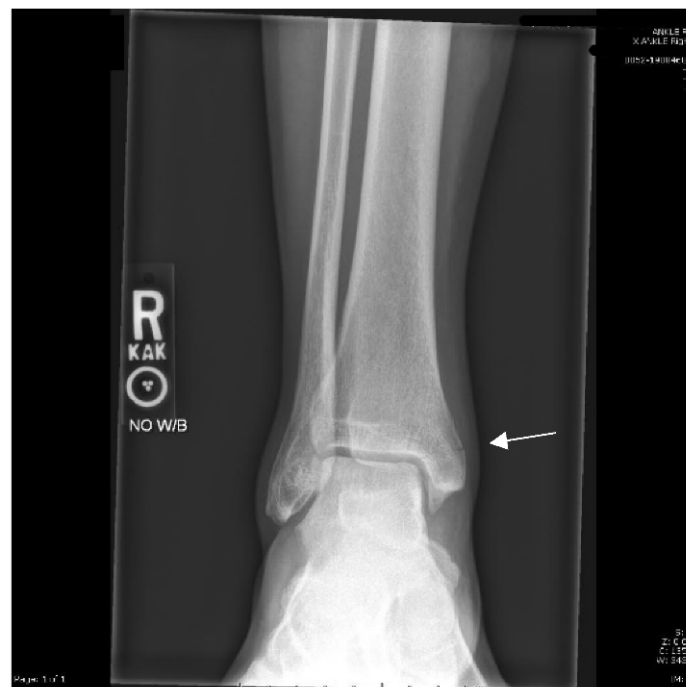to the severe disability associated with the bilateral nature. To our knowledge, this is the first reported case of a young, healthy, active duty United States (US) military male with spontaneous bilateral traumatic AT ruptures and unilateral medial malleolus fracture without known risk factors. We will outline the treatment we chose and its ultimate outcome in the case presentation below.

## 2. Case Presentation

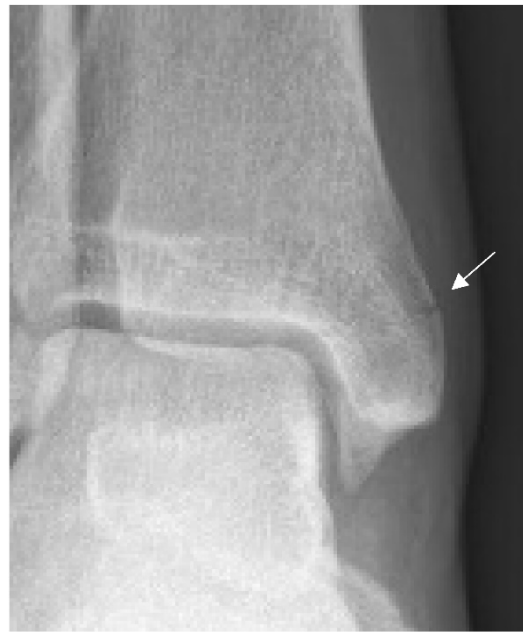A 34-year-old active duty US military male presented to the emergency department after attempting to perform a back flip. He landed on the plantar aspect of his forefoot and his ankle rapidly dorsiflexed against his resistance. At this time, he felt pops bilaterally about his AT's. He reported significant pain about the AT bilaterally as well as pain about the medial aspect of the right ankle. On physical exam, he had palpable defects about the AT bilaterally. The defect was 7 cm proximal to the calcaneal insertion on the left and 6 cm proximal on the right. He was unable to plantar flex either foot, he had a positive Thompson's squeeze test bilaterally, and he had a symmetric Matles test. Additionally, he had significant bony tenderness to palpation about the medial malleolus of the right ankle.

The patient was previously healthy, exercised regularly, and consistently passed the Army Physical Fitness Test (APFT). He denied any recent fluoroquinolone or corticosteroid use. He denied any antecedent pain or significant past medical history. He denied any family history of collagen disorder. He did, however, report a previous provoked deep venous thrombosis (DVT) after a femoral shaft fracture 5 years prior. Routine laboratory work-up was within normal limits. Prior to discharge from the emergency department, the patient was given a prescription for Lovenox, and a consult to Internal Medicine was placed for recommendations regarding post-operative anticoagulation.

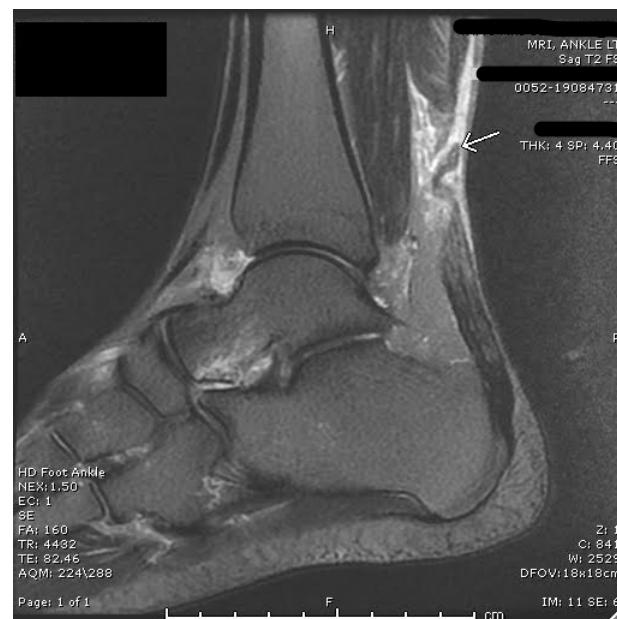Radiographs demonstrated a non-displaced transverse fracture of the right medial malleolus (Figures 1 and 2). Magnetic Resonance Imaging (MRI) of the right ankle revealed a complete, full thickness tear of the AT 6 cm proximal to the calcaneal insertion as well as a non-displaced fracture of the medial malleolus (Figure 3). MRI of the left ankle revealed a complete, full thickness tear 7 cm proximal to the calcaneal insertion (Figure 4).



**Figure 1.** Plain AP of right ankle demonstrating medial malleolar fracture.



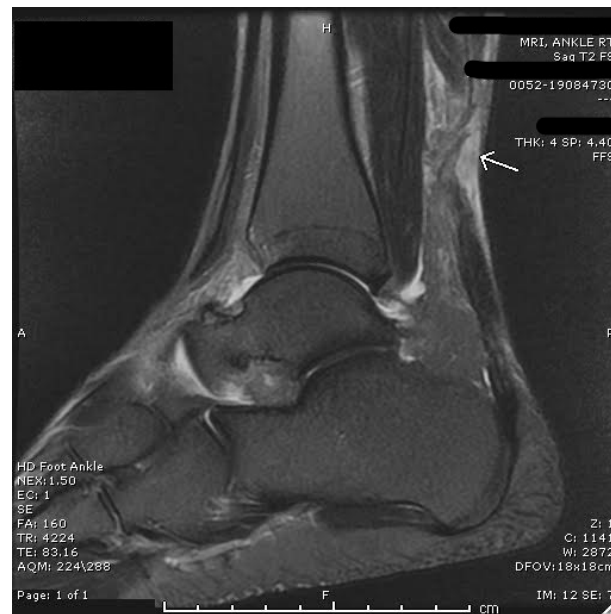**Figure 2.** Zoomed view of right ankle AP demonstrating medial malleolar fracture.



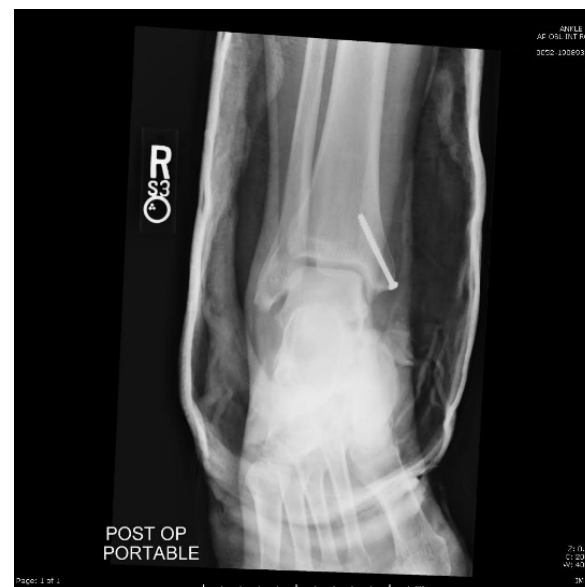**Figure 3.** MRI of left ankle demonstrating AT rupture.

The patient was taken to the operating room 4 days after injury for a bilateral AT repair as well as open reduction internal fixation (ORIF) of the right medial malleolus. The patient was positioned prone with slight bilateral leg flexion and draped to expose the bilateral lower extremities. The right medial malleolus was addressed first via a medial curvilinear incision and fixed using 2 parallel 4-0 cannulated screws. Plain films demonstrated appropriate placement of screws and reduction of the ankle mortise (Figures 5 and 6). Both Achilles' tendons were repaired utilizing the same technique via dorsomedial incisions. The plantaris tendon was visualized bilaterally with no gross deformity or degeneration. There was no evidence of enthesitis or tendinopathy in other portions of the AT. Given these findings and a non-concerning history, a biopsy was not collected, and no further investigation was initiated. An end-to-end repair was performed using a #2 Fiberwire suture (Arthrex, Naples, FL, USA) and a Krackow locking loop technique. He restarted

Lovenox on post-operative day 1 and was subsequently discharged with a thirty-day course of apixaban for DVT prophylaxis per Internal Medicine recommendations.



**Figure 4.** MRI of right ankle demonstrating AT rupture.

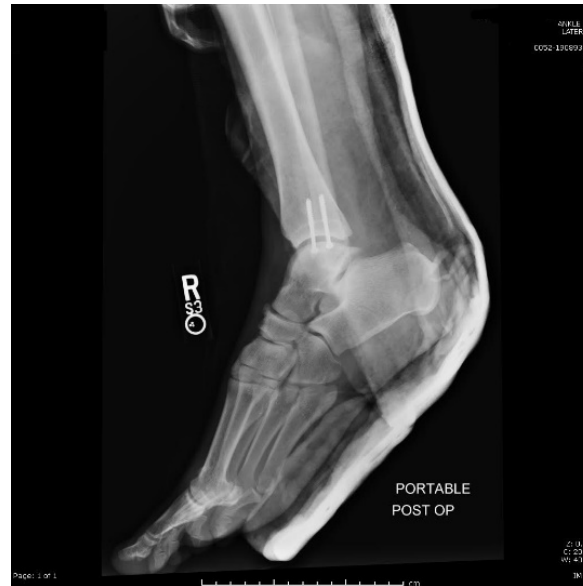

**Figure 5.** Mortise View of the right Ankle demonstrating reduced mortise and appropriate screw positioning.

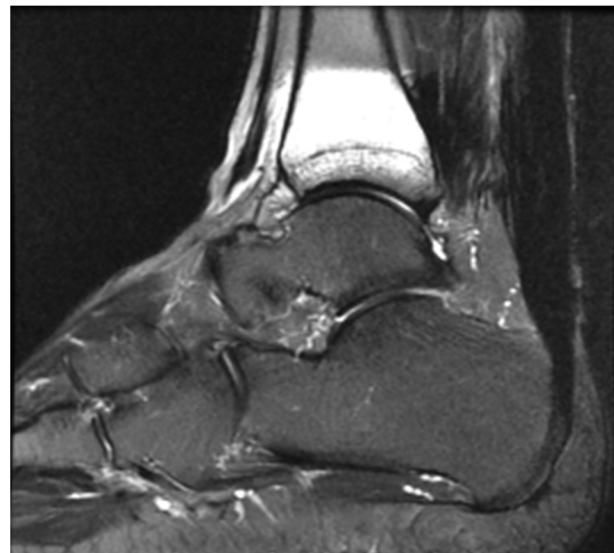
Post-operatively, the patient was splinted in plantar flexion bilaterally. He remained non-weight-bearing to bilateral lower extremities for 2 weeks. After 2 weeks of immobilization, the patient was transitioned into bilateral controlled ankle motion (CAM) boots with 3 cm heel lifts. For the left AT, the patient began the Willits functional rehabilitation protocol at 2 weeks post-operatively [15]. The patient was non-weight-bearing for six weeks on the right before beginning the Willits functional rehabilitation protocol.

At 7 months post-operatively, the patient had achieved the full range of motion in both ankles and returned to normal activities of daily living. He reported no pain about the left AT; however, he reported pain about his right posterior tibial tendon with weight bearing and range of motion. Therefore, an MRI of the right ankle was obtained. The MRI demonstrated significant tendinitis of the posterior tibial tendon and contact of the tendon with the posterior medial malleolus screw. The follow-up MRI also demonstrated a healed

right AT (Figure 7). He returned to the operating room 8 months post-operatively for removal of the medial malleolus screws. At one year post-operatively, the patient returned to running and performing his normal military requirements including passing an APFT. There were no venous thromboembolic (VTE) events during this patient's treatment. The patient provided written informed consent for publication of all information pertinent to this case.



**Figure 6.** Lateral of the right ankle demonstrating appropriate screw positioning.



**Figure 7.** MRI of right ankle demonstrating healed Achilles Tendon at 8 months post operatively.

### 3. Discussion

To our knowledge, this is the first reported case of bilateral AT ruptures in a healthy active duty US military male without known risk factors. Additionally, this is the first report of bilateral AT ruptures associated with a medial malleolus fracture.

In 2004, Hayes et al. reviewed all published cases of bilateral AT rupture and found that 13 out of 26 were due to exogenous steroid treatment and the rest due to other causes including antibiotic use [8]. Our patient did not have any of the associated risk factors identified by Hayes and did not endorse any antecedent pain. Kapoor et al. published a case report of a young healthy male without apparent risk factors in which they opted



for surgical management in one Achilles utilizing an end-to-end repair and non-operative management in the contralateral Achilles [14]. They did not progress to full weight bearing until 8 weeks following the initiation of treatment. They reported satisfactory results with the intact tendon and an ability to ambulate with full weight bearing at the 9-month follow-up. They did not comment regarding the return to preinjury activity level. We implemented the Willits protocol at 2 weeks post-injury on the left and 6 weeks post-injury on the right, which is significantly quicker than Kapoor. Our outcome was comparable to Kapoor's: full return to normal activity by 7 months, and full return to military duty after 1 year. This was achieved despite our patient requiring hardware removal at 8 months. The decision to treat AT injuries operatively vs. non-operatively is typically made after weighing the risks and benefits of each. In the case of a young, bilaterally injured patient whose job demands rigorous physical activity, operative management should strongly be considered despite the risks. This should be followed by an accelerated rehabilitation protocol to minimize the length of disability incurred by this injury.

There have been cases reported in which a unilateral AT rupture occurs with a medial malleolus fracture in the ipsilateral extremity. In case reports of these two injuries occurring together, it is noted that one of the injuries is often missed on presentation. In 2016, Lu et al. presented a case and reviewed six other cases to find that three AT ruptures and one medial malleolus fracture were missed on presentation [16]. The mechanism of injury in these cases was similar to our case, with a sudden upward force applied at the forefoot followed by hindfoot inversion stress causing a supination-adduction (SAD) injury pattern. Lu et al. opted for surgical management of the medial malleolus and nonoperative management for the AT rupture beginning at two weeks post-op. Lu's patient achieved full active and passive range of motion as well as full strength in the plantar flexion by 12 months after the date of injury. Again, our protocol achieved a comparable outcome despite the need for hardware removal.

An important aspect of this case that must not be overlooked is VTE, especially with his history of provoked DVT. The literature has shown rates of DVT from 23.4–34% following AT rupture regardless of operative or nonoperative treatment [17,18]. The rates of DVT in bilateral AT rupture are theoretically higher than those in single rupture. Ramirez and Richardson reported a case of nearly fatal pulmonary embolism (PE) following bilateral AT ruptures in an elderly male with multiple medical comorbidities [19]. They used low molecular weight heparin (LMWH) in the immediate period, transitioning to warfarin with a goal INR of 2.0. In this case, the anticoagulation was discontinued by his primary care provider prior to the patient being able to ambulate, and he had a nearly fatal PE one week later. Chun et al. reported a fatal PE in a healthy 32-year-old male after unilateral open AT repair occurring 3 weeks following surgery [20]. Our patient received Lovenox daily until post-operative day one at which time he was discharged from the hospital with 30 days of apixaban 5mg twice daily. He began early functional rehabilitation on the left at two weeks, allowing for some lower extremity motion. This early motion may have been protective against VTE.

#### 4. Conclusions

Further studies are needed to evaluate the optimal management of bilateral AT ruptures, especially those with concomitant injuries. In our case, operative fixation followed by accelerated rehabilitation protocol resulted in a full return to active duty military service at 1 year despite the need for hardware removal at 8 months post-op. Detailed physical examination and careful attention when viewing diagnostic studies are recommended to prevent missing associated injuries, such as the medial malleolus fracture in this patient. VTE prophylaxis should not be overlooked in AT ruptures and could potentially be of greater importance in the bilaterally injured patient.

**Author Contributions:** Patient Work Up and Consent: J.L.W. and C.A.C. Patient Management: B.J.M., P.R. and K.P.K. Review of Literature: L.M., C.A.C., R.J.B. and J.L.W. Drafting: J.L.W., L.M., C.A.C. and R.J.B. All authors have read and agreed to the published version of the manuscript.

**Funding:** This research received no external funding.

**Institutional Review Board Statement:** Ethical approval was not sought for this case report because no intervention was performed which was not the standard of care.

**Informed Consent Statement:** Written informed consent has been obtained from the patient(s) to publish this paper.

**Data Availability Statement:** Not applicable.

**Conflicts of Interest:** The authors declare no conflict of interest.

## Abbreviations

AT: Achilles Tendon, APFT: Army Physical Fitness Test, DVT: Deep Vein Thrombosis, MRI: Magnetic Resonance Imaging, ORIF: Open Reduction Internal Fixation, CAM: Controlled Ankle Motion, VTE: Venous Thromboembolism, SAD: Supination Adduction, LMWH: Low Molecular Weight Heparin, PE: Pulmonary Embolism.

## References

1. Fox, G.; Gabbe, B.J.; Richardson, M.; Oppy, A.; Page, R.; Edwards, E.R.; Hau, R.; Ekegren, C.L. Twelve-month outcomes following surgical repair of the Achilles tendon. *Injury* **2016**, *47*, 2370–2374. [[CrossRef](#)] [[PubMed](#)]
2. Thomopoulos, S.; Parks, W.C.; Rifkin, D.B.; Derwin, K.A. Mechanisms of tendon injury and repair. *J. Orthop. Res.* **2015**, *33*, 832–839. [[CrossRef](#)] [[PubMed](#)]
3. Gwynne-Jones, D.; Sims, M.; Handcock, D. Epidemiology and outcomes of acute Achilles tendon rupture with operative or nonoperative treatment using an identical functional bracing protocol. *Foot Ankle Int.* **2011**, *32*, 337–343. [[CrossRef](#)] [[PubMed](#)]
4. Saltzman, C.L.; Tearse, D.S. Achilles tendon injuries. *J. Am. Acad. Orthop. Surg.* **1998**, *6*, 316–325. [[CrossRef](#)] [[PubMed](#)]
5. Arner, O.; Lindholm, A.; Orell, S.R. Histologic changes in subcutaneous rupture of the Achilles tendon; a study of 74 cases. *ActaChir Scand.* **1959**, *116*, 484–490.
6. Barfred, T. Achilles tendon rupture: Aetiology and pathogenesis of subcutaneous rupture assessed on the basis of the literature and rupture experiments on rats. *Acta Orthop. Scand. Suppl.* **1973**, *44*, 3–126. [[CrossRef](#)]
7. Rao, S.K.; Navadgi, B.C.; Vasdev, A. Bilateral spontaneous rupture of Achilles tendons: A Case Report. *J. Orthop. Surg.* **2005**, *13*, 178–180. [[CrossRef](#)] [[PubMed](#)]
8. Hayes, T.; McClelland, D.; Maffulli, N. Metasynchronous bilateral Achilles tendon rupture. *Bull Hosp. Jt. Dis.* **2003**, *61*, 140–144. [[PubMed](#)]
9. Filippucci, E.; Farina, A.; Bartolucci, F.; Spallacci, C.; Busilacchi, P.; Grassi, W. Levofloxacin-induced bilateral rupture of the Achilles tendon: Clinical and sonographic findings. *Reumatismo* **2003**, *55*, 267–269. [[PubMed](#)]
10. Garneti, N.; Holton, C.; Shenolikar, A. Bilateral Achilles tendon rupture: A case report. *Accid. Emerg. Nurs.* **2005**, *13*, 220–223. [[CrossRef](#)] [[PubMed](#)]
11. Kawtharani, F.; Masrouha, K.Z.; Afeiche, N. Bilateral Achilles Tendon Ruptures Associated With Ciprofloxacin Use in the Setting of Minimal Change Disease: Case Report and Review of the Literature. *J. Foot Ankle Surg.* **2016**, *55*, 276–278. [[CrossRef](#)] [[PubMed](#)]
12. Ando, W.; Sakai, T.; Kudawara, I.; Ieguchi, M.; Miyamoto, T.; Ohzono, K. Bilateral achilles tendon ruptures in a patient with ochronosis: A case report. *Clin. Orthop. Relat. Res.* **2004**, *424*, 180–182. [[CrossRef](#)] [[PubMed](#)]
13. De wolf, M.M.; Van der krans, A.; Frijns, C.J. Spontaneous bilateral rupture of the Achilles tendon in an elderly woman undergoing prednisone pulse therapy with a history of polymyalgia rheumatica. *Ned. Tijdschr. Geneesk.* **2006**, *150*, 2155–2158. [[PubMed](#)]
14. Kapoor, C.; Jhaveri, M.; Golwala, P.; Merh, A.; Patel, A. Acute Bilateral Traumatic Achilles Tendon Rupture—A Rare Presentation. *Cureus* **2016**, *8*, e706. [[CrossRef](#)] [[PubMed](#)]
15. Willits, K.; Amendola, A.; Bryant, D.; Mohtadi, N.G.; Giffin, J.R.; Fowler, P.; Kean, C.O.; Kirkley, K. Operative versus nonoperative treatment of acute Achilles tendon ruptures: A multicenter randomized trial using accelerated functional rehabilitation. *J. Bone Jt. Surg. Am.* **2010**, *92*, 2767–2775. [[CrossRef](#)] [[PubMed](#)]
16. Lu, J.; Maruo Holledge, M. Medial malleolus fracture of the ankle combined with rupture of the Achilles tendon. *J. Surg. Case Rep.* **2016**, *2016*, rjw062. [[CrossRef](#)] [[PubMed](#)]
17. Makhdom, A.M.; Cota, A.; Saran, N.; Chaytor, R. Incidence of symptomatic deep venous thrombosis after Achilles tendon rupture. *J. Foot Ankle Surg.* **2013**, *52*, 584–587. [[CrossRef](#)] [[PubMed](#)]
18. Nilsson-Helander, K.; Thurin, A.; Karlsson, J.; Eriksson, B.I. High incidence for deep venous thrombosis after Achilles tendon rupture: A prospective study. *Knee Surg. Sports Traumatol. Arthrosc.* **2009**, *17*, 1234–1238. [[CrossRef](#)]
19. Ramirez, M.A.; Richardson, L.C. Pulmonary Embolism associated with spontaneous bilateral Achilles tendon rupture. *J. Foot Ankle Surg.* **2007**, *46*, 283–287. [[CrossRef](#)] [[PubMed](#)]
20. Chun, D.I.; Lee, S.; Won, S.H.; Cho, J. Fatal pulmonary thromboembolism after Achilles tendon open repair: A rare case report. *Medicine* **2017**, *96*, e8887. [[CrossRef](#)] [[PubMed](#)]