

Case Report

Prolonged Disease-Free Survival in a Relapsed Adult Granulosa Cell Tumor of the Ovary Treated by Combined Leuprolide and Letrozole: Case Report

Giancarlo Garuti ^{1,*}, Paola Francesca Sagrada ², Susanna Delfrati ¹, Lorenzo Sogaro ¹ and Marco Soligo ¹¹ Obstetrics and Gynecology Department, Hospital of Lodi, via Largo Donatori del Sangue, 26900 Lodi, Italy² Medical Oncology Department, Hospital of Lodi, via Largo Donatori del Sangue, 26900 Lodi, Italy

* Correspondence: giancarlo.garuti@tiscali.it; Tel.: +39-33-8270-2675

Abstract: Relapsing ovarian granulosa-cell tumor (GCT) is a challenge for physicians due to the lack of effective therapy. Current strategies did not improve the 80% death rate of recurrent disease. GCTs synthesize estrogens and express follicle-stimulating hormone, gonadotropin-releasing hormone, and estrogen and progesterone receptors. The FOXL2-C134W mutation is shared in all GCTs, and its downregulation of hormone-related apoptosis appears causal in induction of tumor phenotype. On these assumptions, hormone anti-estrogenic therapies have been proposed for recurrent GCTs. A 32-year-old woman suffering from GCT was first treated by surgery in 2004 and staged as IA disease. Two subsequent pelvic relapses were diagnosed in 2006 and 2007, and the patient underwent surgery and chemotherapy to treat both recurrences. Overall, she underwent five subsequent surgical interventions and two chemotherapy instances. A third single pelvic relapse above the vaginal cuff was diagnosed in 2013. Based on the patient's refusal to undergo further surgery we proposed an anti-estrogen therapy consisting of combined GnRH analogue leuprolide and the aromatase inhibitor letrozole. Complete remission was obtained after 3 months from the start of therapy. Subsequently, we found that disease-free survival was maintained over 9 years of treatment. Although recent reports indicate poor effectiveness of hormone therapy to treat recurrent GCTs, the success of this case indicates that a subset of patients with recurrent GCT maintain a tumor phenotype highly responsive to anti-estrogen drugs.

Keywords: granulosa-cell tumor; ovary; ovarian cancer; GnRH agonists; aromatase inhibitors; FOXL-2



Citation: Garuti, G.; Sagrada, P.F.; Delfrati, S.; Sogaro, L.; Soligo, M. Prolonged Disease-Free Survival in a Relapsed Adult Granulosa Cell Tumor of the Ovary Treated by Combined Leuprolide and Letrozole: Case Report. *Reprod. Med.* **2022**, *3*, 297–302. <https://doi.org/10.3390/reprodmed3040023>

Academic Editor: Udo Jeschke

Received: 26 September 2022

Accepted: 31 October 2022

Published: 1 November 2022

Publisher's Note: MDPI stays neutral with regard to jurisdictional claims in published maps and institutional affiliations.



Copyright: © 2022 by the authors. Licensee MDPI, Basel, Switzerland. This article is an open access article distributed under the terms and conditions of the Creative Commons Attribution (CC BY) license (<https://creativecommons.org/licenses/by/4.0/>).

1. Introduction

The adult-type granulosa-cell tumor (GCT) is a stromal neoplasm accounting for 2–5% of all ovarian cancers, with a median presentation age of 52 years. It arises from the granulosa cells and a point mutation of the FOXL2 gene, encoding a transcription factor driving cell function, and differentiation is found in almost all GCTs [1,2]. GCTs secrete estrogens, leading to abnormal uterine bleeding as a common symptom, and exposure to estrogens can promote synchronous endometrial hyperplasia or carcinoma. Pelvic pain due to bulking growth, torsion, or rupture of the tumor and ascites are other reported symptoms. More than 95% of GCTs are unilateral, and about 85% of cases are diagnosed in the first stage, according to FIGO classification. GCTs show indolent behavior and a favorable prognosis. Nevertheless, in about 25% of cases early and mostly late relapses follow the initial treatment, indicating the need of long-term surveillance and effective therapy for recurrent disease [1]. Staging is the main prognostic factor, displaying survival rates ranging from 95% to 45% for patients diagnosed at stages I and IV, respectively. Surgery is the mainstay treatment to establish a diagnosis and to stage the disease. Hysterectomy and bilateral adnexectomy are recommended, such as cytoreduction of extragenital disease when possible. In young patients showing first-stage disease conservative management is warranted. The routine accomplishment of lymphadenectomy is debatable due to

the low rate of nodal spread [3]. There is a role for platinum-based chemotherapy in patients affected by persistent or relapsing disease, with response rate varying from 37% to 90% [4]. Radiotherapy and monoclonal immunotherapy by blocking vascular endothelial growth factor or tyrosine kinase receptors have been described to treat recurrent disease but there are no sufficient data to establish their therapeutic role. Hormone therapy has been proposed for progressive disease based on tumor expression of both estrogen (ER) and progesterone receptors (PGR). Treatment regimens included gonadotropin-releasing hormone (GnRH) agonists, progestogens, tamoxifen, and aromatase inhibitors (AIs). A review from 2014 reported a 100% response in patients treated with AIs, whereas a recent prospective trial showed a response rate to AIs of only 2.6% [5,6]. Granulosa cells and GCTs secrete inhibins, heterodimeric proteins downregulating pituitary follicle-stimulating hormone (FSH) production. Inhibin-B is considered the most useful marker in surveillance of GCTs and to monitor the treatment response [7]. We present a patient in which a combined therapy with a GnRH agonist and an AI to treat recurrent GCT allowed complete and sustained remission of disease.

2. Case Report

In September 2003 a 32-year-old woman underwent gynecological examination due to a one-year-long amenorrhea. Initial investigations included physical examination and transvaginal ultrasonography (TVUS) demonstrating a 18×16 mm complex left ovarian cyst, believed to be endometriotic in nature, as the sole abnormal finding. Tumor markers including CA125, CA15.3, CEA, and AFP were normal and a treatment with oral contraceptives was undertaken. After a six-month reassessment, the patient underwent laparoscopic cyst enucleation in July 2004 due to the increasing size of the ovarian cyst (20×22 mm). Histology diagnosed adult GCT showing 10 mitoses/HPF, whereas immunochemistry revealed positivity to vimentin, chromogranin, CD-99, and inhibin. A few days later, a laparoscopic left adnexectomy was performed, revealing no persistent disease. Upon these findings, the disease was stratified as FIGO stage IA and clinical follow-up was indicated. In August 2006, TVUS found a sub-serous hypoechoic nodule of the posterior uterine wall measuring 12×11 mm. The patient underwent laparoscopic excision of the uterine focality, giving a pathologic diagnosis of recurrent GCT, leading to a further exploratory laparoscopy in October 2006. It revealed a multiple nodular relapsing disease on the vesico-uterine peritoneal fold. Peritoneal excision and left pelvic lymphadenectomy were carried out. Histopathology confirmed a relapsing GCT without lymph-node spread. The patient postoperatively underwent chemotherapy with six cycles of carboplatin (AUC 6)/taxol (175 mg/sm), concluded in May 2007. In August 2007, TVUS found a right ovarian cyst measuring 20×11 mm suspected for a further recurrence and surgical radicalization was proposed. The patient underwent laparotomy with hysterectomy, right adnexectomy, omentectomy, right iliac lymphadenectomy, and intraoperative chemo-hyperthermia with cisplatin (150 mg/sm)/gemcitabine (1000 mg). No residual disease was recorded, whereas pathologic findings confirmed a relapsed GCT in the right ovary. The patient was advised to follow up and remained free from disease throughout a 60-month period. An increase in inhibin-B was found from June 2013 and in December 2013, with inhibin-B values of 141 pg/mL. The patient came to our charge. Physical examination discovered a 2 cm solid movable mass above the vaginal cuff. Computed tomography, magnetic resonance (Figure 1), and positron emission tomography (Figure 2) were performed to stage the recurrent disease. The imaging showed a solid, metabolically active pelvic nodule measuring 18 mm in the largest diameter as a unique site of relapsing GCT.

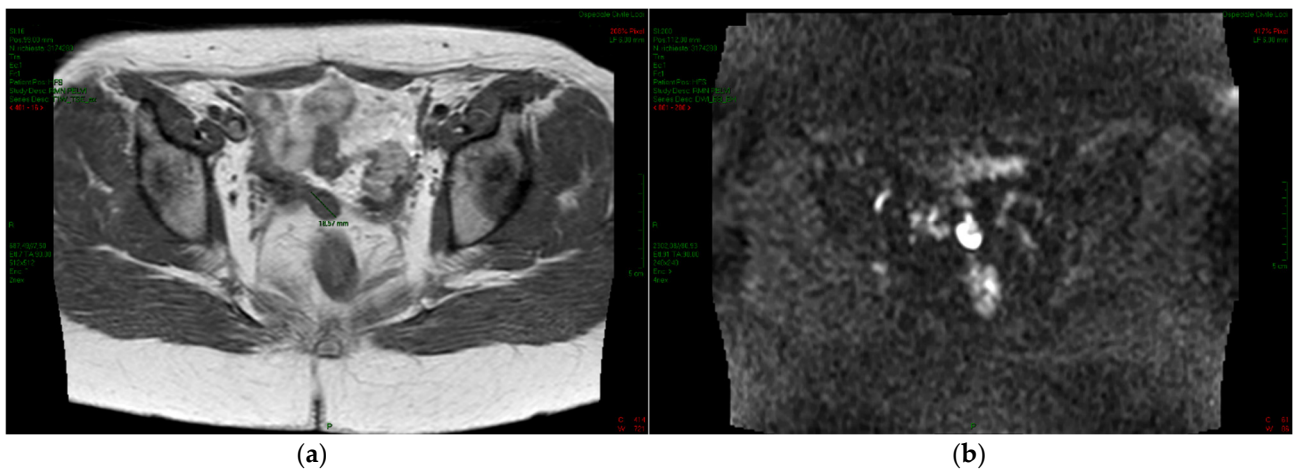


Figure 1. Magnetic resonance. A solid mass is identified as an 18 mm nodule located above the vaginal cuff with intermediate signal intensity on T1 TSE-weighted axial imaging (a) and with high signal intensity on diffusion-weighted MRI (b), suggesting the presence of a highly cellular lesion.

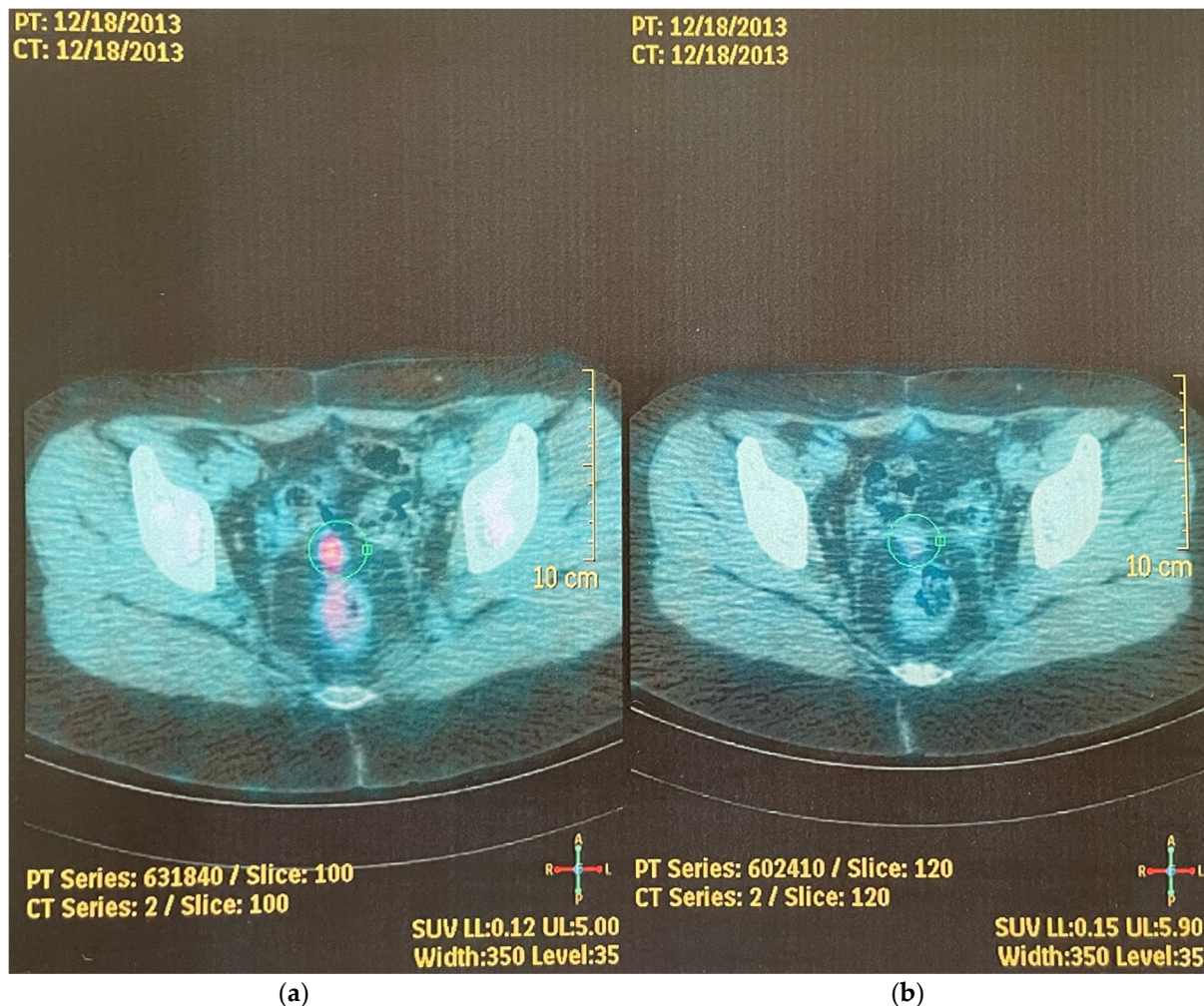


Figure 2. Positron emission tomography. The nodule shown in Figure 1 is further characterized through an FDG PET/TC scan. The middle density nodule found on the axial CT scan (b) is shown to be metabolically active (standardized uptake value of 3.7) on an FDG PET (a), suggesting the diagnosis of recurrence.

TVUS showed a non-homogeneous, well-circumscribed nodule above the vaginal vault measuring 14×18 mm, displaying high vascular flow with low impedance upon

eco-color-Doppler assessment. We believed that the comprehensive data were sufficient to give a diagnosis of recurrent GCT. Our first therapeutic indication was surgical. Because of the patient's reluctance to undergo further surgery and based on the promising results arising at that time from hormone therapy, we proposed a medical therapy combining the GnRH analogue leuprolide acetate (11.25 mg, intramuscular administration every 3 months) and AI letrozole (2 mg/day) [5,8]. Ethical-board approval was obtained, although a two-day hospital admission was recommended to begin off-label drug administration (Ref. doc 2014803187). After the patient's agreement via a signed informed consent and a tailored informative note, she started the treatment in April 2014. A monitoring of response was planned by monthly physical examination, TVUS assessment, and inhibin-B determination. After observing a progressive decrease in both nodule size and inhibin-B level, from July 2014 physical examination and TVUS demonstrated the disappearance of the nodule and inhibin-B dropped below the physiological cut-off of 7 pg/mL. From the achievement of complete response, we advised the patient to follow up every six months based on physical examination and inhibin-B determination, with a planned yearly computed tomography. Based on the experience of breast cancer adjuvant hormone therapy [9], an arbitrary cease in leuprolide administration was suggested after 60 months of treatment, and from July 2019 the patient continued her therapy with only letrozole. After 9 years from the start of therapy, the patient is alive and free from disease. With the exception of a slight non-progressive reduction in bone density detected 3 years after the beginning of therapy, the treatment was well tolerated without any recorded significant complaint.

3. Discussion

The 5-year survival rate of patients suffering from GCT was found to be approximately 95%, but it is estimated that 25% of GCT patients ultimately relapse over a longer period and that 80% of patients with recurrent GCT die from the disease [3]. Surgery and chemotherapy based on bleomycin–etoposide–cisplatin or carboplatin–taxanes are the cornerstone therapies of recurrent disease [4,8]. GCT is a unique stromal neoplasm exhibiting morphological and biochemical features similar to proliferating granulosa cells of the pre-ovulatory follicle, including estrogens and inhibin synthesis, FSH receptor, ER and PGR expression, and aromatase activity [2,10]. As displayed in normal granulosa cells, GCT-derived cell lines also express the GnRH receptor that, when activated, triggers apoptotic pathways [11]. The finding that virtually all adult-type GCTs share a single missense mutation in the FOXL2 gene (402C > G, C134W) that encodes the fork-head transcription factor 2 is of pivotal interest. Wild FOXL2 plays a role in the maintenance of granulosa-cell biology by driving differentiation, promoting estrogen synthesis by aromatase regulation, and modulating cell apoptosis. FOXL2-C134W mutation appears unable to elicit many apoptotic signaling responses and upregulates aromatase function, indicating a role of this somatic mutation in the pathogenesis of GCT [2,11,12]. Based on these findings, but with the arbitrary assumption that endocrine and/or autocrine estradiol exposure of GCT can promote its growth, clinicians investigated the effectiveness of anti-estrogenic drugs to treat relapsing diseases [13]. GnRH analogues downregulate pituitary FSH secretion, allowing the estrogen synthesis promoted by activation of the FSH receptor to be broken. Moreover, the binding to the GnRH receptor displayed in GCT cells may contribute to driving tumor-cell apoptosis [11]. We retrieved 16 patients from current literature undergoing GnRH analogues for recurrent GCT, showing an objective response in six cases (37.5%) [5,14]. The enzyme aromatase is a member of the cytochrome P-450 family converting androgens to estrogens and it is expressed in GCTs, a cell function possibly upregulated by C134W-FOXL2 mutation [11,13]. To maximize the deprivation of estrogens, the inhibition of aromatase inside and outside the tumor appears to be a rational approach. In January 2014, Van Meurs updated the effectiveness of AIs treatment in GCTs, reporting a 100% response in nine patients previously described as case reports or small series [5]. Nevertheless, in a Dutch survey published in 2015, the same author found neither complete nor partial responses in 10 patients treated by AIs. Stabilization of

disease was obtained in 70% of the cases and mean progression-free survival (PSF) was 13 months [15]. Recently, a prospective trial analyzing the effectiveness of anastrozole on 38 patients with relapsing GCT showed partial response and stable disease in 2.6% and 76% of patients, respectively. The clinical benefit at 12 months and median PFS were 79% and 8.6 months, respectively [6]. In 16 women treated with AIs included in the review by Brink et al. published in 2022, complete response, partial response, and stable disease were achieved in 6%, 31%, and 44% of patients, respectively [13]. Despite these discouraging findings, a combined anti-estrogenic therapy led to a sustained complete remission in our patient, persisting throughout 9 years of treatment until now. With the assumption that blocking estrogen synthesis inside and outside the tumor can be effective at controlling its growth, both the decrease in the signaling promoted by the high levels of FSH in a menopausal patient by a GnRH analogue and the direct inhibition of the key enzyme responsible for estrogen synthesis by an AI appear warranted to optimize hypo-estrogenic biochemical milieu. Based on this rationale, we proposed a combined hormone treatment by a GnRH analogue and an AI to the patient, a therapy safely experienced in an adjuvant setting of premenopausal ER-positive breast-cancer patients [9]. To our knowledge this is the first patient to be described in the literature with relapsing GCT treated with a combination treatment as such. The achievement of complete response by hormone therapy in relapsing GCTs is rare, although the high rate of stabilized disease is clinically significant and indicates that estrogens may play some role in promoting tumor growth [5,13]. In our patient, all recurrences were limited to the pelvic peritoneum without evidence of distant spread. Even the last recurrence was confined to the pelvis, and we can hypothesize that such “favorable” behavior of regional relapsing disease could be the result of inadvertent tumoral-cell peritoneal seeding caused by previous surgeries. The maintenance of a differentiated monoclonal cancer-cell biology displaying an exquisite responsiveness to estrogen deprivation but still not affected by other carcinogenetic impaired signaling pathways [2] may account for the significant clinical result achieved in this patient. It is probable that a small cohort of relapsing GCTs present similar characteristics, and it is advisable that more reliable molecular markers of hormone responsiveness, besides the improvement of knowledge on the aberrations caused by FOXL2-C134W mutation, will permit the tailoring of more rational interventional strategies in the years to come.

4. Conclusions

We present a patient with relapsing GCT responsive to concurrent leuprolide and letrozole administration. Complete tumor shrinkage and lasting remission persisting after 9 years of therapy were obtained. This finding suggests that a subset of patients with relapsing GCTs can benefit from anti-estrogen drugs.

Author Contributions: G.G.: conceptualization, writing—original draft preparation, writing—review and editing; P.F.S.: conceptualization, formal analysis; S.D.: data curation, formal analysis, visualization; L.S.: data curation, formal analysis, editing; M.S.: supervision, validation. All authors have read and agreed to the published version of the manuscript.

Funding: This research received no external funding.

Institutional Review Board Statement: Institutional Board approval was obtained, although a two-day hospital admission was recommended to begin off-label drug administration. The study was conducted according to the guidelines of the Declaration of Helsinki and approved by the Institutional Review Board of Lodi Hospital (Ref. doc 2014803187, 2 April 2014).

Informed Consent Statement: An informed consent and tailored informative note were obtained from the subject patient of the study before the start of therapy. An informed consent was obtained from the patient to publish this manuscript including images.

Acknowledgments: We thank M.S., the subject patient of the present report, for authorizing the publication of clinical data. We thank Caroline Calnan Sagrada, a native English speaker experienced in medical literature, who supervised the English grammar and style of the manuscript.

Conflicts of Interest: All authors declare no existing conflict of interest.

References

1. Shumer, S.T.; Cannistra, S.A. Granulosa cell tumor of the ovary. *J. Clin. Oncol.* **2003**, *21*, 1180–1189. [[CrossRef](#)] [[PubMed](#)]
2. Jamieson, S.; Fuller, P.J. Molecular pathogenesis of granulosa cell tumors of the ovary. *Endocr. Rev.* **2012**, *33*, 109–144. [[CrossRef](#)] [[PubMed](#)]
3. Colombo, N.; Parma, G.; Zanagnolo, V.; Insinga, A. Management of stromal cell tumors. *J. Clin. Oncol.* **2007**, *25*, 2944–2951. [[CrossRef](#)] [[PubMed](#)]
4. Nakai, H.; Koike, E.; Murakami, K.; Takaya, H.; Kotani, Y.; Nakai, R.; Suzuki, A.; Aoki, M.; Matsumura, N.; Mandai, M. Clinical determinants affecting indications for surgery and chemotherapy in recurrent ovarian granulosa cell tumor. *Healthcare* **2019**, *7*, 145. [[CrossRef](#)] [[PubMed](#)]
5. Van Meurs, H.S.; Van Lonkhuijzen, R.C.W.; Limpes, J.; Van der Valk, J.; Buist, M.R. Hormone therapy in ovarian granulosa cell tumors: A systematic review. *Gynecol. Oncol.* **2014**, *134*, 196–205. [[CrossRef](#)] [[PubMed](#)]
6. Benerjee, S.N.; Tang, M.; O’Connell, R.L.; Sjoquist, K.; Clamp, A.R.; Millan, D.; Nottley, S.; Lord, R. A phase 2 study of Anastrozole in patients with estrogen receptor and progesterone receptor positive recurrent/metastatic granulosa cell tumors/sex cord stromal tumors of the ovary: The PARAGON/ANZ GOG 0903 trial. *Gynecol. Oncol.* **2021**, *163*, 72–78. [[CrossRef](#)] [[PubMed](#)]
7. Portuesi, R.; Loppini, A.; Mancari, R.; Filippi, S.; Colombo, N. Role of inhibin B in detecting recurrence of granulosa cell tumors of the ovary in postmenopausal patients. *Int. J. Gynecol. Cancer* **2021**, *31*, 893–898. [[CrossRef](#)] [[PubMed](#)]
8. Zhuang, Y.; Zhang, S.; Liu, Y.; Yang, H. GnRH as a treatment for letrozole-resistant recurrent adult granulosa cell tumors: A case report. *Medicine* **2021**, *100*, e28343. [[CrossRef](#)] [[PubMed](#)]
9. Bui, K.T.; Willson, M.L.; Goel, S.; Beith, J.; Goodwin, A. Ovarian suppression for adjuvant treatment of hormone receptor-positive early breast cancer. *Cochrane Database Syst. Rev.* **2020**, *3*, CDO013538. [[CrossRef](#)] [[PubMed](#)]
10. Haltia, U.M.; Pihlajoki, M.; Andersson, N.; Makinen, L.; Tapper, J.; Cervera, A.; Horlings, H.M.; Turpeinen, V.; Anttonen, M.; Unkila-Kallio, L.; et al. Functional profiling of FSH and estradiol in ovarian granulosa cell tumors. *J. Endocr.* **2020**, *41*, bvaa034. [[CrossRef](#)] [[PubMed](#)]
11. Cheng, J.C.; Klausen, C.; Leung, P.L.K. Overexpression of wild-type but not C134W mutant FOXL2 enhances GnRH induced cell apoptosis by increasing GnRH receptor expression in human granulosa cell tumors. *PLoS ONE* **2013**, *8*, e55099. [[CrossRef](#)] [[PubMed](#)]
12. Fleming, N.I.; Knowler, K.C.; Lazarus, K.A.; Fuller, P.J.; Simpson, E.R.; Clyne, C.D. Aromatase is a direct target of FOXL2: C134W in granulosa cell tumors via a single highly conserved binding site in the ovarian specific promoter. *PLoS ONE* **2010**, *5*, e14389. [[CrossRef](#)] [[PubMed](#)]
13. Brink, G.J.; Groeneweg, J.W.; Hooft, L.; Zweemer, R.P.; Witteveen, P.O. Response to systematic therapies in ovarian adult granulosa cell tumors: A literature review. *Cancers* **2022**, *14*, 2998. [[CrossRef](#)] [[PubMed](#)]
14. Zhuang, Y.; Zhang, S.; Liu, Y.; Yang, H. Can adjuvant chemotherapy improve the prognosis of adult ovarian granulosa cell tumors? A narrative review. *Medicine* **2022**, *101*, e29062. [[CrossRef](#)]
15. Van Meurs, H.S.; Van Der Velden, J.; Buist, M.R.; Van Driel, W.J.; Kenter, G.G.; Van Lonkhuijzen, L. Evaluation of response to hormone therapy in patients with measurable adult granulosa cell tumors of the ovary. *Acta Obstet. Gynecol. Scand.* **2015**, *94*, 1269–1275. [[CrossRef](#)]