hearts

MDPI

Case Report

Hidden under the Surface: A Rare Cause of Repeated Syncope in a Patient with Recent Pacemaker Implantation

Leticia Barrios [1], Dagmara Dilling-Boer [1], Axel Jacobs [2], Olivier Ghekiere [3] and Philippe Timmermans, Jr. [1,*]

[1] Department of Cardiology, Hartcentrum, Jessa Hospital, 3500 Hasselt, Belgium; leticia.barrios@jessazh.be (L.B.); dagmara.dilling.boer@jessazh.be (D.D.-B.)
[2] Department of Nuclear Medicine, Jessa Hospital, 3500 Hasselt, Belgium; axel.jacobs@jessazh.be
[3] Department of Radiology, Jessa Hospital, 3500 Hasselt, Belgium; Olivier.ghekiere@jessazh.be
* Correspondence: philippe.jr.timmermans@jessazh.be

Abstract: A 66-year-old woman received a pacemaker implantation because of syncope with documented sinus arrest and junctional bradycardia. Three weeks later the pacemaker analysis revealed episodes of nonsustained ventricular tachycardia. Coronary angiography and invasive coronary assessment showed diffuse moderate stenosis but no significant ischemia. Three months later she experienced a new syncope and the pacemaker analysis showed runs of nonsustained ventricular tachycardia at the time of syncope. The combination of brady- and tachyarrhythmias raised concern for cardiac sarcoidosis. ^{18}F-fluorodeoxyglucose positron emission tomography (PET) scan showed increased FDG uptake in the basal segments compatible with inflammatory disease. Cardiac magnetic resonance imaging showed late gadolinium enhancement in the same region of the PET-avid lesions. Diagnostic electrophysiologic study could induce VT. The diagnosis of cardiac sarcoidosis was made, for which high dose corticosteroids were prescribed and an upgrade to a dual chamber implantable cardioverter defibrillator was performed. Because of the localization of the lesions, an endomyocardial biopsy was not performed. All the lesions regressed completely on PET-scan after treatment with high dose corticosteroids.

Keywords: sarcoidosis; cardiac magnetic resonance; cardiomyopathy

Citation: Barrios, L.; Dilling-Boer, D.; Jacobs, A.; Ghekiere, O.; Timmermans, P., Jr. Hidden under the Surface: A Rare Cause of Repeated Syncope in a Patient with Recent Pacemaker Implantation. *Hearts* **2021**, *2*, 288–293. https://doi.org/10.3390/hearts2020023

Academic Editor: Matthias Thielmann

Received: 11 May 2021
Accepted: 10 June 2021
Published: 16 June 2021

1. Introduction

Here we report the case of a middle aged woman presenting with repeated syncopes, even after pacemaker implantation. Following several diagnostic investigations an unexpected diagnosis was made.

2. Case Presentation

A 66-year-old woman presented with complaints of lightheadedness and palpitations followed by abrupt loss of consciousness while sitting. There were no bladder or bowel incontinence or seizure-like movements. She had no chest pain or dyspnea. She experienced repeated syncopes in the two days prior to admission. Her past medical history was significant for a syncope nine years ago and a hysterectomy. There was no family history of sudden cardiac death nor medication use. On examination she had blood pressure of 140/60 mmHg, a regular heart rhythm of 73/min, no fever, 97% oxygen saturation; with normal heart and lung sounds on auscultation. There were no neurological abnormalities. The electrocardiogram at the emergency department revealed a sinus rhythm, 77/min, with a left axis and left anterior hemiblock. She was admitted at our department and during her hospital stay symptomatic sinus arrest and junctional bradycardia were documented on telemetry. We therefore decided to implant a pacemaker. She was discharged from the hospital after uneventful observation post-device implantation.

One month later the pacemaker analysis revealed three episodes of asymptomatic nonsustained ventricular tachycardia. Coronary angiography was performed to exclude

myocardial ischemia and showed diffuse moderate coronary stenosis without significant ischemia on invasive physiological coronary assessment.

Transthoracic echocardiography showed normal heart structure and function. Three months after the pacemaker implantation she experienced a syncope. The pacemaker analysis at this time again showed runs of nonsustained ventricular tachycardia with a ventricular rate up to 300 bpm (Figure 1).

The combination of brady- and tachyarrhythmias raised the concern for cardiac sarcoidosis (CS), for which a ^{18}F-fluorodeoxyglucose (FDG)-positron emission tomography (PET) scan was scheduled.

The measured standardized uptake value (SUV) max was 4.33 g/mL and the left ventricular blood pool threshold 2.11 g/mL (cardiac SUV max greater than a 1.5-times left ventricular blood pool threshold are considered quantitatively positive) [1].

The images showed FDG uptake in the basal segments of the anterolateral, inferolateral and inferior wall and in the basal segment of the anteroseptal wall, compatible with an inflammatory myocardial disease. There was no tracer uptake in other organs or mediastinal structures (Figure 2).

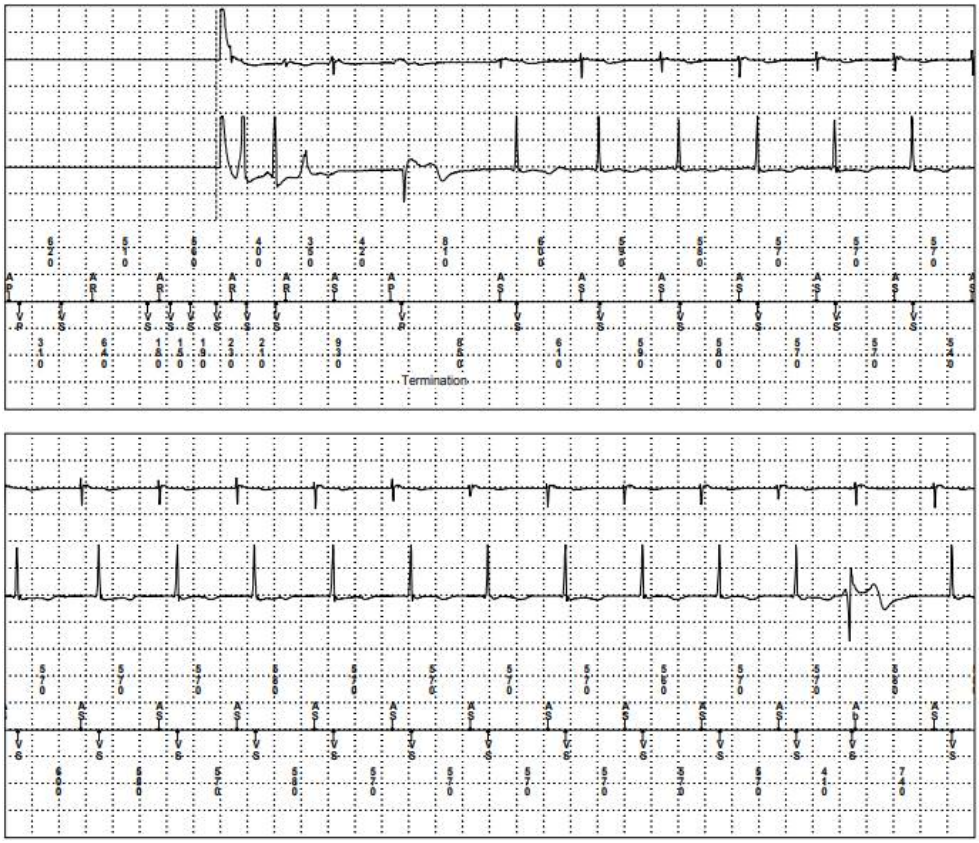

Figure 1. Ventricular tachycardia recorded on pacemaker up to 300 bpm.

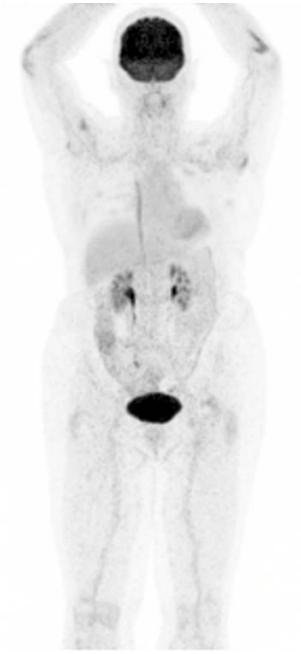

(**a**)

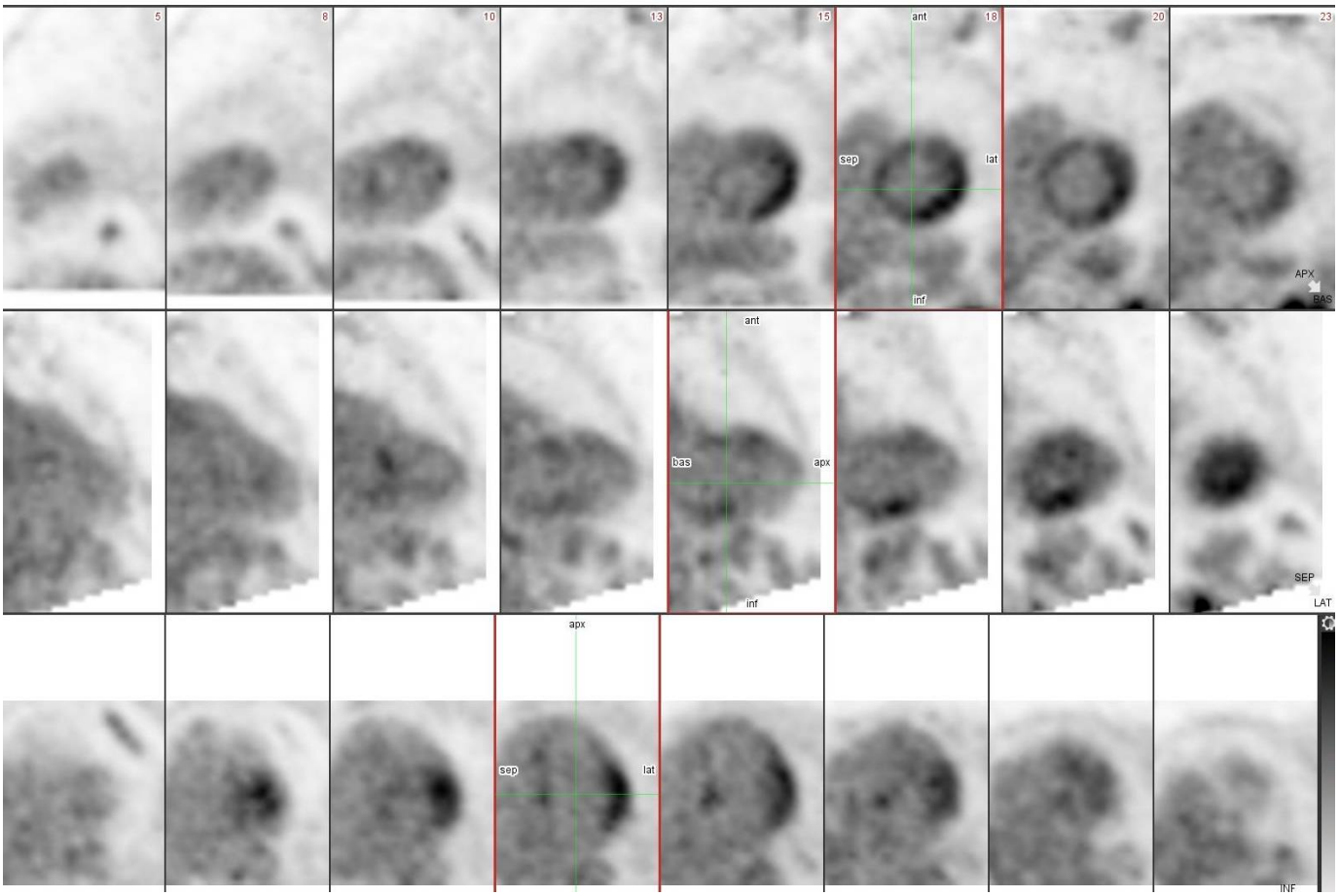

(**b**)

Figure 2. FDG PET scan. (**a**) Whole body MIP image. (**b**) The short, vertical and horizontal long axis images show ^{18}F-FDG uptake in the basal segments of the anterolateral, inferolateral and inferior wall and in the basal segment of the anteroseptal wall. Slice 10 mm, zoom × 1.

The diagnosis of CS was suspected, based on the recent history of ventricular arrhythmia and sinus arrest in the absence of echocardiographic structural heart disease and hemodynamically significant myocardial ischemia. Laboratory results showed normal inflammatory parameters and normal troponin levels. The patient was admitted for device explantation, performance of cardiac magnetic resonance (CMR), diagnostic invasive electrophysiologic study and upgrade to a dual chamber implantable cardioverter defibrillator. During electrophysiologic study, sustained ventricular tachycardia could be induced. CMR showed prolonged myocardial relaxation up to 62–64 msec on T2 mapping in the inferolateral basal segment of the left ventricle, suggesting acute myocardial inflammation In addition, midmyocardial and subepicardial late gadolinium enhancement (LGE) was demonstrated in the same inferolateral basal segment of the left ventricle (Figures 3 and 4).

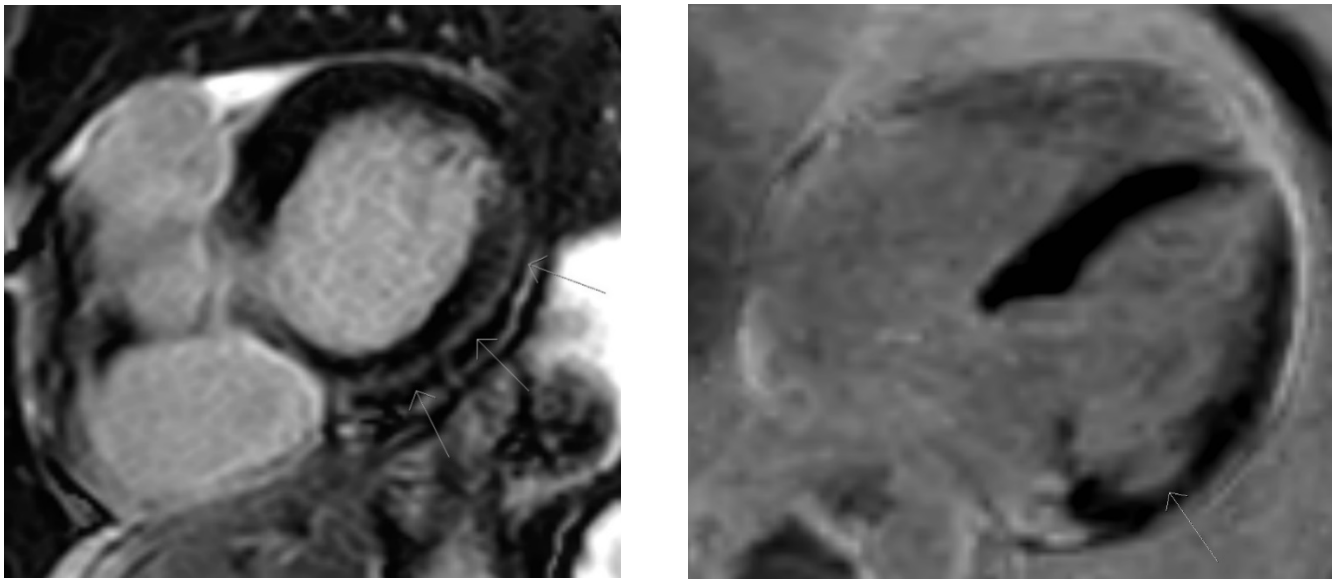

(**a**) (**b**)

Figure 3. Cardiac magnetic resonance. (**a**,**b**) Late gadolinium enhancement (LGE) inferolateral basal midmyocardial and subepicardial (arrows) in two chamber and four chamber views.



Figure 4. T2 mapping: prolonged myocardial relaxation inferolateral basal segment of the left ventricle up to 62–64 msec.

Taken together these findings were strongly suggestive for myocardial inflammation/necrosis compatible with CS. Because of the localization of the lesions, an endomyocardial biopsy was not performed. A dual chamber implantable cardioverter defibrillator was implanted and corticosteroids were initiated, with a gradual tapering over 12 weeks. She did not experience syncope again, nor did she have any other symptoms suggestive of heart arrhythmias. A PET-scan three months after the cessation of corticosteroids showed the regression of all lesions (Figure 5).

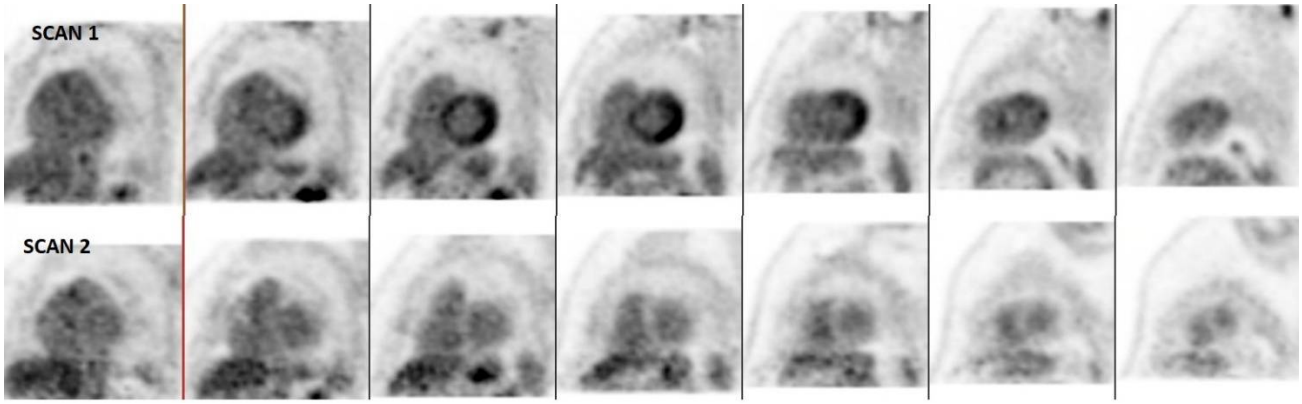

Figure 5. FDG PET-CT images at the time of diagnosis (**SCAN 1**) and 3 months after cessation of corticosteroids (**SCAN 2**). Slice 12 mm. Zoom × 3.

3. Discussion

Here we report a case of an isolated CS. Sarcoidosis is a multisystem inflammatory granulomatous disease of unknown origin. Up to 5% of patients with sarcoidosis present with clinical symptoms of cardiac involvement: ventricular arrythmias, conduction abnormalities and heart failure. About 20–25% of patients have clinical silent cardiac involvement [2,3]. The true prevalence of isolated CS is not known, as illustrated by a huge variability (27–45%) in the reporting of all cases with cardiac sarcoidosis [4].

Diagnosis of CS is challenging. An endomyocardial biopsy provides a high specificity for diagnosis but this invasive test has documented limited sensitivity, due to the patchy nature of the disease. Advanced cardiac imaging with CMR and/or FDG-PET are therefore valuable tools for the detection of CS. The use of CMR clearly has increased the diagnostic yield in recent years [3,5]. In particular, the combination of detecting myocardial scarring/fibrosis by LGE and quantitative tissue characterization detecting myocardial inflammation by T2 mapping has shown added value in the diagnosis of CS [6].

Although current recommendations require histological confirmation for diagnosis of sarcoidosis, either (A) histological diagnosis from myocardial tissue or (B) histological diagnosis from extra cardiac sarcoidosis in combination with other criteria with noninvasive studies [2], we did not take a biopsy because of the difficult-to-reach cardiac localization of the lesions and the lack of extracardiac involvement.

Despite the fact that an atrioventricular block is considered typical for CS, the presence of ventricular tachycardia and sinus node dysfunction—after excluding other causes, such as ischemia and structural heart disease—in combination with late gadolinium enhancement (LGE) on CMR and uptake on cardiac FDG-PET led to the diagnosis of CS.

The combination of FDG-PET and CMR has contributed to diagnostic and therapeutic progress in CS. This is mainly due to the complementary information of both imaging modalities, with CMR demonstrating myocardial fibrosis and FDG-PET showing active inflammation [7]. This distinction between active and nonactive lesions impacts therapeutic decision making, both with regard to systemic immunosuppressive therapy and cardiac specific therapy (implantable cardioverter defibrillator).

Management of CS is based on (A) immunosuppressive therapy for the treatment of active sarcoidosis and (B) cardiac-specific therapies including medication to treat ventricu-

lar dysfunction and device therapy (pacemaker/ICD) for heart blocks and heart rhythm disturbances [2,8].

4. Conclusions

Isolated cardiac sarcoidosis is a rare and underdiagnosed disease. Clinical presentation may include AV block, sinus node dysfunction, tachyarrythmias and heart failure. Multimodality imaging with CMR and PET-CT is very important for diagnosis and therapeutic decision making.

Author Contributions: L.B. wrote the manuscript. P.T.J. revised the manuscript. D.D.-B. revised the manuscript. O.G. and A.J. provided the images. All authors have read and agreed to the published version of the manuscript.

Funding: This research received no external funding.

Institutional Review Board Statement: Not applicable.

Informed Consent Statement: Informed consent was obtained from all subjects involved in the study.

Data Availability Statement: No new data were created or analyzed in this study. Data sharing is not applicable to this article.

Conflicts of Interest: The authors declare no conflict of interest.

References

1. Varghese, M.; Smiley, D.; Bellumkonda, L.; Rosenfeld, L.E.; Zaret, B.; Miller, E.J. Quantitative interpretation of FDG PET for cardiac sarcoidosis reclassifies visually interpreted exams and potentially impacts downstream interventions. *Sarcoidosis Vasc. Diffus. Lung Dis.* **2018**, *35*, 342–353.
2. Birnie, D.H.; Sauer, W.H.; Bogun, F.; Cooper, J.M.; Culver, D.A.; Duvernoy, C.S.; Judson, M.A.; Kron, J.; Mehta, D.; Nielsen, J.C.; et al. HRS Expert Consensus Statement on the Diagnosis and Management of Arrhythmias Associated With Cardiac Sarcoidosis. *Heart Rhythm.* **2014**, *11*, 1305–1323. [CrossRef] [PubMed]
3. Kandolin, R.; Lehtonen, J.; Airaksinen, J.; Vihinen, T.; Miettinen, H.; Ylitalo, K.; Kaikkonen, K.; Tuohinen, S.; Haataja, P.; Kerola, T.; et al. Cardiac sarcoidosis: Epidemiology, characteristics, and outcome over 25 years in a nationwide study. *Circulation* **2015**, *131*, 624–632. [CrossRef] [PubMed]
4. Okada, D.R.; Bravo, P.E.; Vita, T.; Agarwal, V.; Osborne, M.T.; Taqueti, V.R.; Skali, H.; Chareonthaitawee, P.; Dorbala, S.; Stewart, G.; et al. Isolated cardiac sarcoidosis: A focused review of an under-recognized entity. *J. Nucl. Cardiol.* **2018**, *25*, 1136–1146. [CrossRef] [PubMed]
5. Slart, R.H.J.A.; Glaudemans, A.W.J.M.; Lancellotti, P.; Hyafil, F.; Blankstein, R.; Schwartz, R.G.; Schwartz, R.G.; Russell, R.; Gimelli, A.; Rouzet, F.; et al. A joint procedural position statement on imaging in cardiac sarcoidosis: From the Cardiovascular and Inflammation & Infection Committees of the European Association of Nuclear Medicine, the European Association of Cardiovascular Imaging, and the American Society of Nuclear Cardiology. *J. Nucl. Cardiol.* **2018**, *25*, 298–319. [PubMed]
6. Puntmann, V.O.; Isted, A.; Hinojar, R.; Foote, L.; Carr-White, G.; Nagel, E. T1 and T2 mapping in recognition of early cardiac involvement in systemic sarcoidosis. *Radiology* **2017**, *285*, 63–72. [CrossRef] [PubMed]
7. Vita, T.; Okada, D.R.; Veillet-Chowdhury, M.; Bravo, P.E.; Mullins, E.; Mullins, E.; Madan, R.; Taqueti, V.R.; Taqueti, V.R.; Steigner, M.; et al. Complementary Value of Cardiac Magnetic Resonance Imaging and Positron Emission Tomography/Computed Tomography in the Assessment of Cardiac Sarcoidosis. *Circ. Cardiovasc. Imaging* **2018**, *11*, e007030. [CrossRef] [PubMed]
8. Birnie, D.H.; Kandolin, R.; Nery, P.B.; Kupari, M. Cardiac manifestations of sarcoidosis: Diagnosis and management. *Eur. Heart J.* **2017**, *38*, 2663–2670. [CrossRef] [PubMed]