

Lucyna Opoka<sup>1</sup>, Monika Szturmowicz<sup>2</sup>, Karina Oniszh<sup>1</sup>, Damian Korzybski<sup>3</sup>, Zbigniew Podgajny<sup>4</sup>, Katarzyna Błasińska-Przerwa<sup>1</sup>, Małgorzata Szotkowska<sup>5</sup>, Iwona Bestry<sup>1</sup>

<sup>1</sup>Department of Radiology, National Tuberculosis and Lung Diseases Research Institute, Warsaw, Poland

<sup>2</sup>Ist Department of Lung Diseases, National Tuberculosis and Lung Diseases Research Institute, Warsaw, Poland

<sup>3</sup>II Department of Lung Diseases, National Tuberculosis and Lung Diseases Research Institute, Warsaw, Poland

<sup>4</sup>Affidea Masovian PET-CT Centre, Warsaw, Poland

<sup>5</sup>Department of Pathomorphology, National Tuberculosis and Lung Diseases Research Institute, Warsaw, Poland

## CT imaging features of thin-walled cavitary squamous cell lung cancer

### Abstract

Primary lung cancer manifesting as a thin-walled solitary cavity, occurs relatively infrequently. The most common histologic type presenting such a pattern is squamous cell cancer, followed by adenocarcinoma, and finally — large cell cancer. Cavitation is typically not seen in small cell lung cancer. Entities indicating malignancy of such lesions include irregular cystic wall, wall nodule formation, nodular septa or increased standard uptake on positron emission tomography (PET).

We are presenting a case of a squamous cell lung cancer manifesting on chest CT as a thin-walled septated cavity with irregular margins mimicking a cyst. The lesion was reported unchanged in a follow-up computed tomography after 3 months. A follow-up scan obtained 2 years after initial examination showed thickening of a cyst wall, solid structures within its lumen and thoracic lymph nodes enlargement.

**Key words:** lung cancer, cavitary lesion, solitary lung nodule, computed tomography (CT)

*Adv Respir Med.* 2019; 87: 114–117

### Introduction

Cavitary lung lesions are not a common finding on chest CT scans. Cavitation is more often observed in infectious diseases such as pneumonia caused by *Streptococcus pneumoniae*, *Staphylococcus aureus*, *Klebsiella pneumoniae*, *Haemophilus influenzae*, in tuberculosis and invasive aspergillosis.

Some benign lung diseases as septic emboli, granulomatosis with polyangitis (GPA) and rheumatoid nodules [1] should also be considered in a differential diagnosis.

Lung cancer with a solitary pulmonary cavity pattern is found in about 8% of all lung cancers, and it may present a big challenge for clinicians and radiologists [2]. In this article, we discuss diagnostic difficulties in a patient with squamous lung cancer manifesting as an irregular thin-walled cavity with septa.

### Case presentation

A 78-year-old male, a heavy smoker (65 pack-years), with chronic obstructive pulmonary disease (COPD) B category, diabetes type 2 and arterial hypertension was admitted to our hospital due to an abnormal lung lesion unexpectedly found on an abdominal CT scan performed for abdominal aortic aneurysm. He complained of a cough and sputum production that had lasted for about one year, and a small hemoptysis that appeared 6 weeks before the admission to our hospital and has lasted for 4 weeks.

Chest CT scan revealed emphysematous lungs and an abnormal irregular airspace with a 1.5 mm thick wall and internal septa, localized in the apical segment of the right lower lobe (Fig. 1 A, B). No suspicious infiltration was found on fiberoptic bronchoscopy. A congenital cystic pulmonary malformation or lung cancer were taken into consideration, hence a follow-up CT scan after 3 months was recommended.

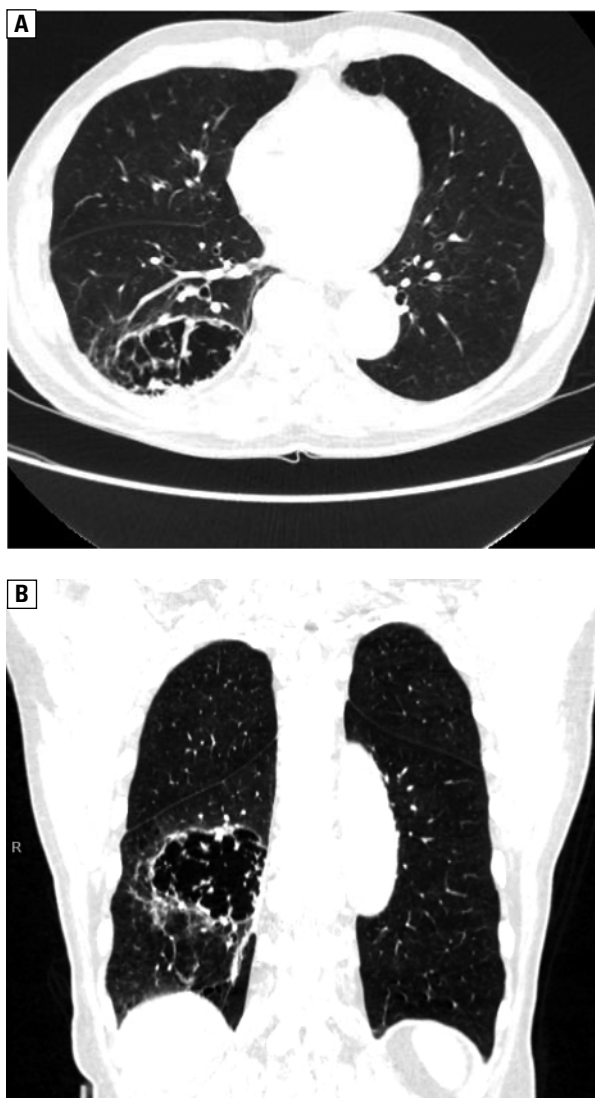
**Address for correspondence:** Lucyna Opoka, Department of Radiology, National Tuberculosis and Lung Diseases Research Institute, Płocka 26, 01–138 Warsaw, Poland, e-mail: lucyna.opoka@gmail.com

DOI: 10.5603/ARM.2019.0018

Received: 19.02.2019

Copyright © 2019 PTChP

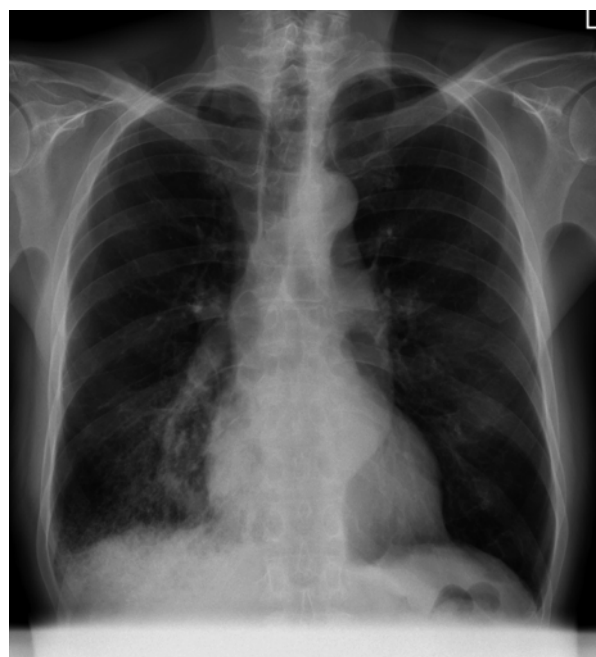ISSN 2451–4934



**Figure 1 A, B.** Baseline chest CT (2016), lung window, axial and coronal plane; abnormal irregular septated airspace in the apical segment of the right lower lobe

A follow-up CT scan obtained 3 months later showed no progression. The patient ignored multiple calls for follow-ups, he has been admitted to our hospital 22 months later, due to recurrent hemoptysis. Chest X ray showed a loss of volume of the right lower lobe, and a thick-walled cavity of 7 cm, surrounded by parenchymal opacities (Fig. 2).

CT scan revealed an irregular septated cavity with a 12 mm thick wall and abnormal tissue masses within its lumen (Fig. 3 A, B), loss of volume of the whole right lower lobe and enlarged subcarinal lymph nodes (15 mm in size). Radiological appearance of the lesion at that time was suggestive of lung tumor and a needle biopsy was recommended, nevertheless it hasn't been performed due to extensive emphysema.



**Figure 2.** Posteroanterior chest Xray (2018); loss of volume of the right lower lobe with a 7 cm thick-walled cavity surrounded by nodular opacities

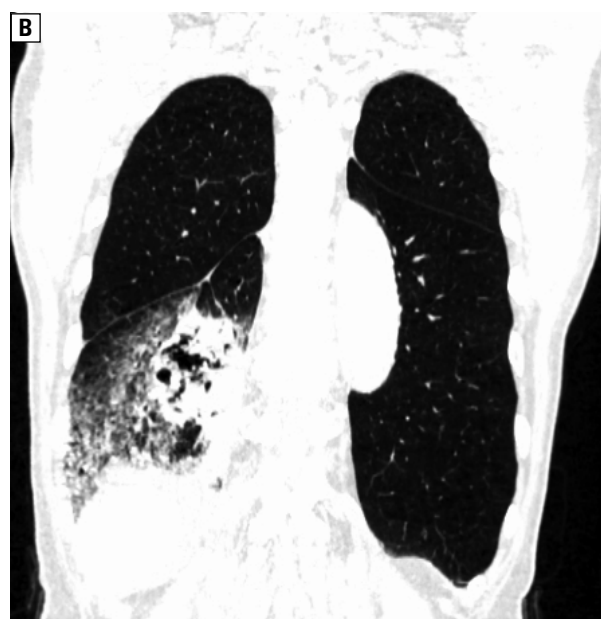
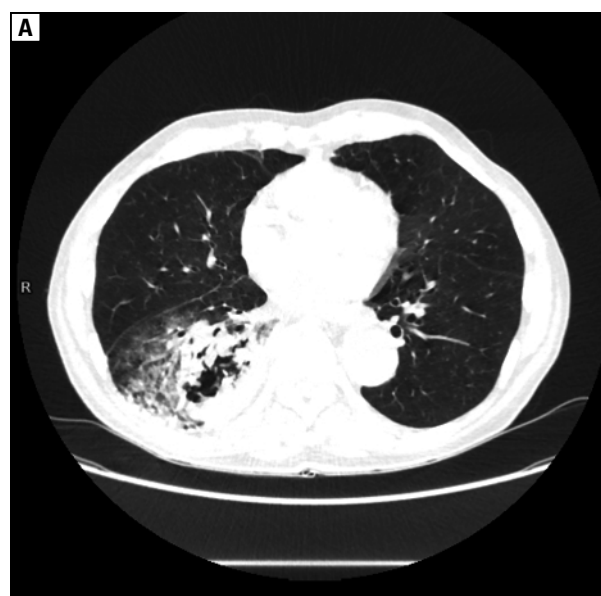Fibreoptic bronchoscopy with transbronchial, ultrasound guided, lymph node biopsy (EBUS) was inconclusive.

Fluorodeoxyglucose-positron emission tomography (FDG-PET) revealed an increased standard uptake value (SUV max.14.5) of tumor (Fig. 4) and increased SUV (max.6.5) of a subcarinal and left hilar node (max.9.2). Another increased SUV focus (max.11.9) was found within cranial skull bone. A skull tumor was confirmed by physical examination. An ultrasound guided needle biopsy of the tumor was performed, and a pathologist reported metastatic lesion from non-small cell lung cancer, probably squamous cell carcinoma. PDL1 expression was 20%. The patient has not been qualified for immunotherapy. Systemic chemotherapy could not be recommended due to a poor performance status of the patient, mental disability, substantial weight loss >10% and renal insufficiency. Hospice palliative care was administered.

## Discussion

Lung cancer is the most common malignancy worldwide, with about 14% of new cases in men and 13% — in women in 2018 [3]. It is also the most important cause of death in the adult population.

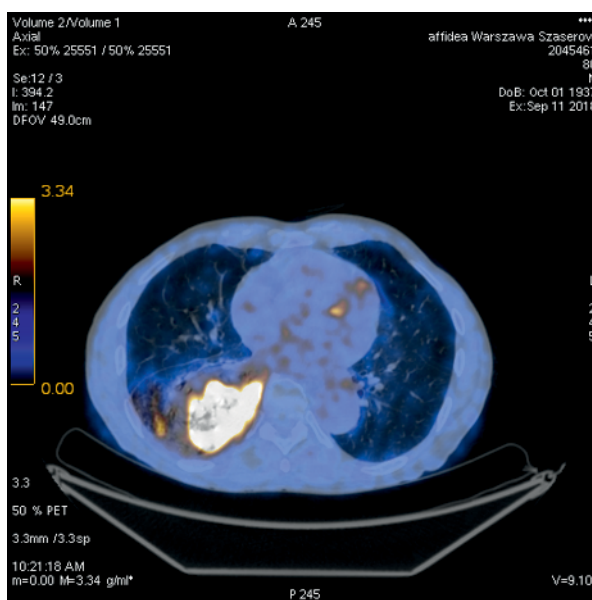
Cavitation in lung cancer can be found in 2–16% of diagnosed cases [4]. The walls of ca-



**Figure 3 A, B.** Chest CT scan (2018), lung window, axial and coronal plane; thick-walled septated cavity in the apical segment of the right lower lobe; the walls are much thicker than in 2016, central tissue structures and adjacent parenchymal consolidations with ground-glass component appeared

vities are usually thicker than 4 mm [5]. The histological diagnosis of cavitary lung cancers most often concerns squamous cell lung cancer, followed by adenocarcinoma and large cell lung cancer. Cavitation is not observed in small cell lung cancer [6].

Our case showed an irregular septated thin-walled cavity on initial CT scan. The cavity was found in a patient with extensive emphysema though it could not have been identified as a bulla. Smoking history, COPD diagnosis and hemoptysis



**Figure 4.** FDG PET/CT shows increased uptake in the abnormal irregular septated airspace

reported by our patient, strongly suggested diagnosis of a lung cancer.

Lung cancers presenting a thin-walled cavity pattern occur infrequently. Such a pattern is probably the result of check-valve mechanism initiated by cancer cell development within the alveolar wall. Check-valve mechanism causes gas accumulation within bronchioles and an increase in cystic airspace size over time [7].

A correct radiological diagnosis of a lung cancer presenting as a thin-walled cavity is still a big challenge. Malignant nature of such lesion may be considered in case of: irregular shape of the cyst, wall nodule formation, central solid tissue or septation [8]. Such cavities are often surrounded by ground-glass opacities confirmed by pathologist as neoplastic dissemination.

While in the presented case, the lung cancer was not excluded, the initial diagnosis could not have been made definitively. Two years later, the evidence of malignancy on radiological examination was obvious, due to thickening of the cavity walls, solid component within its lumen and enlarged thoracic lymph nodes.

Markedly increased standard uptake on FDG PET-CT of the cavity wall and lymph nodes as well as skull lesion, have been suggestive of lung cancer with metastatic skull lesion. The final diagnosis was made by a pathologist after the detection of cancer cells in a specimen obtained by US guided biopsy of a soft tissue component of a skull bone metastatic tumor.

In conclusion, the paper presents a rare case of a thin-walled cavity with a 22-month observation period during which a CT image evolution confirmed a malignancy. This case represents another good example of a variety of lung cancer patterns in CT imaging.

### Conflict of interest

The authors declare no conflict of interest.

### References:

1. Parkar AP, Kandiah P. Differential Diagnosis of Cavitory Lung Lesions. *J Belg Soc Radiol.* 2016; 100(1): 100, doi: [10.5334/jbr-btr.1202](#), indexed in Pubmed: [30151493](#).
2. Xue XY, Liu YX, Wang KF, et al. Computed tomography for the diagnosis of solitary thin-walled cavity lung cancer. *Clin Respir J.* 2015; 9(4): 392–398, doi: [10.1111/crj.12172](#), indexed in Pubmed: [24931383](#).
3. Siegel RL, Miller KD, Jemal A. Cancer statistics, 2018. *CA Cancer J Clin.* 2018; 68(1): 7–30, doi: [10.3322/caac.21442](#), indexed in Pubmed: [29313949](#).
4. Goto T, Maeshima A, Oyamada Y, et al. Cavitory lung cancer lined with normal bronchial epithelium and cancer cells. *J Cancer.* 2011; 2: 503–506, indexed in Pubmed: [21980325](#).
5. Woodring JH. Pitfalls in the radiologic diagnosis of lung cancer. *AJR Am J Roentgenol.* 1990; 154(6): 1165–1175, doi: [10.2214/ajr.154.6.2110722](#), indexed in Pubmed: [2110722](#).
6. Gadkowski LB, Stout JE. Cavitory pulmonary disease. *Clin Microbiol Rev.* 2008; 21(2): 305–33, table of contents, doi: [10.1128/CMR.00060-07](#), indexed in Pubmed: [18400799](#).
7. Iwata T, Nishiyama N, Nagano K, et al. Squamous cell carcinoma presenting as a solitary growing cyst in lung: a diagnostic pitfall in daily clinical practice. *Ann Thorac Cardiovasc Surg.* 2009; 15(3): 174–177, indexed in Pubmed: [19597393](#).
8. Qi Y, Zhang Q, Huang Y, et al. Manifestations and pathological features of solitary thin-walled cavity lung cancer observed by CT and PET/CT imaging. *Oncol Lett.* 2014; 8(1): 285–290, doi: [10.3892/ol.2014.2065](#), indexed in Pubmed: [24959262](#).