

Aleksandra Szczawińska-Popłonyk,¹ Anna Bręborowicz,¹ Renata Langfort²

¹Clinical Department of Pneumology, Paediatric Allergy, and Clinical Immunology, Third Department of Paediatrics, Poznan University of Medical Sciences, Poznan, Poland
Head of Department: A. Bręborowicz, MD, PhD

²Department of Pathology, Institute of Tuberculosis and Lung Diseases, Warsaw, Poland
Head of Department: R. Langfort, MD, PhD

Interstitial lung disease in the course of surfactant protein C deficiency coexisting with primary immunodeficiency — a case report

Abstract

Interstitial lung diseases in children are a diverse group in terms of aetiology and pathogenesis. Differential diagnosis should include infectious, immune, and metabolic disorders and hereditary surfactant protein C deficiency. We report a case of interstitial lung disease in the course of surfactant protein C deficiency and primary humoral immunodeficiency, providing a detailed discussion of the clinical, radiological, and histological findings.

Key words: interstitial pneumonia, surfactant protein C, immunodeficiency, children

Pneumonol. Alergol. Pol. 2010; 78, 3: 244–247

Introduction

Children's interstitial lung disease (chILD) is an umbrella term for a multitude of conditions whose aetiology and pathogenesis involve infectious, immune, and metabolic factors. For these reasons chILD is a challenge in terms of multidirectional differential diagnosis. The rare causes of chILD include hereditary disorders of surfactant homeostasis caused by defects in proteins B and C and the ABCA3 (ATP-binding cassette A3) transporter, which are associated with diverse clinical, radiological, and histological manifestations. We report a case of interstitial lung disease in the course of surfactant protein C deficiency and primary immunodeficiency.

Case presentation

A ten-year-old girl had been looked after by the Department of Pneumology, Paediatric Allergy, and Clinical Immunology since she was 18

months of age, at which time she first developed a respiratory infection complicated by respiratory failure. The chest X-ray at that time revealed disseminated interstitial changes in the lungs.

The pre- and perinatal history was unremarkable, the girl did not have a history of any illnesses as an infant and did not present with any worrying respiratory symptoms, nor did she have any family history of chronic lung disease, primary immunodeficiency syndromes, or autoimmune conditions. Physical examination revealed good nutritional status (body weight between the 25th and 50th percentiles), pale pink skin, impalpable peripheral lymph nodes, no changes in the oral and pharyngeal mucosa, hypertrophic tonsils, normal symmetrical vesicular breath sounds over the pulmonary fields, regular heart rate, and no hepatomegaly. No dyspnoea, cough, or reduced exercise tolerance were observed. Both resting and exertional oxygen saturation of haemoglobin values measured by capillary blood gas analysis and pulse oximetry were normal.

Address for correspondence: Dr n. med. Aleksandra Szczawińska-Popłonyk, Clinical Department of Pneumology, Paediatric Allergy, and Clinical Immunology, University of Medical Sciences, ul. Szpitalna 27/33, 60–572 Poznań, Poland, tel. +48 61 848 0111, fax +48 61 848 0111, e-mail: ola@malwa.com.pl

Received: 19.01.2010 r.
Copyright © 2010 Via Medica
ISSN 0867–7077

A detailed differential evaluation was carried out to establish the final diagnosis. Infections caused by the following agents were ruled out: respiratory viruses (respiratory syncytial virus [RSV], adenovirus, and parainfluenza viruses), hepatotropic viruses (hepatitis B virus [HBV], hepatitis C virus [HCV], and cytomegalovirus [CMV]), atypical bacteria (mycoplasmas and *Chlamydophila pneumoniae*), and fungi (*Aspergillus* and *Pneumocystis jirovecii*). Tests for cystic fibrosis, namely the sweat test and tests for 30 mutations of the *CFTR* gene, were negative. No precipitating antibodies to chicken, duck, or goose droppings were detected in the serum. Immunodiagnostic evaluation revealed immunodeficiency in the form of IgG3 subclass deficiency and C4 deficiency. An analysis of the principal subpopulations of peripheral blood lymphocytes by flow cytometry, blastic transformation test, and burst test revealed no abnormalities. The child was also evaluated for systemic connective tissue diseases. A transient elevation of the titres of antibodies to alveolar basement membrane and glomerular basement membrane typical of Goodpasture's syndrome was observed. From the age of four years the child had had elevated levels of antinuclear antibodies (positive at 1:40–1:160–1:320 dilutions with homogenous, homogenous-speckled, and homogenous-nucleolar patterns). The tests showed no antibodies typical of systemic lupus erythematosus: anti-Sm, anti-nDNA, anti-histone, or antibodies to ribosomal N protein, and no anti-SS-A or anti-SS-B antibodies (also present in Sjögren's syndrome), no lupus anticoagulant or antiphospholipid antibodies, no antibodies to Scl-70 or anticentromere antibodies typical of systemic sclerosis, no antisynthetase antibodies anti-Jo1 present in dermatomyositis, and no cANCA or pANCA observed in vasculitis (Wegener's syndrome and Churg-Strauss syndrome, respectively).

Due to the progression of pulmonary changes between 3 and 6 years of age, the girl was receiving glucocorticosteroid treatment, during which stabilisation of the radiological picture of the lungs was observed. However, the child developed complications in the form of osteoporosis, hypertension, and glucose intolerance.

From the beginning of the observation a chronic respiratory infection with a pathogenic bacterial flora was observed (*Pseudomonas aeruginosa*, *Streptococcus pneumoniae*, *Haemophilus influenzae*, *Neisseria* spp. and methicillin-sensitive *Staphylococcus aureus*).

It was not until an open lung biopsy and a histopathological examination were performed that

the final diagnosis could be established. Microscopic examination of the collected tissue samples revealed areas of uniform thickening of the interalveolar septi with moderate fibrosis, chronic inflammatory infiltrates, and alveolar epithelial hyperplasia. The lumina of the alveoli with pathologically changed walls contained: cholesterol crystal clefts surrounded by giant cells; macrophages with finely granular cytoplasm; and eosinophilic debris that gave a positive PAS reaction and a positive immunohistochemical reaction with surfactant apoprotein. Based on the histological picture a diagnosis of chronic pneumonitis of infancy (CPI) was made with changes consistent with cholesterol pneumonia, which might be associated with surfactant protein C deficiency.

The girl is now 10 years of age. The chest X-ray has shown progression of interstitial changes (Fig. 1), and high-resolution computed tomography (HRCT) has revealed progression of the nodular changes overlapping on intra- and interacinar septal thickening and isolated nodules (Fig. 2). The interstitial changes with the thickened septae have also increased in severity, especially in the basal segments and in the middle lobe. The radiological picture correlated with the progressive ventilation disturbances observed in spirometry (a 5% reduction of VC compared to 6 months earlier). Further abnormalities have included exercise intolerance and periodic desaturation on pulse oximetry and episodes of ineffective cough as well as reduced vesicular breath sounds and nail clubbing on physical examination. Due to the progression of the radiological changes and respiratory parameters on pulmonary function testing, the girl was started on systemic corticosteroids. Due to the clinical course of immunodeficiency associated with respiratory tract infections the girl was qualified for treatment with polyvalent immunoglobulins. The progressive nature of interstitial lung disease, despite having employed all the therapeutic options discussed above, suggests the necessity of considering lung transplantation in the future.

Discussion

Interstitial lung diseases in children are a diverse group of diseases in terms of aetiology and pathogenesis. The final diagnosis requires multidirectional investigations taking into account infectious, immune and metabolic causes, as no pathognomonic laboratory criteria currently exist. An interdisciplinary clinical, radiological, and histopathological consensus is currently the gold standard [1].

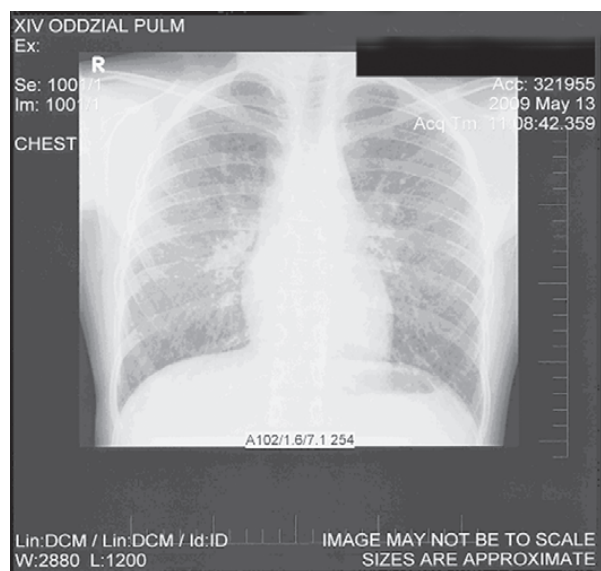


Figure 1. Chest radiological examination. Disseminated infiltrations in both lungs, most intensive in lower lobes, without features of peripheral obstruction

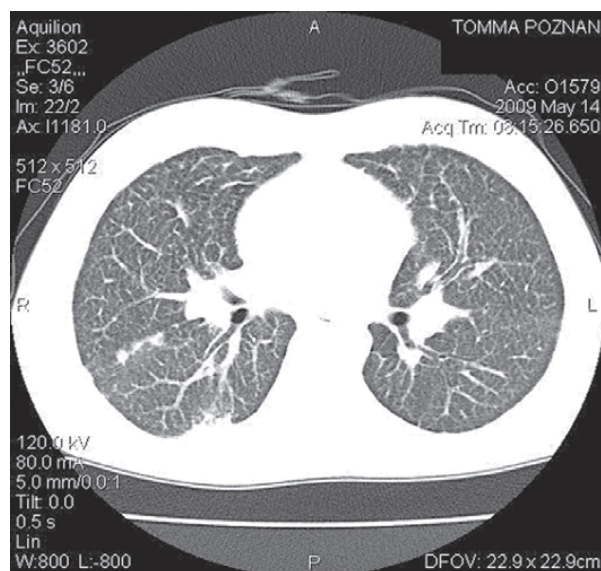


Figure 2. Computed tomography of the chest with contrast. Thickening of the intra- and interlobular septa, most prominent in basilar segments and on the base of the middle lobe, as well as disseminated fine nodules and single larger nodules

In the case of our patient the non-invasive diagnostic investigations allowed us to identify the mutually overlapping pathogenetic elements of interstitial lung disease and primary immunodeficiency. The humoral immunodeficiency comprising IgG3 and C4 deficiencies predisposes to infections and increases the risk of autoimmune disorders [2].

Indeed, chronic respiratory infection with pathogenic bacterial flora and the presence of au-

toantibodies was observed throughout the entire clinical observation period. However, the possibility of antinuclear antibodies being present in various rheumatic diseases, pulmonary fibrosis, bacterial and viral infections, and in drug reactions should also be taken into account.

As far as the differential diagnosis of interstitial pneumonia in children is concerned, tests for the known aetiological factors of the disease are recommended, such as tests for infectious pathogens (viral pathogens: adenovirus, CMV, EBV, HIV; bacterial pathogens: *Chlamydomphila*, *Mycoplasma*), tests for precipitating antibodies to environmental organic antigens, the sweat test for cystic fibrosis, and immunological testing for immunodeficiency syndromes and systemic connective tissue disorders [3].

High-resolution computed tomography is a valuable imaging method for the monitoring of interstitial lung disease, and its high degree of standardisation allows one to narrow down the differential diagnosis. However, the characteristic radiological picture only in a few selected cases, such as alveolar proteinosis and haemosiderosis, justifies resignation from performing a lung biopsy [4].

The lung biopsy provides an opportunity to evaluate interstitial inflammation, thickening of the interalveolar septi, the presence of inflammatory cells, alveolar filling, and alveolar fibrosis. In our case, the histopathology was conclusive for establishing the final diagnosis. Results of a multicentre study conducted in the United States summarising data on lung biopsies in small children [5] showed that it was possible to make the diagnosis in as many as 88% of the cases based on the histological picture of interstitial lung disease. Most commonly, in 24.6% of the subjects, disseminated developmental anomalies were detected, associated with prenatal factors that resulted in abnormal lung growth (skeletal and neuromuscular anomalies, cardiovascular malformations limiting pulmonary blood flow, abdominal wall defects and chromosomal aberrations, e.g. trisomy 21) and with postnatal factors (neonatal chronic lung disease). The less frequent conditions included: pulmonary interstitial glycogenosis (PIG), neuroendocrine cell hyperplasia of infancy (NEHI), and defects of surfactant protein C (SP-C) synthesis or the ABCA3 transporter, accounting for 6.95% of all the investigated cases. Abnormalities of SP-C expression may be characterised by a variety of phenotypes and, as was the case with our patient, cause few symptoms in early childhood and lead to interstitial lung disease [6–9]. An SP-C defect may result from the lack of a mature protein C, accu-

mulation of abnormally formed precursor protein pro-SP-C, or both these mechanisms combined. The clinical diagnosis may be confirmed by testing for mutations of the protein C gene, surfactant gene, and the ABCA3 transporter gene. In the case of our patient, the diagnosis was established on the basis of the history, physical examination, radiological studies and the characteristic histopathological picture. Additional factors, such as infections and drugs that may increase accumulation of the toxic pro-SP-C, contribute to the progression of lung disease [10, 11]. The co-existence of humoral immunodeficiency predisposing our patient to recurrent respiratory infections should be considered an adverse prognostic factor for the further evolution of her interstitial lung disease.

References

1. Leslie K.O. My approach to interstitial lung disease using clinical, radiological and histopathological patterns. *J. Clin. Pathol.* 2009; 62: 387–401.
2. Kumar A., Teuber S.S., Gershwin E. Current perspectives on primary immunodeficiency diseases. *Clin. Dev. Immunol.* 2006; 13: 223–259.
3. Paiva M.A., Amaral S.M. Chronic interstitial lung diseases in children. *J. Bras. Pneumol.* 2009; 35: 792–803.
4. Elicker B., Pereira C.A., Webb R., Leslie K.O. High-resolution computer tomography patterns of diffuse interstitial lung disease with clinical and pathological correlation. *J. Bras. Pneumol.* 2008; 34: 715–744.
5. Deutsch G.H., Young L.R., Detering R.R. et al. Diffuse lung disease in young children. *Am. J. Respir. Crit. Care Med.* 2007; 176: 1120–1128.
6. Pinheiro Ribeiro Lyra P., de Albuquerque Diniz M.E. The importance of surfactant on the development of neonatal pulmonary diseases. *Clinics* 2007; 62: 181–190.
7. Percopo C., Cameron H.S., Nogee L.M., Peltinato G., Montella S., Santamaria F. Variable phenotype associated with SP-C gene mutations: fatal case with the I73T mutation. *Eur. Resp. J.* 2004; 24: 1072–1073.
8. McFetridge L., Mc Morrow A., Morrison P.J., Shields M.D. Surfactant metabolism dysfunction and childhood interstitial lung disease (child). *Ulster Med. J.* 2009; 78: 7–9.
9. Hartl D., Griesse M. Interstitial lung disease in children — genetic background and associated phenotypes. *Resp. Res.* 2005; 6: 32–48.
10. Beers M.F., Mulugeta S. Surfactant protein C biosynthesis and its emerging role in conformational lung disease. *Annu. Rev. Physiol.* 2005; 67: 663–696.
11. Lawson W.E., Grant S.W., Ambrosini V. et al. Genetic mutations in surfactant protein C are a rare cause of sporadic cases of IPF. *Thorax* 2004; 59: 977–980.