

Witold Owczarek<sup>1</sup>, Tomasz Targowski<sup>2</sup>, Katarzyna Łebkowska<sup>1</sup>, Elwira Paluchowska<sup>1</sup>

<sup>1</sup>Department of Dermatology, Military Institute of the Health Services in Warsaw, Poland

Head: Prof. S. Zabielski

<sup>2</sup>Department of Internal Medicine, Pneumology and Allergology, Military Institute of the Health Services in Warsaw, Poland

Head: Prof. T. Plusa

## Tubercular inflammation of cervical lymph nodes with a colliquative tuberculosis focus — a case study

### Abstract

Cutaneous tuberculosis is a specific form of tuberculosis, characteristic of a differentiated clinical picture and resulting from either endo- or exogenous way of infection, immunological mechanisms and unfavourable conditions for mycobacterium development. The atypical course and symptoms of the disease may cause certain difficulties in obtaining a proper diagnosis and, in consequence, result in delayed onset of appropriate treatment. When diagnosing cutaneous tuberculosis, a broad apparatus of differential diagnostics should be applied, taking into account other diseases such as leishmaniasis, actinomycosis, leprosy or deep mycoses.

We report a case of lymph node tuberculosis and of colliquative tuberculosis of the skin, at first erroneously diagnosed as actinomycosis, complicated by multiform erythema.

In the reported case, no tuberculous bacilli were identified in bacteriological evaluations of biopsies collected from the skin changes. The final diagnosis of the disease was determined by the presence of specific granulation tissue in the last performed histopathological studies, as well as by hypersensitivity to tuberculin and the presence of mycobacterial DNA in PCR evaluation. According to the authors, in case of clinically suspected cutaneous tuberculosis, repeated (several) histopathological studies of samples from observed changes seem to be fairly justified. The results of histopathological studies should be completed by one of the methods of oligomycobacterial material evaluation, e.g. by identification of mycobacterial genetic material by means of nucleic acid amplification in the PCR method.

**Key words:** dermal tuberculosis, colliquative tuberculosis, inflammation of lymphatic nodes, polymerase chain reaction

**Pneumonol. Alergol. Pol. 2009; 77: 417–421**

### Introduction

Pulmonary tuberculosis is the commonest form of tuberculosis in Poland, as well as in the world. Extrapulmonary tuberculosis is a rather rare disease, most often affecting: the pleura, lymph nodes, urinary tract and bones, while dermal localisation of tuberculosis is even rarer. In North America and Europe, cutaneous tuberculosis is identified in less than 1% of all patients with this disease [1–4]. Skin changes in the course of tuberculosis may result from direct skin infection, as well as from immunological reaction in respon-

se to a specific process of different localisation in the organism (so-called tuberculid) [1, 5–8].

Cutaneous forms of tuberculosis include lupus tuberculosis, tuberculous lymphadenitis, colliquative tuberculosis, verrucous tuberculosis and ulcerous tuberculosis [5, 9]. Procedures of differential diagnostics, applied to identify tuberculosis of lymph nodes and skin, should also take into account other disease processes, such as, among others, leishmaniasis, actinomycosis, leprosy and mycotic infections [7]. Overt difficulties with microbiological diagnosis and the atypical character of skin changes may greatly impede correct

**Address for correspondence:** Witold Owczarek, Department of Dermatology, Military Institute of the Health Services, Szaserów 128, 00–909 Warsaw, Poland, tel. (+48 22) 681 64 49, e-mail: witold.owczarek@dermedicus.pl

Received: 16.09.2008  
Copyright © 2009 Via Medica  
ISSN 0867–7077

diagnosis, resulting in delayed onset of therapy with antimycobacterial agents [7, 8, 10, 11].

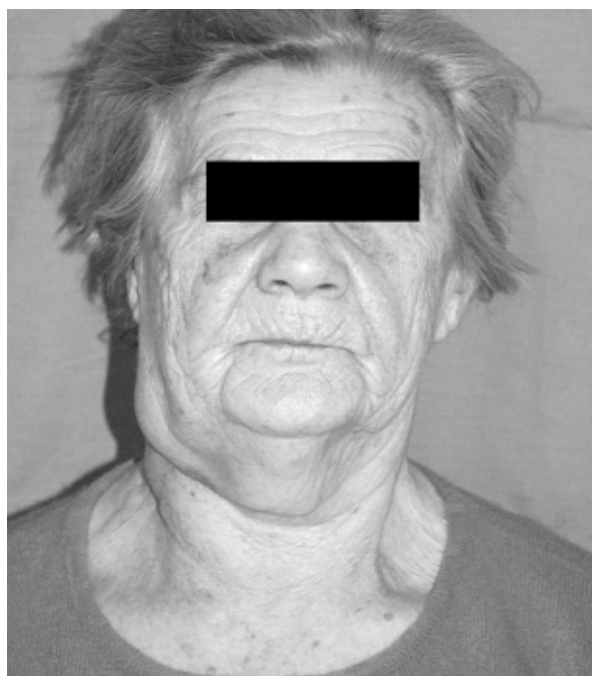
This report presents a case of lymph node tuberculosis with colliquative tuberculosis of the skin, at first erroneously diagnosed as actinomycosis, complicated by multiform erythema.

### Case report

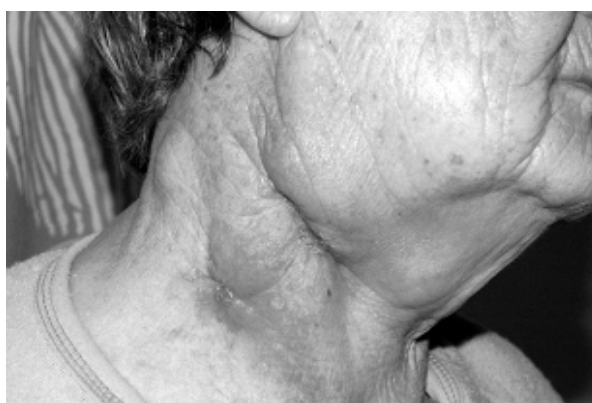A 75 year-old female patient was admitted to the Department of Dermatology at the Military Institute of the Health Services with referral diagnosis of multiform erythema, which occurred after the administration of a combined treatment of amoxycillin and clavulanic acid. The patient received that antibiotic for suspected cervical actinomycosis. Skin changes had occurred on the right side of the patient's neck in August 2007, prompting her to seek outpatient medical help. The applied protocol of management included surgical incisions of the skin changes, together with repeated draining. Material samples were collected for cultures (no bacterial growth on media), a specimen was collected for histopathological study (unspecific inflammatory infiltration with mononuclear cells) and antibiotics were empirically administered, such as procaine penicillin, cefoxitin, tetracycline and clindamycin. However, results were ineffective. Following a subsequent cycle of antibiotic therapy (amoxycillin with clavulanic acid), enhanced multiform erythema occurred, for which the patient was referred to the Department of Dermatology. On admission, disseminated erythematous-oedematous skin changes were found, well separated from the surrounding area and with the highest intensity on the distal sections of upper and lower limbs, as well as on the patient's trunk.

Multiform erythema is a disease of complex aetiology. The most frequent provoking factors include viral (HSV1 and HIV 2, Coxsackie) and bacterial infections (especially streptococci), as well as medicinal agents (antibiotics, barbiturates, salicylates) [9].

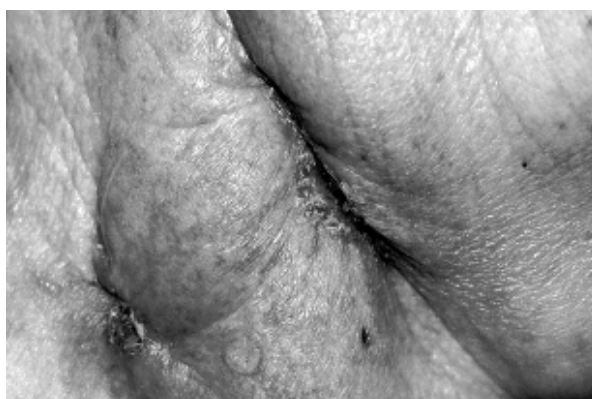Also, a visible focus of enlarged lymph nodes was found on the right side of the patient's neck (see Fig. 1). Skin within the focus was reddened, while two fistulas of approximately 0.5 cm in diameter were visible in its central part (see Figs. 2, 3). Beside the above-mentioned skin changes, no other abnormalities were found, either in physical examination or in the patient's anamnesis. In basic laboratory tests, the only observed deviations from normal values included leukocytosis ( $12\,200/\text{mm}^3$ ),



**Figure 1.** Tubercular focus of the right submandibular area



**Figure 2.** Infiltrations with fistulae in the area of submandibular lymphatic nodes tubercular inflammation



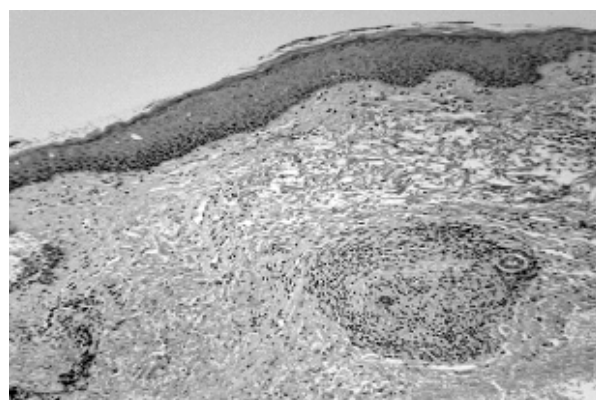
**Figure 3.** Colliquative tuberculosis focuses in lymphatic nodes changes area

slightly elevated erythrocytation rate (21 mm/h) and elevated alpha1 (4.3%) and alpha2 (13.8%) fractions in proteinogram. Radiological chest examination revealed calcified lymph nodes in hilus of the left lung and paraaortic lymph nodes, while the pulmonary parenchyma was normal.

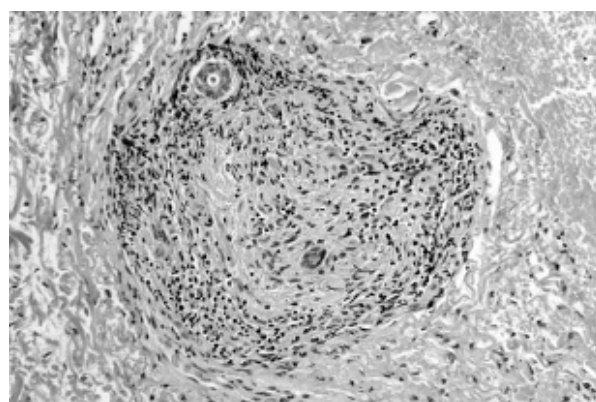
In consideration of the high intensity of multiform erythematous changes, a systemic treatment with glyocorticosteroids was administered. Prednisone was applied in the initial dose of 40 mg/d, obtaining quick regression of erythematous changes. Simultaneously, differential diagnostics was continued, regarding the dermonodular changes on the left cervical surface. Sonographic imaging of the cervical lymph nodes revealed a package of enlarged, changed lymph nodes in the right, lateral region of the neck, where the largest node was 13 × 7 mm in size, while supra- and subclavicular lymph nodes remained unchanged.

Serological tests for the presence of antibodies against HIV, HCV, HBsAg, unheated serum regin test and microbiological evaluation of fistula swab brought negative results. The patient had no history of tuberculosis, nor had ever had any direct contact with a sputum-positive patient. Nevertheless, following a pneumological consultation and taking into account the skin changes and the presence of calcifications in the mediastinal lymph nodes, tuberculin reaction test was recommended after steroid therapy, with bacteriological and histopathological studies to detect tuberculosis. Three specimens were collected from cervical skin and lymphatic changes for repeated histopathological evaluations, bacteriological analysis and genetic studies by the PCR (polymerase chain reaction) method for the presence of TB bacilli. No biopates with tubercle bacilli were found, either in bacterioscopy or in classical culture, while the presence of *Mycobacterium tuberculosis complex* was confirmed in a PCR study performed by the MTD Gen-Probe method.

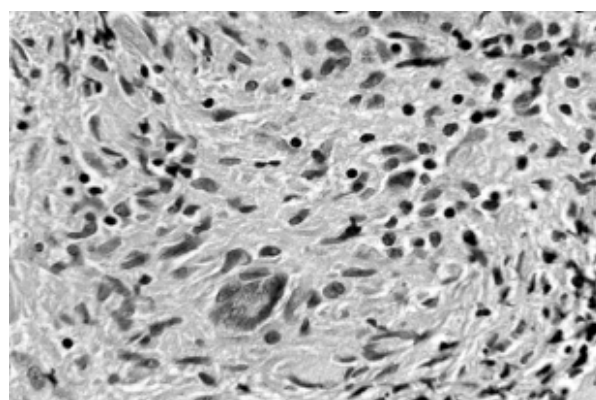
In histopathological evaluation of a skin specimen collected from the periphery of the focus of disease, typical tuberculous granulation tissue was found with Langhans giant cells, surrounded by epithelioid cells and lymphocytes (Figs. 4–6). The tuberculin test, performed after steroid therapy termination, brought overtly positive results (infiltration diameter = 22 mm). Consequently, taking into account the entire clinical picture, cutaneous and lymph node tuberculosis was diagnosed. A combined medical treatment was applied, including riphampicine (0.6 g/d), ioniasid (0.3 g/d) and pirasinamid (1.5 g/d), obtaining total healing of the skin changes and normalization of the affected cervical lymph nodes.



**Figure 4.** Histopathological examination. Tuberculous granulations is visible in upper dermis layers. H+E Staining. Magnification (c 200×)



**Figure 5.** Histopathological examination. Typical tubercular granuloma with giant Langhans like cells in epithelial cells and lymphocytes environment. H+E Staining. Magnification (c 400×)



**Figure 6.** Histopathological examination. Tubercular granulation. H+E Staining. Magnification (c 600×)

## Discussion

All the risk factors for tuberculosis infection may be divided into the social and the biological. The social risk factors include poor social and living conditions, close contact with already infec-

ted people, and migration of people, while biological risk factors include medical conditions with weakened immunity of the cellular type, such as neoplastic diseases, AIDS, diabetes mellitus, severe renal insufficiency, malnutrition or immunosuppressive therapy [7, 12–14]. In developed countries, cutaneous tuberculosis is one of the least common forms of this disease. Its prevalence, according to various sources of data, varies between 1% and 4.4% of all forms of tuberculosis [4, 13–18]. Cutaneous tuberculosis is more frequently observed in women, including the discussed colliquative tuberculosis; its total prevalence rate in women being 1.5 times higher than in men [19]. Cutaneous tuberculosis may result both from exogenous infection (by penetration of the skin by tubercle bacilli which pass through injured epidermis) and by blood-derived dissemination or from skin affection by continuities of disease foci in other organs [16]. Typical forms of cutaneous tuberculosis, resulting from exogenous infection, include ulcerous and papillous tuberculosis [1, 8, 16, 20]. The ulcerous form most often develops in patients with immunosuppression, while the papillous form is characteristic of subjects with preserved anti-tuberculous cellular immunity [1, 20, 21]. Most frequently, skin affection processes, as observed in the course of tuberculosis, are induced by an endogenous mechanism in result of secondary dissemination of tubercle bacilli from an intrasystemic focus via blood or lymphatic vessels or by continuity from other infected tissues [4, 13, 14, 22]. Then, painless infiltrations occur in the subcutaneous tissue with manifested tendency towards malacia, ulcerations and fistulas (the colliquative form of tuberculosis) [1, 4, 23]. In general clinical practice, the much lower incidence of tuberculosis and rarely observed extra-pulmonary localisations of this disease are at the base of many diagnostic problems, resulting, among others, from less and less practical experience among clinical physicians of this type of illness.

One of the difficulties in properly diagnosing cutaneous tuberculosis is also the comparatively slight characteristic appearance of skin changes which, in the initial period of the disease, resemble other dermatological diseases, such as mycoses or, as in the described case, actinomycosis [7, 24]. Diagnosis is often further complicated by the oligomycobacterial course of the disease. Following the definition in the Official Journal of the European Union, a confirmed or probable case of tuberculosis is such a case which is confirmed by positive culture result or by two positive results of bacte-

rioscopic evaluation. In turn, a possible case of tuberculosis is such a case in which clinical symptoms occur, which are characteristic of the disease, and where X-ray image is conformable with the picture of active tuberculosis of any organ, while laboratory tests give negative results [25].

Regarding the reported case, no tubercle bacilli were found, either in bacterioscopy or in cultures, while the genetic material of *Mycobacterium tuberculosis* was revealed in the skin changes by PCR technique. Though that observation reflected a probable, rather than a confirmed case of the disease, the regression of changes after the application of full antituberculous therapy, following the earlier long-term, ineffective antibiotic therapy, speaks in favour of a tuberculous background to the skin changes. In the reported case, no biopsates with tubercle bacilli were identified in bacteriological studies of the skin changes, while the final diagnosis took into account the presence of tuberculous granulation tissue in the last histopathological study, the presence of bacilli DNA, revealed by PCR, and oversensitivity to tuberculin. According to many authors, when cutaneous tuberculosis is clinically suspected, it is justified to perform several biopsies followed by several histopathological evaluations of the material collected from observed changes, the results of which should be completed by one of the methods of oligomycobacterial material evaluation, e.g. by an identification of mycobacterial genetic material by amplification of nucleic acids in the PCR method [26–28].

It was impossible to determine the source of infection in the reported patient. The patient denied either any direct contact with person(s) who might potentially have been infectious or a stay in any environment with an increased risk of tuberculosis. Taking into account the patient's age group, she is healthy with no positive family history of internal diseases; neither had she received any long-term medical therapy nor reported any ailments before. She at first neglected the enlarged lymph nodes, palpable on the lateral surface of her neck. Only the occurrence of large nodules and of an inflammatory condition prompted her to seek medical help. Neither the initial outpatient treatment nor the performed surgical intervention brought any improvement and only the occurrence of generalised erythematous, drug-induced changes brought the patient to hospital, triggering detailed and careful laboratory diagnostics, the results of which brought proper diagnosis and enabled the administration of appropriate therapy.

## References

- Korzeniewska-Koseła M., Michałowska-Mitczuk D. Gruźlica pozapłucna. Gruźlica w praktyce lekarskiej (*Extrapulmonary tuberculosis. Tuberculosis in Clinical Practice*). Ewa Rowińska-Zakrzewska, PZWL Warszawa 2000.
- Szczuka I. Gruźlica w Polsce w 2004 roku (*Tuberculosis in Poland in 2004*). Przegl. Epidemiol. 2006; 60: 529–536.
- Saral Y., Coskun B.K., Ozturk P., Bulut Y., Cobanoglu B. Multiple metastatic tuberculosis abscesses in a patient with Pott disease and lung tuberculosis: a case report. J. Cutan. Pathol. 2005; 32: 629–633.
- Yates V.M., Ormerod L.P. Multiple metastatic tuberculosis abscesses in a patient with Pott disease and lung tuberculosis: a case report. J. Cutan. Pathol. 2005; 32: 629–633.
- Tappeiner G., Wolff K. Tuberculosis and other mycobacterial infections. In: T.B. Fitzpatrick, A.Z. Elsen, K. Wolff, I.M. Freedberg, K.F. Austen (eds.). *Dermatology in general medicine*. McGraw-Hill, New York, 1999; 2274–2292.
- Woźniacka A., Schwartz R.A., Sysa-Jędrzejowska A., Borun M., Arkuszewska C. Lupus vulgaris: report of two cases. Int. J. Dermatol. 2005; 44: 299–301.
- Bravo F.G., Gotuzzo E. Cutaneous tuberculosis. Clin. Dermatol. 2007; 25: 173–180.
- Lai-Cheong J.E., Perez A., Tang V., Martinez A., Hill V., Menagé Hdu P. Cutaneous manifestations of tuberculosis. Clin. Exp. Dermatol. 2007; 32: 461–466.
- Jabłońska S., Majewski S. Choroby skóry i choroby przenoszone drogą płciową (*Dermal diseases and sexually transmitted diseases*). Wydawnictwo Lekarskie PZWL, Warszawa 2005; 63–74.
- Thomas S., Suhas S., Pai K.M., Raghu A.R. Lupus vulgaris — report of a case with facial involvement. Br. Dent. J. 2005; 12: 135–137.
- Güclüer H., Demirçay Z., Gürbüz O. Cutaneous tuberculosis. Scand. J. Infect. Dis. 2000; 32: 434–436.
- Barbagallo J., Tager P., Ingleton R., Hirsch R.J., Weinberg J.M. Cutaneous tuberculosis: diagnosis and treatment. Am. J. Clin. Dermatol. 2002; 3: 319–328.
- Zouhair K., Akhdari N., Nejiam F., Ouazzani T., Lakhdar H. Cutaneous tuberculosis in Morocco. Int. J. Infect. Dis. 2007; 11: 209–212.
- Yasmeen N., Kanjee A. Cutaneous tuberculosis: a three year prospective study. J. Pak. Med. Assoc. 2005; 55: 10–12.
- Fariña M.C., Gegundez M.I., Piqué E. i wsp. Cutaneous tuberculosis: a clinical, histopathologic, and bacteriologic study. J. Am. Acad. Dermatol. 1995; 33: 433–440.
- Serafin A., Chodyncka B. Gruźlica skóry (*Cutaneous tuberculosis*). Przegl. Dermatol. 2008; 95: 230–233.
- Ho C.K., Ho M.H., Chong L.Y. Cutaneous tuberculosis in Hong Kong: an update. Hong Kong Med. J. 2006; 12: 272–277.
- Hamada M., Urabe K., Moroi Y., Miyazaki M., Furue M. Epidemiology of cutaneous tuberculosis in Japan: a retrospective study from 1906 to 2002. Int. J. Dermatol. 2004; 43: 727–731.
- Starzycki Z. Cutaneous tuberculosis treated at the Dermatology Clinic Medical Academy in Cracow 1963–1987. Epidemiological analysis. Przegl. Dermatol. 1990; 77: 34–39.
- Foo C.C., Tan H.H. A case of tuberculosis verrucosa cutis—undiscovered for 44 years and resulting in fixed-flexion deformity of the arm. Clin. Exp. Dermatol. 2005; 30: 149–151.
- Tigoulet F., Fournier V., Caumes E. Clinical forms of the cutaneous tuberculosis. Bull. Soc. Pathol. Exot. 2003; 96: 362–367.
- Flisiak I., Wierzbicka B., Chodyncka B. Tuberculosis colliquativa curtis (scrofuloderma) — opis przypadku (*case report*). Przegl. Dermatol. 2001; 88: 251–253.
- Meyer S., Naumann L., Landthaler M., Vogt T. Lupus vulgaris caused by Mycobacterium bovis ssp. caprae. Br. J. Dermatol. 2005; 153: 220–222.
- Pawlaczyk M., Gutowska-Ryters A., Janicka-Jedyńska M., Kaniowska J. Przypadek gruźlicy toczniowej o 40-letnim przebiegu (*A case of lupous tuberculosis with 40-year course of disease*). Przegl. Dermatol. 2006; 94: 361–365.
- Official Journal of the European Union of June 18, 2008; L159/46.
- Margall N., Baselga E., Coll P., Barnadas M.A., de Moragas J.M., Prats G. Detection of Mycobacterium tuberculosis complex DNA by the polymerase chain reaction for rapid diagnosis of cutaneous tuberculosis. Br. J. Dermatol. 1999; 135: 231–236.
- Welsh O., Vera-Cabrera L., Fernández-Reyes M., Gómez M., Ocampo J. Cutaneous tuberculosis confirmed by PCR in three patients with biopsy and culture negative for Mycobacterium tuberculosis. Int. J. Dermatol. 2007; 46: 734–735.
- Negi S.S., Basir S.F., Gupta S., Pasha S.T., Khare S., Lal S. Comparative study of PCR, smear examination and culture for diagnosis of cutaneous tuberculosis. J. Commun. Dis. 2005; 37: 83–92.