

Vascular Deformation Mapping (VDM) of Thoracic Aortic Enlargement in Aneurysmal Disease and Dissection

Nicholas S. Burris¹, Benjamin A. Hoff^{1,2}, Ella A. Kazerooni¹, and Brian D. Ross^{1,2,3}

¹Department of Radiology; ²Center for Molecular Imaging; and ³Department of Biological Chemistry, University of Michigan, Ann Arbor, MI

Corresponding Author:

Nicholas Burris, MD

Department of Radiology, University of Michigan, 1500 E. Medical Center Drive, TC B1-132, SPC-5030, Ann Arbor, MI 48109-5030; E-mail: nburris@med.umich.edu

Key Words: aortic aneurysm, spatial Jacobian, aortic dissection, 3D printing, aneurysmal enlargement, vascular deformation mapping

Abbreviations: Vascular deformation mapping (VDM), abdominal aortic aneurysm (AAA), thoracic aortic aneurysm (TAA), electrocardiogram (ECG), computed tomography angiography (CTA), Hounsfield unit (HU), computed tomography (CT), matrix metalloproteinases (MMPs)

ABSTRACT

Thoracic aortic aneurysm is a common and lethal disease that requires regular imaging surveillance to determine timing of surgical repair and prevent major complications such as rupture. Current cross-sectional imaging surveillance techniques, largely based on computed tomography angiography, are focused on measurement of maximal aortic diameter, although this approach is limited to fixed anatomic positions and is prone to significant measurement error. Here we present preliminary results showing the feasibility of a novel technique for assessing change in aortic dimensions, termed vascular deformation mapping (VDM). This technique allows quantification of 3-dimensional changes in the aortic wall geometry through nonrigid coregistration of computed tomography angiography images and spatial Jacobian analysis of aortic deformation. Through several illustrative cases we demonstrate that this method can be used to measure changes in the aortic wall geometry among patients with stable and enlarging thoracic aortic aneurysm and dissection. Furthermore, VDM results yield observations about the presence, distribution, and rate of aortic wall deformation that are not apparent by routine clinical evaluation. Finally, we show the feasibility of superposing patient-specific VDM results on a 3-dimensional aortic model using color 3D printing and discuss future directions and potential applications for the VDM technique.

INTRODUCTION

The thoracic aorta is the largest blood vessel in the human body and is subject to most extreme hemodynamic forces. A healthy aorta is extremely durable, and it is able to absorb forces generated by the heart owing to its thick walls and its elastic nature. Because of multiple factors (eg, hypertension, atherosclerosis, genetic aortic syndromes, infection), the structural integrity and elasticity of the aortic wall can deteriorate, leading to progressive dilation of the aortic lumen and formation of aortic aneurysm (1). Aortic dissection is a related form of aortic disease characterized by tearing of the inner layers of the aortic wall (ie, intima and media), leading to the creation of a false lumen—or channel—within the aortic wall itself, which is structurally compromised and is subjected to high pressures. This results in aneurysm formation in ~60% of patients with chronic aortic dissection of the descending thoracic aorta (Stanford type B) (2). The incidence of aortic aneurysm is increasing in the US population, and mildly dilated aortas are being incidentally detected at higher rates owing to increased use of thoracic cross-sectional imaging for nonaortic indications (eg, lung cancer screening) (3). Recent data suggest that the prevalence of thoracic aortic

dilation (>4 cm) is ~3% of individuals older than 55 years of age, which, on the basis of current US population estimates, means that ~2.7 million people in the USA would be recommended to undergo regular imaging of the thoracic aorta on the basis of the current American Heart Association guidelines for imaging surveillance (4-8).

Imaging surveillance has a central role in the management of asymptomatic patients with aortic disease. The vast majority of patients with an aortic aneurysm, ~95%, are asymptomatic until the aneurysm ruptures, and only 40% of patients in whom the aneurysm ruptures reach the hospital alive (6, 9). Although the topic of aortic enlargement in abdominal aortic aneurysm (AAA) before and after endovascular repair has been the focus of significant research effort, the natural history and mechanisms of thoracic aortic aneurysm (TAA) progression remain poorly understood, and only a handful of studies have attempted to measure growth rates of the thoracic aorta (10-16). A major limitation in improving our understanding of TAAs is that the current clinical imaging surveillance techniques rely primarily on measurement of maximal aortic diameter. This parameter has been most widely studied and is shown to correlate with future

risk of aneurysm rupture (17). Although the simplicity of diameter measurements is appealing, this approach is subject to a high degree of measurement error, in the range of 2–5 mm despite optimal measurement technique (18, 19). Error of this magnitude makes confident determination of aortic enlargement challenging considering that typical aortic growth rates are slow (eg, 1 mm/y in the ascending aorta and 3 mm/y in the descending aorta), and this issue is further compounded when shorter follow-up intervals are analyzed (3 or 6 months) and when the aortic geometry is ovoid (17).

Although several sections of the aorta are vertically oriented and can be viewed in cross-section on axial images, most of the aorta cannot be viewed in cross-section on standard image planes, requiring image-processing software to effectively straighten the aorta and allow true orthogonal diameter measurements to be made. The 2010 ACCF/AHA/AATS/ACR/ASA/SCA/SCAI/SIR/STS/SVM Guidelines for the Diagnosis and Management of Patients With Thoracic Aortic Disease was the first set of guidelines to raise this issue and to recommend standard measurement locations in addition to measurement of maximal aortic diameter (4). Even with orthogonal measurements, the aorta is often not perfectly round in the cross-section, but it is rather ovoid or irregular, particularly in the setting of disease, further compounding the issue of exactly which diameter measurements to record and use for follow-up. Measuring the aortic diameter at predefined anatomic locations fails to capture interval growth at nonmaximal locations, and this measurement does not detect the components of aortic enlargement in circumferential or longitudinal directions. Height-/weight-adjusted aortic area has been proposed as a better predictor of future rupture than maximal diameter, and several studies have investigated the use of volumetric measurements of TAA and AAA to improve the sensitivity for detecting aortic growth (10, 20–24). However, similar to diameter measurements, measurement of aortic area and volumetric should be performed at predetermined anatomic boundaries to ensure that measurements are comparable between studies, and small focal changes in aortic dimension may be camouflaged by a volumetric measurement approach. Although area or volume measures may be more sensitive to detect overall growth of an aortic segment, information about localized change at a specific point along the aortic wall is not captured. Considering that surgical management recommendations are based on thresholds of size and growth rate, a diameter-based measurement technique may lead to treatment recommendations that are either overly aggressive or conservative on the basis of the measurement error alone. In addition, such size criteria used for surgical decision-making are based on historical measurement data and its inaccuracies, further emphasizing the significant ongoing need for accurate and reproducible aortic measurements.

A potential solution to these challenges exists in the field of diffeomorphic image registrations, particularly the application of spatial Jacobian matrices to quantify the deformation of the aortic wall by extracting nonrigid image transformations to match high-resolution thoracic electrocardiogram (ECG)-gated computed tomography angiography (CTA) images acquired at different time points, a technique that we term vascular defor-

mation mapping (VDM). Spatial Jacobian matrices in this context describe the relative local distortion at each point in the image resulting from the automated image-based registration. Although nonrigid image warping coregistration techniques have been broadly used in diseases of the lungs and brain, to the best of our knowledge, no prior studies have quantified spatial Jacobian maps to assess interval aortic enlargement (25–27). Image intensity-based registration techniques have been reported to have submillimeter precision in many applications, which also translate to accuracy in the calculation of the resulting spatial Jacobian with well-optimized workflows (28). Quantitative assessment of registration accuracy is not straightforward, with many potential sources of error and a large number of degrees of freedom; however, the use of cost function penalties such as bending energy helps to constrain and smooth spatial Jacobian results while also maximizing anatomical feature alignment. Jacobian maps may be directly calculated from the optimized nonrigid transform, and it could offer information about the local deformation of the aortic wall, including in the circumferential and longitudinal directions, information that is not currently assessed by other techniques.

A significant need exists for a more sensitive and accurate method of measuring change in thoracic aortic dimensions, considering that accurate detection of small-magnitude changes has important implications for improving understanding of aortic aneurysm progression and better informing treatment decisions. The aim of this study was to demonstrate the feasibility of using the proposed VDM technique to measure interval change in aortic wall dimensions on routine clinical CTA studies of patients with TAA and dissection. In addition, we aim to compare the results of the VDM analysis with routine clinical CTA assessments in seeking to better understand the potential benefits and limitations of this novel technique.

METHODS AND MATERIALS

Study Population

All procedures were approved by the local institutional review board with a waiver of informed consent obtained for this retrospective study and were Health Insurance Portability and Accountability Act-compliant. Patients were identified through a review of local picture archiving and communication system archives to identify adult (>18 years) patients with dilation of the thoracic aorta undergoing imaging surveillance, with at least 2 prior ECG-gated CTA examinations available for review. Patients were excluded if thoracic aortic enhancement was suboptimal (<250 Hounsfield unit [HU]) or there was significant motion/respiratory artifact affecting the clinical evaluation of thoracic aortic segments. After reviewing 15 patients, several were excluded owing to obvious pulsation artifact affecting the diseased aortic segment on CTA images ($n = 5$) or low-resolution baseline CTA studies (section thickness > 1.5 mm) that were acquired at outside hospitals and uploaded to our picture archiving and communication system ($n = 4$). One patient with type B aortic dissection was excluded from analysis owing to difficulties with accurate segmentation of the false lumen due to poor enhancement related to slow flow and partial thrombosis. The aortic pathologies of those patients selected for analysis included ascending thoracic aortic

dilation ($n = 1$), descending TAA ($n = 1$), and thoracic aortic dissection ($n = 3$).

Computed Tomography Angiography

CTA examinations were performed on 64-detector computed tomography (CT) scanners using helical acquisition mode (LightSpeed VCT or Discovery CT750HD, GE Healthcare, Waukesha, WI). Images were acquired through the entire thoracic aorta (lung apices to 2 cm below the celiac artery) during intravenous injection of 95-mL iopamidol 370 mg I/mL (Isovue 370, Bracco Diagnostics, Inc., Princeton, NJ) at 4 mL/s, followed by a 100-mL saline chaser at 4 mL/s. Retrospective ECG-gating was used, with axial reconstructions at 0.625-mm section thickness at 75% of the R-R cycle with ECG-modulated tube current technique (20% of maximum milliampere) and 40% adaptive statistical iterative reconstruction for dose efficiency. Other scan parameters included the following: detector coverage, 40 mm; Display Field of View, 25 cm; gantry rotation time, 0.4 seconds; maximum tube current, 400–700 milliampere as determined by patient size; and tube voltage, 100–120 kVp.

Image Segmentation

Segmentation of the aortic blood volume was accomplished with a user-defined threshold in contiguous regions followed by manual adjustments, all performed using custom in-house algorithms developed in Matlab (The MathWorks, Inc, Natick, MA). In brief, a threshold was chosen on a case-by-case basis to separate contrast-enhanced blood from the surrounding tissues and organs. Manual separation was required at the aortic valve and arch vessel levels. The surface structure was determined on the basis of the segmentation mask and then subject to curvature flow smoothing.

Image Registration

Image registration was performed between sequential CTA studies using a custom Matlab interface to the Elastix open source software (Utrecht, Netherlands). Images were processed temporarily for registration with the following after manually cropping around the region of the aorta:

- (1) A 3D Wiener filter ($3 \times 3 \times 3$) was applied to limit the effects of noise.
- (2) Image values <0 HU were set to 0 HU to avoid including the lungs.
- (3) The aortic blood segmentation mask was dilated by 6 mm to include the aortic wall.

Automated image registration included an affine optimization followed by a multiresolution nonrigid b-spline warping optimization using mutual information (subsampling within the dilated segmentation mask) with bending energy penalty (set to 50). Three resolutions of b-spline grid spacing were used in the descending order, as follows: 12, 6, and 3 mm. Total time for image registration was ~ 10 min on a standard high-end personal computer.

Vascular Deformation Mapping

Using the deformation fields generated from the final optimized nonrigid transformation, the spatial Jacobian tensor can be defined as all first-order derivatives at each voxel location:

$$J = I \begin{bmatrix} \frac{\delta \Delta x}{\delta x} & \frac{\delta \Delta x}{\delta y} & \frac{\delta \Delta x}{\delta z} \\ \frac{\delta \Delta y}{\delta x} & \frac{\delta \Delta y}{\delta y} & \frac{\delta \Delta y}{\delta z} \\ \frac{\delta \Delta z}{\delta x} & \frac{\delta \Delta z}{\delta y} & \frac{\delta \Delta z}{\delta z} \end{bmatrix}. \quad (1)$$

The determinant of the 3D spatial Jacobian, $|J|$, or simply referred to as the Jacobian map, was calculated from the final optimized image transform and normalized by the time difference between imaging sessions ($|J|/\text{years}$) to indicate a deformation rate. Values of $|J|$, henceforth referred to as VDM values, were linearly interpolated to the vertex points of the aortic segmentation surface for display. Image expansion is visualized by greater values (red, $|J| > 1$), compression by $|J| < 1$ (blue), and no general deformation by $|J| = 1$ (green). Areas of expansion or compression were considered artificial if one of the following criteria was present:

- (1) visible motion artifact was present on source CTA images;
- (2) visible error was noted in image alignment after the image warping coregistration step; or
- (3) regions of expansion/compression were adjacent to the cut-planes of the 3D aortic segmentation (eg, at the level of the aortic valve or proximal arch vessels), as these areas are susceptible to minor differences in geometry resulting from manual segmentation.

A simplified workflow of the VDM technique is displayed in Figure 1.

RESULTS AND DISCUSSION

Evaluation of Aortic Aneurysm

The VDM analysis clearly depicted interval enlargement of the descending aortic dimensions in our first representative case of a 76-year-old female patient with a prior history of surgical repair of an ascending aortic aneurysm. The aortic arch and descending aorta were not included in the initial surgical repair given the mild degree of preoperative dilation; however, the distal arch and descending aorta were noted to progressively enlarge over 3 subsequent CTA examinations spanning a period of 3.8 years (Figure 2). It is interesting to note that although the VDM shows enlargement of the proximal descending aorta at each interval, the extent and rate of enlargement progress from the first interval to the last, consistent with the gradually accelerating and outwardly expanding nature of aortic enlargement described with aortic aneurysm (6). In addition, although the clinical radiologist's assessment using maximal aortic diameters identified enlargement at each interval, the growth rate appeared to be decelerating by diameter measurements, and the growth was reported to be limited to the distal arch, whereas the VDM clearly highlighted more extensive enlargement along the length of the aorta, involving the proximal and mid-descending aorta at the second and third intervals. In an attempt to quantify and validate the VDM results, aortic area measurements were performed at a single level in the distal descending aorta with close attention paid to placing the measurement plane at precisely the same level and orientation in each study (Figure 2). The luminal area measurements revealed a small

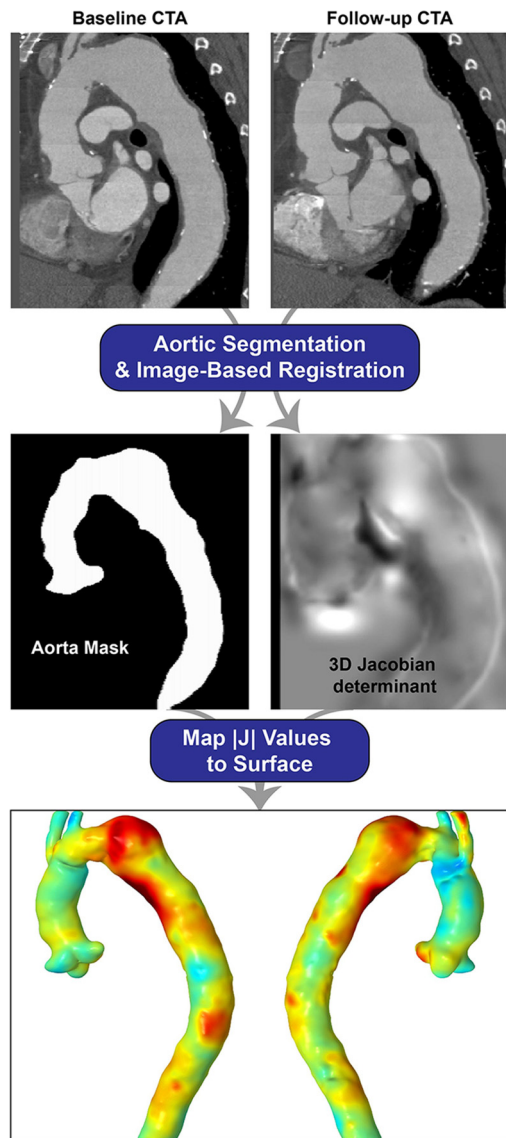


Figure 1. Vascular deformation mapping (VDM) workflow: computed tomography angiography (CTA) images undergo digital image processing and analysis that involves segmentation of the contrast-enhancing aortic blood volume followed by nonrigid coregistration between baseline and follow-up sessions. 3D maps of the determinant of the spatial Jacobian are then generated using the final optimized transform. These values are subsequently mapped to the 3D surface of the aortic segmentation, essentially allowing for visualization of the aortic wall deformation rate between imaging sessions. Expansion can be visualized as red (VDM > 1), compression as blue (VDM < 1), and no deformation as green (VDM = 0).

increase in area at the first interval (3.7 mm²), a larger increase in luminal area at the second interval (22.1 mm²), and the greatest increase in luminal area at the third interval (100.2 mm²) consistent with the accelerating growth visualized on the VDM map. For reference, an overall luminal increase of 100 mm² is equal to a ~1.1 mm increase in the diameter assuming that the lumen is circular.

In contrast to the above case, the VDM analysis was performed on a 66-year-old female patient undergoing imaging surveillance of a mildly dilated ascending aorta (maximally 4.1 cm at baseline), which revealed little deformation (Figure 3). This case was selected for analysis to serve as a negative control, as no enlargement was detected by clinical diameter assessment, and enlargement of the ascending aorta is both significantly slower and less common than enlargement of the descending aorta, particularly when the degree of dilation is mild (15). VDM did not reveal any areas of rapid growth in the ascending or descending aorta, and the majority of the 3D surface area of the thoracic aorta showed |J| values close to 1 (green), compatible with stable aortic dimensions. However, several small regions of moderate deformation were detected, one at the level of the sinotubular junction, another in the proximal arch in the region of the origin of the innominate artery, and the last at the mid-descending level. No motion artifact or image registration error was visually apparent, and, although the significance of these findings remains unclear, it is possible that they represent areas of slow growth that are beneath the threshold of detection by diameter measurements.

Evaluation of Aortic Dissection

Aortic dissection and aortic aneurysm are unique in their pathophysiology; however, the ultimate consequence of both pathologies is the same—dilation of the aortic wall due to weakened structural integrity. In both aneurysm and dissection, clinical surveillance guidelines and surgical decision-making are based on observation of the absolute aortic dimensions and the rate of aortic enlargement. As such, the VDM technique can be used to monitor progression (ie, enlargement) of patients with aortic dissection. In the first representative case, we present the results of a 56-year-old patient with a prior history of surgically repaired dissection of the ascending aorta, with a residual dissection flap involving the native aortic arch and descending aorta (Figure 4). VDM showed values close to 1 (green) throughout the majority of the aorta, compatible with stable dimensions of the true and false lumen during the 2-year time interval, in agreement with the clinical diameter assessment. There were several small areas of apparent mild enlargement in the ascending aorta and the distal descending aorta, which are thought to be due to imprecisions in coregistration caused by slight differences in cardiac and respiratory phases between studies, resulting in minor differences in aortic angulation (ie, “bending”), although no definite misregistration was visually apparent.

In contrast, Figure 5 illustrates a 52-year-old man with a history of type B aortic dissection who had 2 ECG-gated CTA studies available for analysis, the first ~1 year after the onset of his dissection and a follow-up study performed 6 months after the first. On the basis of the clinical report, there was suspicion for ~1–2 mm of interval enlargement of the distal aortic arch,

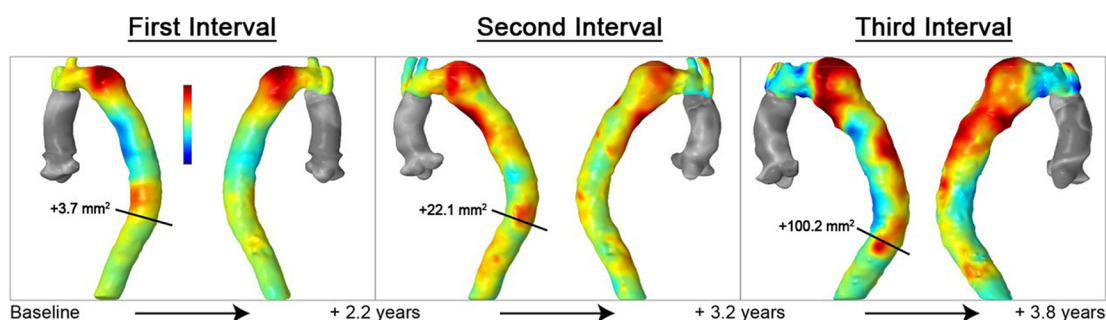


Figure 2. Progressive enlargement of an aortic aneurysm of the descending aorta in a 76-year-old patient with history of prior surgical repair of the ascending aorta. Aortic enlargement is noted at all intervals, but increases in rate and extent over time. Aortic lumen area (in square millimeter) measured at a single level (black line) in the distal descending aorta was used to corroborate a focal region of enlargement in the distal descending aorta seen on the VDM map. VDM values for replaced ascending aorta are not displayed owing to artifact.

but the conclusion of the clinical assessment was that there had been no definite enlargement, as the observed change in diameter was within the range of measurement error. VDM of this patient showed nearly diffuse enlargement of the false lumen throughout the distal aortic arch and descending aorta, with a corresponding decrease in size of the true lumen, changes that are frequently observed in chronic aortic dissection (29). It is important to note that although the absolute change in maximal aortic dimension was thought to be small (1–2 mm), the rate of growth is noted to be significant owing to the short interval (6 months) between the 2 studies. This ability to detect growth

over short intervals is particularly useful in the setting of patients with recent aortic dissection, as there is a proven clinical benefit to endovascular (TEVAR) repair in the subacute period (2 weeks to 3 months after dissection) (30). Of note, there was a visually apparent motion artifact in the ascending aorta on CTA images, leading to difficulty with image coregistration, which is manifested on the VDM as a wavy aortic wall contour and areas of high and low Jacobian determinant (red and blue, respectively) on adjacent areas of the aortic wall.

Finally, Figure 6 illustrates a 76-year-old man with a history of ascending aorta replacement, who developed a type B aortic dissection on the baseline study and had 4 surveillance

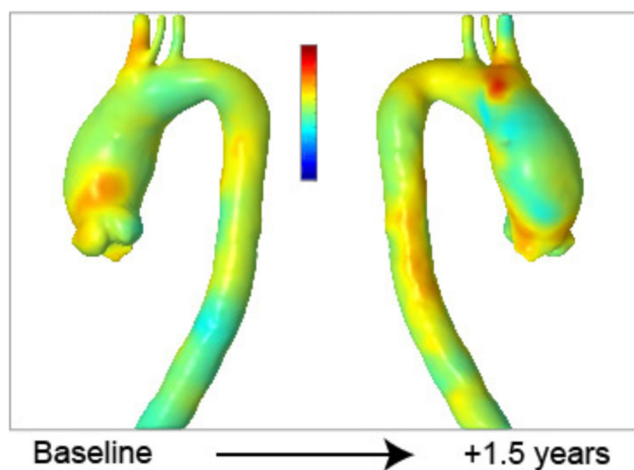


Figure 3. VDM analysis shows no areas of high-intensity wall expansion in a 66-year-old woman with a mild dilated ascending aorta (4.1 cm maximally). Although aortic dimensions were stable by clinical diameter assessment, low-intensity areas of potential aortic enlargement were noted at the sinotubular junction and in the region of the innominate artery, suggesting the possibility of limited growth in these regions.

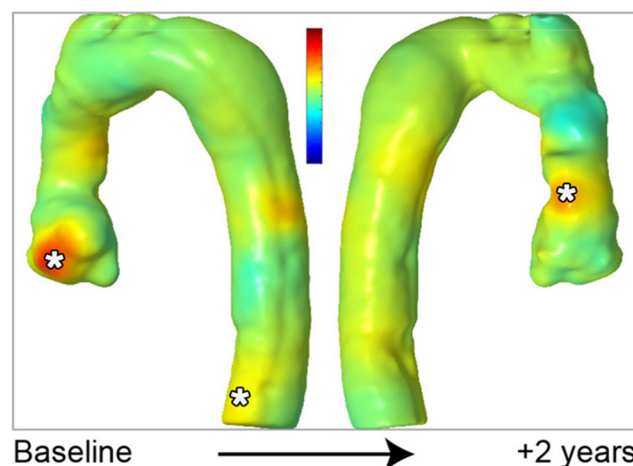


Figure 4. Overall stable aortic dimensions in a 56-year-old man with a history of surgical repair of the ascending aorta for type A dissection with residual dissection flap in the aortic arch and descending aorta. Small areas of apparent aortic expansion at the aortic root and distal descending aorta are likely because of mild coregistration artifact (*).

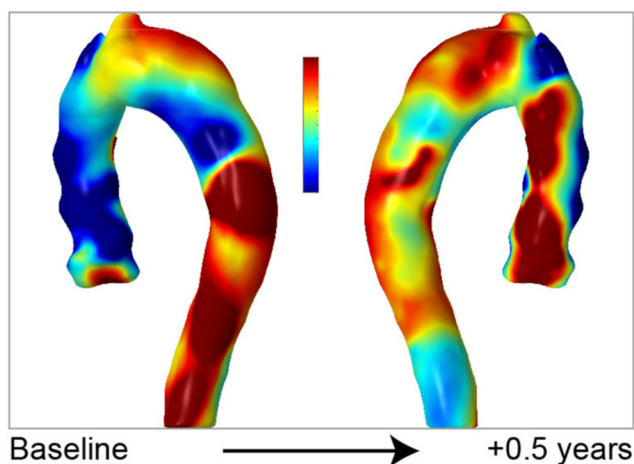


Figure 5. VDM analysis of a 52-year-old man with a history of type B dissection shows interval expansion of the false lumen (red) with interval compression of the true lumen (blue) over a short interval of 6 months. Clinical diameter measurements suggested 1–2 mm increase in maximal dimensions, but no definite enlargement was described because the diameter change was within the range of measurement error. Cardiac motion artifact in the ascending aorta results in a wavy aortic wall contour and areas of high- and low-VDM values on opposite sides of the aortic wall.

CTAs performed over a 3-year period available for analysis. Comparing the clinical reports of the first and most recent CTA studies, the patient experienced up to 6 mm of enlargement overall at various points along the descending aorta during the 4-year follow-up period; however, using clinical diameter measurements interval enlargement was only confidently detected at the second interval. During the first interval, the VDM anal-

ysis revealed several areas of enlargement along the descending aorta, with the most intense areas in the proximal and distal descending aorta characterized by enlargement of the false lumen and compression of the true lumen. Despite the distal descending aorta being susceptible to image coregistration error related to respiratory variation, we did not visually detect any issues with image coregistration. On re-examination of the CTA studies, there was suggestion of 1–2 mm of aortic enlargement at these levels by diameter assessment. Furthermore, the entry tears that allow blood to flow from the true lumen into the false lumen were located at the proximal descending and distal descending levels, the locations of the most rapid growth, supporting the VDM results that enlargement had occurred in these regions. At the second interval, the VDM map again showed regions of false lumen enlargement; however, the rate of aortic enlargement decreased. Finally, during the third interval, the descending aorta that appeared showed only a small area of continued false lumen enlargement at the mid-descending level, and otherwise no interval change. This observed gradual deceleration of aortic growth over time has previously been described in patients with chronic aortic dissection (29). Although the mechanisms underlying the evolution of chronic type B dissection remain poorly understood, the wall of an acutely dissected aorta contains minimal fibrosis, and structural integrity of the wall is low. With increasing chronicity, the aortic wall undergoes a process of adaptive remodeling, mainly through increased collagen deposition, leading to increased wall rigidity and a decreased rate of enlargement (29). Unfortunately, such remodeling processes are insufficient for preventing aneurysm formation in some patients who remain at a risk for rupture. The ability to accurately measure the rate of aortic enlargement at each follow-up interval may better inform clinical management through improved depiction of the overall growth trend (ie, accelerating vs decelerating), and may contribute to a better understanding of the natural history of aneurysm formation among patients with chronic aortic dissection.

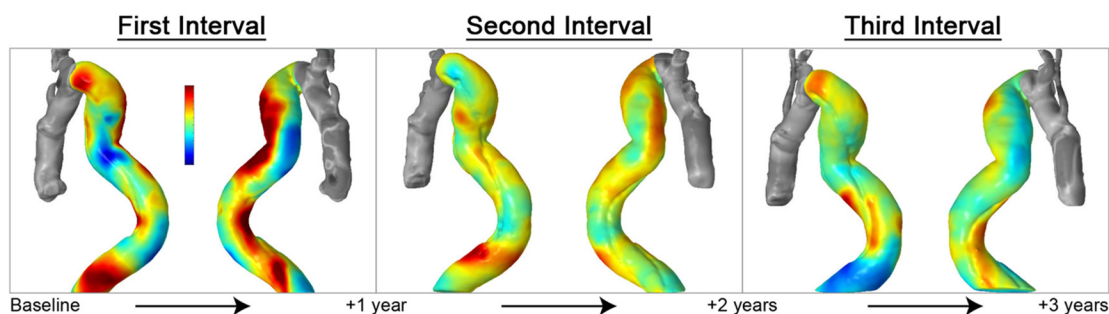


Figure 6. Progressively enlarging aortic dimensions in a 76-year-old man with a history of type B aortic dissection over 3 intervals with the rate of enlargement noted to progressively decrease during follow-up. The highest-intensity regions of enlargement were at the level of the proximal and distal descending aorta levels corresponding to the location of entry tears in the dissection flap. Clinical diameter assessment detected a 4-mm interval growth at the second interval in the distal arch, but no definite enlargement was noted at the first or third intervals. VDM values for replaced ascending aorta are not displayed because of artifact.

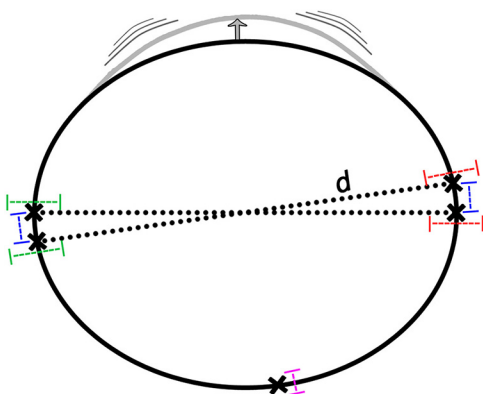


Figure 7. Diagram of sources of measurement variability with maximal diameter and VDM measurement techniques. Variability in diameter measurements arises from 3 potential user-specific inputs: placement of the near-wall caliper (green error bar), placement of the far-wall caliper (red error bar), and sight differences in radial position of diameter measurement in noncircular aortic segments (blue error bar). The nonrigid image registration techniques used in the VDM analysis are reported to have submillimeter precision (purple error bar), and coregister all points in 3D space along the circumference and length of the aorta, making detection of local regions of non-maximal growth possible (gray area of wall bulging).

Advantages and Clinical Opportunities

We believe that the early results presented here clearly demonstrate several unique advantages of the VDM technique over maximal diameter measurements for assessment of aortic enlargement in the setting of aneurysm and dissection. First, and most importantly, we believe that the application of the VDM technique can result in reduced measurement error, as it uses the full 3D image data along the entire length of the aorta, rather than diameters placed at fixed locations along the aortic length. Furthermore, our approach relies on modern semiautomated nonrigid image registration techniques that can align CTA images with a precision in the range of 0.5–1 mm (28). The reported 2–5 mm range of error associated with aortic diameter measurement on CT arises from several potential sources, including variability in placement of the measurement calipers along the near and far walls, as well as variability in the rotation of the diameter plane when the aorta is not uniformly circular as shown in Figure 7 (31). However, the VDM technique relies on modern nonrigid image coregistration techniques that are able to match each location along the 3D aortic wall surface with submillimeter accuracy.

Second, the VDM technique offers the distinct advantage of being able to map a continuous range of growth rates in a 3D fashion, both along the entire length of the aorta and around its circumference, whereas aortic diameter measurements are lim-

ited to a single radial position at a fixed anatomic location. In addition, wall deformation can be assigned vectors, allowing for measurement of directional deformation in addition to overall magnitude, a characteristic of aortic aneurysm growth that has not been previously quantified in situ. Separating the full Jacobian tensor into components of normal, circumferential tangent, and longitudinal tangent magnitudes may provide an even more nuanced understanding of changes in aortic wall geometry. Volumetric and cross-sectional area measurements, although reported to be more sensitive for aortic enlargement, rely on discrete predefined anatomic boundaries of the aorta (ie, start and stop points along the length of the aorta), and are therefore limited in determining the spatial location and gradation of aortic enlargement. The 3-dimensional nature of VDM lends itself to robust and easily interpretable data visualization modalities that are customizable and approachable for surgeons and other nonimager aortic specialists. Furthermore, physical models displaying VDM may now be easily and economically 3D-printed and provided to surgeons preoperatively to aid in surgical planning. Although surgical decision-making remains a complex and patient-specific task, mapping the distribution of growth along the entire thoracic aorta, particularly areas of growth at nonmaximal locations, allows for the possibility of tailoring the surgical repair technique to include areas of slow growth that may not otherwise be detected by diameter measurements, and it could potentially necessitate future reoperation.

Lastly, because of the spatially continuous and quantitative nature of the VDM and its reduced measurement error, increased sensitivity for detection of eccentric and small-magnitude aortic enlargement is possible. The rate of aortic enlargement, rather than absolute increase in maximal diameter, can be easily calculated and visualized. The rate of aortic enlargement is more closely related to the underlying structural and cellular mechanisms that drive aneurysm progression, and is likely a better indicator of risk among patients with aortic aneurysm. Unfortunately, the rate of enlargement often cannot be accurately calculated from aortic diameter measurements owing to significant measurement error, particularly when time intervals—the denominator in a rate measurement—are short. The decreased measurement error attainable with the VDM technique may allow confident determination of slow aortic enlargement over short time intervals (eg, 3–6 months), rather than the several-year time frame often required for diameter measurements. Earlier detection and more accurate quantification of aortic growth may allow for more targeted and aggressive treatment of aortic disease, may provide for better-informed decisions to undergo major aortic surgical or endovascular procedures, and may be useful in the research setting where aortic enlargement is an outcome of interest and follow-up periods are limited by cost or other logistical considerations. Furthermore, the frequency of surveillance imaging can be better tailored to an individual if the stability of their aorta can be more accurately assessed; patients with slow-growing or stable aneurysms can have imaging spaced to 2- to 3-year intervals, allowing for more efficient health-care utilization, whereas patients with rapid enlargement can undergo imaging more frequently in the hopes

of minimizing the incidence of potentially predictable and preventable complications.

Technical Challenges

The results presented here constitute the first steps in the application of a VDM technique for the evaluation of aortic disease, and while preliminary results show great promise, several challenges remain. First, because this analysis has a high degree of sensitivity to aortic wall deformation, errors can be introduced by factors resulting in differing spatial alignment of the 2 compared aortic geometries. The 2 areas most susceptible to such error are at the aortic root (sinuses of Valsalva) and at the distal descending aorta at the level of the diaphragm, with the 2 main contributing factors being cardiac and respiratory motion. The effects of these factors on variation in aortic geometry have been previously described (32). The aortic root has the highest degree of pulsatory motion of any thoracic aortic segment owing to its close proximity to the heart, with the degree of pulsation amplified during expiration. In addition, the entire thoracic aorta has a relatively uniform lateral and posterior displacement with expiration. However, although uniform displacement could be easily corrected for during image coregistration, the distal descending aorta remains relatively fixed in position by the diaphragm, and this nonuniform motion introduces potential misalignment during image coregistration.

These observations stress the importance of acquiring the CTA images during the same phase of respiration (preferably inspiration) and with ECG-gating (preferably in late diastole) to minimize errors attributable to the small phasic variations in aortic geometry. In addition to respiratory and pulsation artifacts, “stair-step” artifact is occasionally encountered in ECG-gated CTAs, particularly when studies are performed on scanners with detector rows numbering 64 or less. The stair-step artifact is problematic for the VDM technique, as it creates an abrupt shelf-like defect in the 3D aortic segmentation that limits image coregistration. Fortunately, modern CT scanners that have been optimized for cardiovascular imaging can greatly minimize the frequency and severity of stair-step artifacts owing to the increased number of detector rows and decreased gantry rotation time.

Second, the VDM method has significant technical demands, both in terms of user expertise and computing requirements. Many software platforms are currently available to perform accurate semiautomated aortic segmentation, which, if combined with our technique, may significantly decrease the time required for analysis. In addition, although the required computing power makes the VDM technique less practical for smaller centers that lack dedicated high-performance computing capabilities, the recent rise of cloud-based medical image analysis software may allow for analysis to be centralized, lessening technical demands at the level of the end user. Development of this VDM technique is still in the early stages of development; however, routine clinical applicability of this approach will require streamlining of the analysis with improved semiautomated image segmentation techniques and code optimization to minimize technical demands and user input.

Future Technical Directions

Future technical efforts will be focused on the following 5 key topics:

- (1) Further validating the accuracy and consistency of the VDM analysis is an important next step, as there is no clear noninvasive—or even invasive—tool to measure changes in aortic dimension in situ. As such, VDM results will need to be compared with other more sensitive measurements of aortic enlargement such as CTA luminal area and volumetric assessments. In addition, phantoms with precisely controlled dimensions could be used to further validate VDM results in a controlled experimental setting.
- (2) Further developments in computer algorithms will be needed to further automate and improve image segmentation, coregistration, and analysis steps. In particular, additional efforts need to be focused on accurate and reproducible false lumen segmentation in patients with aortic dissection, as the false lumen is prone to heterogeneous enhancement related to either partial thrombosis and/or slow blood flow.
- (3) Development of a user-friendly console for easy visualization and interaction with the VDM results will be an important step in moving this technology into the realm of clinical practice.
- (4) Evaluating the feasibility of quantifying changes in the aortic dimensions between different points in the cardiac cycle, rather than between different studies acquired at the same point in the cardiac cycle. The aortic dimensions have been shown to change significantly with pulsation, and measurement of these changes using VDM could provide important insights into the elasticity/rigidity of the aortic wall, a characteristic that has been associated with a large variety of cardiovascular diseases (33).
- (5) Investigating the feasibility of the VDM technique to quantify enlargement of other pathologies that manifest as progressive vascular enlargement such as AAA, cerebral aneurysm, pulmonary artery enlargement related to pulmonary hypertension, and endoleak after endovascular aortic repair.

Future Clinical Directions

In addition to ongoing technical developments, this technology has several unique potential clinical and research applications that we plan to investigate. First, given the rapidly increasing availability and decreasing costs of color 3D printing, we plan to study the clinical utility of superimposing VDM results on full-scale, color 3D-printed aortic models. To demonstrate feasibility of this approach, we submitted the VDM results from Figure 2 (Interval 2) for color 3D printing with the results shown in Figure 8. To the best of our knowledge, there are no prior published reports of superimposing imaging-based measurements of pathophysiology, such as the VDM results of aneurysm enlargement, on 3D-printed anatomic models. A large proportion of the literature in the field of 3D printing has focused on the production of high-fidelity anatomic models from medical imaging data, with some proposed applications including rapid prototyping for medical device development, creation of individualized medical implants/prostheses, and operative planning and pa-

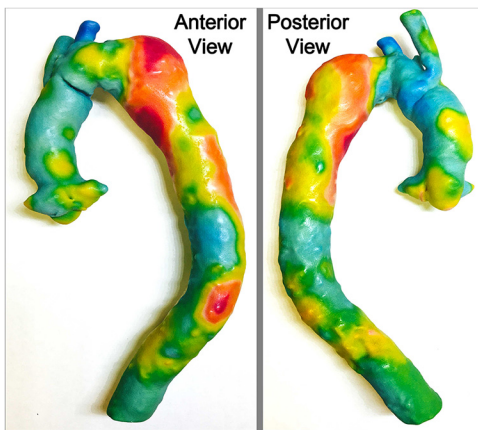


Figure 8. Color 3D-printed model of the thoracic aorta produced from the VDM results of a patient with progressively enlarging descending aortic aneurysm presented in Figure 2, interval 2. The superimposition of pathophysiologic VDM data on a 3D-anatomic model represents a novel application of medical 3D printing and be valuable in operative planning.

tient-specific device sizing in the setting of complex anatomy (34, 35). However, despite such promising applications, the role of 3D printing in clinical practice remains a topic of debate, largely owing to questions of cost versus benefit if similar observations and measurements can be made by 3D medical imaging software. As demonstrated here, the addition of VDM results superimposed on the 3D model surface significantly increases the amount of information that the model contains and may further justify the effort involved in creating patient-specific 3D models. Although a computerized VDM provides a detailed overview of the aneurysm enlargement, a 3D model that can be handled and closely studied by surgeons may allow for subtle anatomic and functional observations that are not as easily appreciated on a digital image, and could facilitate patient education during clinic visits.

Second, the VDM technique may be extremely valuable as a research tool for studies of aneurysm pathophysiology owing to its high degree of sensitivity to changes in aortic dimensions. There has been increased interest in elucidating the cellular pathways involved in remodeling of the vascular wall leading to the formation of aortic aneurysm (36, 37). Various cellular signaling pathways along with host-immune interactions have been implicated in the pathogenesis of AAAs (38–41). These factors are in part related to the complex underlying cellular processes responsible for the loss of extracellular matrix and wall remodeling. For example, chronic inflammation of the aorta wall has been implicated in the activation of matrix metalloproteinases (MMPs) such as MMP-2 and MMP-9, which have been reported to play a role in aortic wall weakening and subsequent AAA formation (42, 43). Furthermore, transforming growth factor β signaling alterations (44) have been widely associated with vascular smooth muscle disease with the genetic

basis now identified to involve 3 distinct pathomechanisms that include perturbation of the transforming growth factor β signaling pathway, disruption of the vascular smooth muscle cell contractile apparatus, and impairment of extracellular matrix synthesis (36, 37, 45). Advances in our understanding of the underlying pathogenetic alterations involved in the pathogenesis of thoracic aortic disease are providing significant new opportunities for therapeutic interventions using novel pharmaceutical approaches. The development of a validated imaging biomarker would allow for longitudinal quantification of the effects of drug interventions on modulation of disease progression. This capability would provide unique opportunities to use this imaging biomarker to facilitate development of therapeutic strategies in both preclinical aneurysm models and for use in clinical translational trials undertaking novel therapeutic strategies.

Finally, the potential impact of VDM results on clinical patient care will need to be thoroughly studied. Primary topics of investigation will include investigation of the associations between VDM measures and patient cardiovascular risk factors, the potential of VDM assessment to reclassify patient risk assessments, and the ability of VDM to predict patient outcomes. Although the VDM technique may indeed be more sensitive in detecting change in the aortic dimensions, an analysis of how data from this novel method could change patient management will be needed to show value over the more easily obtained aortic diameter measurements. Considering that the VDM analysis can be performed respectively on routine clinical CTA scans, the VDM results can be compared with clinical reports and a wide variety of patient demographic parameters and outcomes such as surgical repair strategy, surgical complication rate, reoperation rates, and occurrence of aorta-specific adverse events during imaging surveillance. In addition, as the VDM technique allows for assessment of aortic enlargement at specific spatial locations along the aortic wall, growth can be colocalized with pathological features of the aortic wall that are believed to promote aneurysm development such as atherosclerotic plaque (both calcified and lipid-rich), mural thrombus, intimal hyperplasia, or wall thickness. Identifying direct correlations between localized aortic wall pathology and regional wall expansion by VDM analysis could greatly advance our understanding of the underlying pathophysiology that leads to aortic aneurysm, and offer new strategies to predict aortic events, risk-stratify patients, and monitor the effectiveness of pharmacological therapy.

CONCLUSION

We have demonstrated the feasibility of a spatial Jacobian-based technique to measure changes in the size of the aortic lumen between baseline and follow-up ECG-gated thoracic CTA examinations in patients with mild aortic dilatation, aortic aneurysm, and aortic dissection, and that this technique is capable of quantifying and visually displaying the degree of aortic enlargement in a 3-dimensional fashion. Furthermore, we have shown that there are clear discrepancies between the VDM results and clinical diameter assessments, with the VDM technique appearing more sensitive for detection of changes in aortic dimensions owing to reduced measurement error, al-

though formal quantification of the degree of error reduction and the potential clinical impacts of a more sensitive analysis of aortic dimension changes requires further investigation. The VDM technique for measurement of change in aortic wall di-

mensions holds the promise of considerably improving the accuracy of aortic imaging surveillance, informing clinical decision-making, furthering aortic research questions, and shedding light on the natural history of aortic disease.

ACKNOWLEDGMENTS

The authors would like to thank Drs. Himanshu Patel and Bo Yang for their guidance pertaining to the potential applications of vascular deformation mapping in the field of aortic surgery. This study received support from BDR: National Institutes of Health R35CA197701 and U01CA166104, and NSB: Radiologic Society of North America Research Fellow Grant (RF1502).

Disclosure: No disclosures to report.

Conflict of Interest: None reported.

REFERENCES

- Elefteriades JA. Thoracic aortic aneurysm: reading the enemy's playbook. *Curr Probl Cardiol.* 2008;33(5):203-277.
- Durham CA, Cambria RP, Wang LJ, Ergul EA, Aranson NJ, Patel VI, Conrad MF. The natural history of medically managed acute type B aortic dissection. *J Vasc Surg.* 2015;61(5):1192-1198.
- Morgan L, Choi H, Reid M, Khawaja A, Mazzone PJ. The frequency of incidental findings and subsequent evaluation in low-dose CT scans for lung cancer screening. *Ann Am Thorac Soc.* 2017;14(9):1450-1456.
- Hiratzka LF, Bakris GL, Beckman JA, Bersin RM, Carr VF, Casey DE Jr, Eagle KA, Hermann LK, Isselbacher EM, Kazerooni EA, Kouchoukos NT, Lytle BW, Milewicz DM, Reich DL, Sen S, Shinn JA, Svensson LG, Williams DM; American College of Cardiology Foundation/American Heart Association Task Force on Practice Guidelines; American Association for Thoracic Surgery; American College of Radiology; American Stroke Association; Society of Cardiovascular Anesthesiologists; Society for Cardiovascular Angiography and Interventions; Society of Interventional Radiology; Society of Thoracic Surgeons; Society for Vascular Medicine. 2010 ACCF/AHA/AATS/ACR/ASA/SCA/SCAI/SIR/STS/SVM guidelines for the diagnosis and management of patients with Thoracic Aortic Disease: a report of the American College of Cardiology Foundation/American Heart Association Task Force on Practice Guidelines, American Association for Thoracic Surgery, American College of Radiology, American Stroke Association, Society of Cardiovascular Anesthesiologists, Society for Cardiovascular Angiography and Interventions, Society of Interventional Radiology, Society of Thoracic Surgeons, and Society for Vascular Medicine. *Circulation.* 2010;121(13):e266-e369.
- Benedetti N, Hope MD. Prevalence and significance of incidentally noted dilation of the ascending aorta on routine chest computed tomography in older patients. *J Comput Assist Tomogr.* 2015;39(1):109-111.
- Chau KH, Elefteriades JA. Natural history of thoracic aortic aneurysms: size matters, plus moving beyond size. *Prog Cardiovasc Dis.* 2013;56(1):74-80.
- Kälsch H, Lehmann N, Möhlenkamp S, Becker A, Moebus S, Schmermund A, Stang A, Mahabadi AA, Mann K, Jöckel KH, Erbel R, Eggebrecht H. Body-surface adjusted aortic reference diameters for improved identification of patients with thoracic aortic aneurysms: results from the population-based Heinz Nixdorf Recall study. *Int J Cardiol.* 2013;163(1):72-78.
- State Health Facts Menlo Park (CA): The Kaiser Family Foundation. <http://www.kff.org/other/state-indicator/distribution-by-age/?> Updated March 2016. Accessed August 31, 2017.
- Johansson G, Markstrom U, Swedenborg J. Ruptured thoracic aortic aneurysms: a study of incidence and mortality rates. *J Vasc Surg.* 1995;21(6):985-988.
- Renapurkar RD, Setser RM, O'Donnell TP, Egger J, Lieber ML, Desai MY, Stillman AE, Schoenhagen P, Flamm SD. Aortic volume as an indicator of disease progression in patients with untreated infrarenal abdominal aneurysm. *Eur J Radiol.* 2012;81(2):E87-E93.
- Juvonen T, Ergin MA, Galla JD, Lansman SL, Nguyen KH, McCullough JN, Levy D, de Asla RA, Bodian CA, Griep RB. Prospective study of the natural history of thoracic aortic aneurysms. *Ann Thorac Surg.* 1997;63(6):1533-1545.
- Sueyoshi E, Sakamoto I, Hayashi K, Yamaguchi T, Imada T. Growth rate of aortic diameter in patients with type B aortic dissection during the chronic phase. *Circulation.* 2004;110(11 suppl 1):II256-261.
- Coady MA, Rizzo JA, Hammond GL, Kopf GS, Elefteriades JA. Surgical intervention criteria for thoracic aortic aneurysms: a study of growth rates and complications. *Ann Thorac Surg.* 1999;67(6):1922-1926.
- Cheung K, Boodhwani M, Chan KL, Beauchesne L, Dick A, Coutinho T. Thoracic aortic aneurysm growth: role of sex and aneurysm etiology. *J Am Heart Assoc.* 2017;6(2). pii: e003792.
- Gagné-Loranger M1, Dumont É1, Voisine P1, Mohammadi S1, Dagenais F. Natural history of 40-50 mm root/ascending aortic aneurysms in the current era of dedicated thoracic aortic clinics. *Eur J Cardiothorac Surg.* 2016;50(3):562-566.
- Hong H, Yang Y, Liu B, Cai W. Imaging of abdominal aortic aneurysm: the present and the future. *Curr Vasc Pharmacol.* 2010;8(6):808-819.
- Elefteriades JA, Farkas EA. Thoracic aortic aneurysm clinically pertinent controversies and uncertainties. *J Am Coll Cardiol.* 2010;55(9):841-857.
- Quint LE, Liu PS, Booher AM, Watcharotone K, Myles JD. Proximal thoracic aortic diameter measurements at CT: repeatability and reproducibility according to measurement method. *Int J Cardiovasc Imaging.* 2013;29(2):479-788.
- Lu TLC, Rizzo E, Marques-Vidal PM, von Segesser LK, Dehmshki J, Qanadli SD. Variability of ascending aorta diameter measurements as assessed with electrocardiography-gated multidetector computerized tomography and computer assisted diagnosis software. *Interact Cardiovasc Thorac Surg.* 2010;10(2):217-221.
- Trinh B, Dubin I, Rahman O, Botelho MPF, Naro N, Carr JC, Collins JD, Barker AJ. Aortic volumetry at contrast-enhanced magnetic resonance angiography feasibility as a sensitive method for monitoring bicuspid aortic valve aortopathy. *Invest Radiol.* 2017;52(4):216-222.
- Masri A, Kalahasti V, Svensson LG, Roselli EE, Johnston D, Hammer D, Schoenhagen P, Griffin BP, Desai MY. Aortic cross-sectional area/height ratio and outcomes in patients with a trileaflet aortic valve and a dilated aorta. *Circulation.* 2016;134(22):1724-1737.
- Davies RR, Gallo A, Coady MA, Tellides G, Botta DM, Burke B, Coe MP, Kopf GS, Elefteriades JA. Novel measurement of relative aortic size predicts rupture of thoracic aortic aneurysms. *Ann Thorac Surg.* 2006;81(1):169-177.
- Parr A, Jayaratne C, Buttner P, Golledge J. Comparison of volume and diameter measurement in assessing small abdominal aortic aneurysm expansion examined using computed tomographic angiography. *Eur J Radiol.* 2011;79(1):42-47.
- Stanley GA, Murphy EH, Knowles M, Ilves M, Jessen ME, Dimairo JM, Modrall JG, Arko FR 3rd. Volumetric analysis of type B aortic dissections treated with thoracic endovascular aortic repair. *J Vasc Surg.* 2011;54(4):985-992.
- Galbán CJ, Han MK, Boes JL, Chughtai KA, Meyer CR, Johnson TD, Galbán S, Rehemtulla A, Kazerooni EA, Martinez FJ, Ross BD. Computed tomography-based biomarker provides unique signature for diagnosis of COPD phenotypes and disease progression. *Nat Med.* 2012;18(11):1711-1715.
- Boes JL, Hoff BA, Hyllton N, Pickles MD, Turnbull LW, Schott AF, Rehemtulla A, Chamberlain R, Lemasson B, Chenevert TL, Galbán CJ, Meyer CR, Ross BD. Image registration for quantitative parametric response mapping of cancer treatment response. *Transl Oncol.* 2014;7(1):101-110.
- Keith L, Ross BD, Galbán CJ, Luker GD, Galbán S, Zhao B, Guo X, Chenevert TL, Hoff BA. Semiautomated workflow for clinically streamlined glioma parametric response mapping. *Tomography.* 2016;2(4):267-275.
- Klein S, Staring M, Pluim JP. Evaluation of optimization methods for nonrigid medical image registration using mutual information and B-splines. *IEEE Trans Image Process.* 2007;16(12):2879-2890.
- Peters S, Mansour AM, Ross JA, Vaitkeviciute I, Charilaou P, Dumfarth J, Fang H, Ziganshin BA, Rizzo JA, Adeniran AJ, Elefteriades JA. Changing pathology of the thoracic aorta from acute to chronic dissection literature review and insights. *J Am Coll Cardiol.* 2016;68(10):1054-1065.
- Fanelli F, Cannavale A, O'Sullivan GJ, Gazzetti M, Cirelli C, Lucatelli P, Santoni M, Catalano C. Endovascular repair of acute and chronic aortic type B dissections: main factors affecting aortic remodeling and clinical outcome. *JACC Cardiovasc Interv.* 2016;9(2):183-191.
- Kauffmann C, Tang A, Therasse E, Giroux MF, Elkouri S, Melanson P, Oliva VL, Soulez G. Measurements and detection of abdominal aortic aneurysm growth: Accuracy and reproducibility of a segmentation software. *Eur J Radiol.* 2012;81(8):1688-1694.
- Suh GY, Beygui RE, Fleischmann D, Cheng CP. Aortic arch vessel geometries and deformations in patients with thoracic aortic aneurysms and dissections. *J Vasc Interv Radiol.* 2014;25(12):1903-1911.

33. Sethi S, Rivera O, Oliveros R, Chilton R. Aortic stiffness: pathophysiology, clinical implications, and approach to treatment. *Integr Blood Press Control*. 2014;7: 29–34.
34. Foley TA, El Sabbagh A, Anavekar NS, Williamson EE, Matsumoto JM. 3D-printing: applications in cardiovascular imaging. *Curr Radiol Rep*. 2017;5(9):43.
35. Marro A, Bandukwala T, Mak W. Three-dimensional printing and medical imaging: a review of the methods and applications. *Curr Probl Diagn Radiol*. 2016; 45(1):2–9.
36. Andelfinger G, Loeys B, Dietz H. A Decade of Discovery in the Genetic Understanding of Thoracic Aortic Disease. *Can J Cardiol*. 2016;32(1):13–25.
37. Bowdin SC, Laberge AM, Verstraeten A, Loeys BL. Genetic testing in thoracic aortic disease—when, why, and how? *Can J Cardiol*. 2016;32(1):131–134.
38. Ghosh A, Lu G, Su G, McEvoy B, Sadiq O, DiMusto PD, Laser A, Futchko JS, Henke PK, Eliason JL, Upchurch GR Jr. Phosphorylation of AKT and abdominal aortic aneurysm formation. *Am J Pathol*. 2014;184(1):148–158.
39. Kim J, Procknow JD, Yanagisawa H, Wagenseil JE. Differences in genetic signaling, and not mechanical properties of the wall, are linked to ascending aortic aneurysms in fibulin-4 knockout mice. *Am J Physiol Heart Circ Physiol*. 2015; 309(1):H103–H113.
40. Meng X, Yang J, Dong M, Zhang K, Tu E, Gao Q, Chen W, Zhang C, Zhang Y. Regulatory T cells in cardiovascular diseases. *Nat Rev Cardiol*. 2016;13(3):167–179.
41. Miner GH, Faries PL, Costa KD, Hanss BG, Marin ML. An update on the etiology of abdominal aortic aneurysms: implications for future diagnostic testing. *Expert Rev Cardiovasc Ther*. 2015;13(10):1079–1090.
42. Rabkin SW. The Role Matrix metalloproteinases in the production of aortic aneurysm. *Prog Mol Biol Transl Sci*. 2017;147:239–265.
43. van der Pluijm I, van Vliet N, von der Thüsen JH, Robertus JL, Ridwan Y, van Heijningen PM, van Thiel BS5, Vermeij M2, Hoeks SE6, Buijs-Offerman RM7, Verhaagen HJ8, Kanaar R9, Bertoli-Avella AM7, Essers J. Defective connective tissue remodeling in Smad3 mice leads to accelerated aneurysmal growth through disturbed downstream TGF-beta signaling. *EBioMedicine*. 2016;12:280–294.
44. Forte A, Galderisi U, Cipollaro M, De Feo M, Della Corte A. Epigenetic regulation of TGF-beta1 signalling in dilative aortopathy of the thoracic ascending aorta. *Clin Sci (Lond)*. 2016;130(16):1389–1405.
45. Brownstein AJ, Ziganshin BA, Kuivaniemi H, Body SC, Bale AE, Elefteriades JA. Genes associated with thoracic aortic aneurysm and dissection: an update and clinical implications. *Aorta (Stamford)*. 2017;5(1):11–20.