Figure S1. Chest X-ray after admission to the NICU.
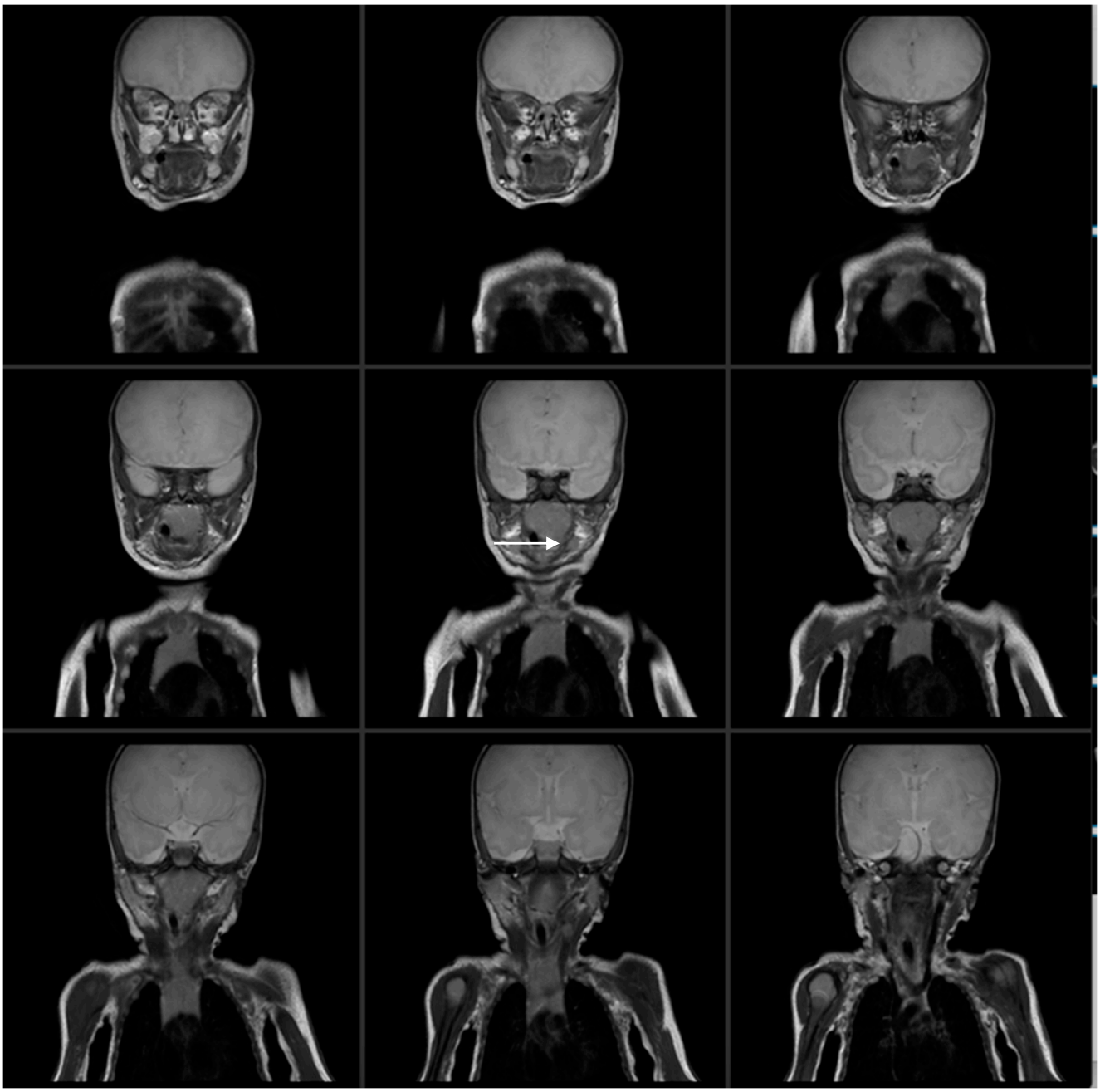
Figure S2. MRI scan of the neck, arrow pointing at the tumor.