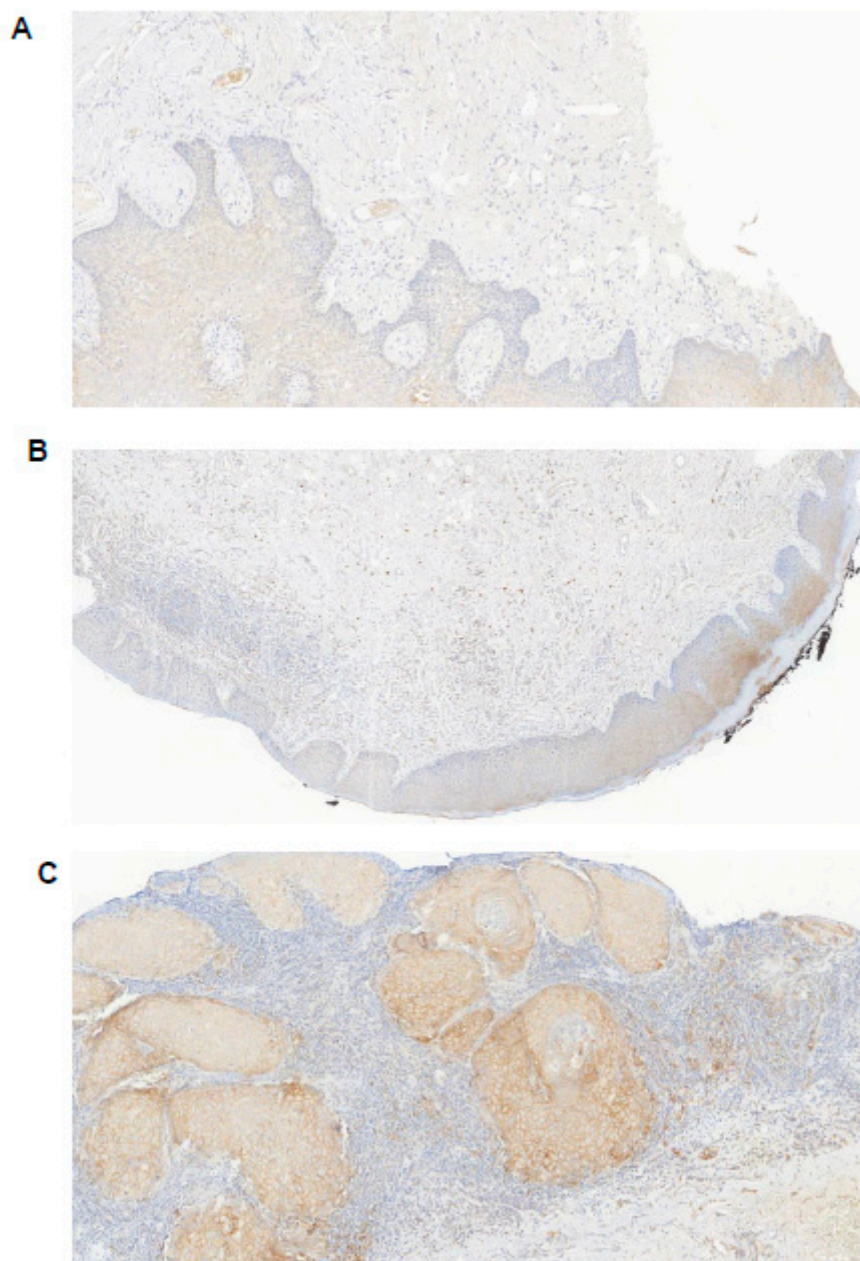


## Supplementary Material



**Figure S1.** Classification "none", "mild", "moderate" and "severe" inflamed samples according to infiltration density by inflammatory cells in the subepithelium of the affected tissue (sections stained applying antibody against PD-L1). (A) mild (B) moderate (C) severe. (magnification 10×).