


## Article

# GC-MS Analysis of the Phytochemical Constituents, Safety Assessment, Wound Healing and Anti-Inflammatory Activities of *Cucurbita pepo* Leaf Extract in Rats

Emmanuel Iroha Akubugwo <sup>1,†</sup>, Okezie Emmanuel <sup>1,†</sup> , Celestine Nwabu Ekweogu <sup>2,†</sup>,  
Ositadinma Chinyere Ugbogu <sup>3,†</sup>, Tochukwu Remigius Onuorah <sup>1,†</sup>, Ozioma Glory Egeduzu <sup>1,†</sup>  
and Eziuche Amadike Ugbogu <sup>1,\*</sup>

<sup>1</sup> Department of Biochemistry, Abia State University, Uturu PMB 2000, Abia State, Nigeria

<sup>2</sup> Department of Medical Biochemistry, Imo State University, Owerri PMB 2000, Imo State, Nigeria

<sup>3</sup> Department of Microbiology, Abia State University, Uturu PMB 2000, Abia State, Nigeria

\* Correspondence: amadike.ugbogu@abiastateuniversity.edu.ng; Tel.: +234-81-6755-0663

† These authors contributed equally to this work.



**Citation:** Akubugwo, E.I.; Emmanuel, O.; Ekweogu, C.N.; Ugbogu, O.C.; Onuorah, T.R.; Egeduzu, O.G.; Ugbogu, E.A. GC-MS Analysis of the Phytochemical Constituents, Safety Assessment, Wound Healing and Anti-Inflammatory Activities of *Cucurbita pepo* Leaf Extract in Rats. *Sci. Pharm.* **2022**, *90*, 64. <https://doi.org/10.3390/scipharm90040064>

Academic Editor: Helen D. Skaltsa

Received: 18 May 2022

Accepted: 22 June 2022

Published: 14 October 2022

**Publisher's Note:** MDPI stays neutral with regard to jurisdictional claims in published maps and institutional affiliations.



**Copyright:** © 2022 by the authors. Licensee MDPI, Basel, Switzerland. This article is an open access article distributed under the terms and conditions of the Creative Commons Attribution (CC BY) license (<https://creativecommons.org/licenses/by/4.0/>).

**Abstract:** In traditional medicine, *Cucurbita pepo* L. is used for the treatment of rheumatism, diabetes, inflammations, and wound injuries. This study was conducted to evaluate the phytochemical constituents, safety profile, wound healing, and anti-inflammatory activities of *Cucurbita pepo* leaf extract in rats. The phytochemical analysis of *C. pepo* extract was carried out using gas chromatography-mass spectrometry (GC-MS). In acute toxicity tests, the rats orally received a single dose of 5 g/kg extract of *C. pepo*. In a subacute toxicity study, the rats received 200, 400, and 800 mg/kg of the *C. pepo* extract via daily gavage for 14 days. Bioactive compounds 1-octen-3-ol, nonanal, trans- $\beta$ -ionone, phytol, trans-farnesol, and squalene were identified. There were no toxic effects detected in any of the evaluated parameters, namely liver, kidney, haematological, lipid, and antioxidant enzymes. In wound healing, *C. pepo* extract showed greater % wound contraction and tensile strength, as well as reduced wound healing time (12 days) and epithelialization when compared to the control (normal saline) and povidone-iodine treated groups. Rats treated with *C. pepo* extract elicit anti-inflammatory activity. The findings of this study revealed that the *C. pepo* extract has wound healing and anti-inflammatory properties with a wide margin of safety.

**Keywords:** *Cucurbita pepo*; bioactive compounds; safety assessment; wound healing; anti-inflammatory

## 1. Introduction

In recent times, the global use of medicinal plants or herbal medicines as either alternative or supportive medicine to conventional medicine has increased tremendously [1]. Today, medicinal plants and their bioactive components are widely accepted as an emerging source of alternative therapy for the management and treatment of various human diseases [2,3]. It is estimated that over 80% of the world population in one way or the other uses medicinal plants and their phytotherapeutic compounds as alternative primary healthcare due to their bioavailability, accessibility, efficacy, affordability, and low associated side effects [4,5]. They are not only used for healthcare remedies but can also serve as novel sources of unlimited raw materials for the discovery of new drugs. In ethnomedicine, many medicinal plants are effectively used for wound healing or wound management because they create a suitable moist environment, demonstrate the shortest healing time, and cause less pain or discomfort to the patients [1]. Wounds (acute, burns, or chronic wounds) are physical injuries that lead to the disruption of normal structures and functions of the tissues and skin [6]. They are traumatic and devastating types of injuries and therefore one of the leading global public concerns. Wound healing is a dynamic biochemical and cellular event involving the repair of damaged tissues and skins [7]. Bioactive components

in medicinal plants or herbal medicines have great potential to reduce oxidative stress and inflammatory processes [8], inhibit infections, and promote blood clotting, as well as accelerate wound healing processes by repairing tissues and regenerating damaged skins [9]. Many researchers have reported that medicinal plants are successfully used in the management and treatment of different types of wounds [6,10–12], and one such plant is *Cucurbita pepo*.

*Cucurbita pepo* L. is a green vegetable that is globally used as functional food and medicine. It belongs to Cucurbitaceae. It is a rich source of carotenoids, liposoluble vitamins, and polyunsaturated fatty acids [13]. It has high contents of flavonoids, terpenoids, alkaloids, proteins, lipids, carbohydrates, minerals [14], and  $\Delta 5$ -,  $\Delta 7$ -, and  $\Delta 8$ -phytosterols [15], which are likely responsible for its medicinal properties. The extract of different parts of *C. pepo* (leaves, seeds, flowers, and fruits) has shown to exhibit various pharmacological activities such as antioxidants, anti-inflammatory [16], anti-proliferative [17], anti-depressant, anti-ulcer, inhibition of lipid peroxidation [18], anti-diabetic [19], anti-bacterial, anti-viral, anti-hypercholesterolemic, and sedative-hypnotic effects [20]. In traditional medicine, the leaves are used as an analgesic or blood booster [21], to remove biliousness, and for treatments of rheumatism, benign prostatic hyperplasia, burns, and wound injuries [4,14]. Despite the acclaimed ethnopharmacological use of *C. pepo* in the treatment of many diseases, there are few or no scientific data from experimental studies as regards its toxicity profile, wound healing, and anti-inflammatory effects. This present study was conducted to evaluate the toxicity profile, wound healing, and anti-inflammatory properties of phytochemical characterized *C. pepo* leaf extract in rats.

## 2. Materials and Methods

### 2.1. Plant Collection and Authentication

Fresh leaves of *Cucurbita pepo* were obtained in June 2021 from Ugbogu's farmland in Amaku Nvosi, Isiala Ngwa South, a Local Government Area of Abia State, Nigeria, and authenticated by a taxonomist at the University of Nigeria Nsukka, Enugu State. The plant name *Cucurbita pepo* with voucher number UNH No 336 was deposited in the herbarium.

### 2.2. Extract Preparation

The fresh leaves of *C. pepo* were removed from the stem and the leaves thoroughly washed with distilled water. The extract was prepared by weighing 2 kg of the fresh *C. pepo* leaves in 2 L of water and squeezing for one (1) hour. The resulting juice was filtered using a sterile sieve and Whatmann No. 1 filter paper. The filtrate was freeze-dried and preserved in the refrigerator at 4 °C as *C. pepo* extract until time of use.

### 2.3. Gas Chromatography-Mass Spectrometric (GC-MS) Analysis

GC-MS analysis of *C. pepo* extract was performed using GC/MS-QP2010 ultra (Shimadzu Co., Kyoto, Japan) with an autosampler. A 5 MS/HP-column (30 m × 0.25 mm × 0.25 µm) with ultra-pure helium as the carrier gas was used. The helium flows at a flow rate of 1.12 mL/min and a linear velocity of 39 cm/s. The oven temperature was fixed at 110 °C to 280 °C at the rate of 10 °C/min. The injector temperature was set at 250 °C and injection volume as 0.5 µL were made in the split-less mode with a split ratio of 10:1. The MS transfer line and ion source temperatures were maintained at 250 °C and 200 °C, respectively, and the mass spectra detector volt was set at 0.94 kV. The full-scan mass spectra were recorded at 10,000 u/s over the mass range ( $m/z$ ) 85–500. Peaks and chemical constituents were identified by direct searching in the National Institute of Standards and Technology (NIST) library.

### 2.4. Animals

Healthy male unused albino rats (200–240 g), purchased from the Laboratory Animal Production Units of Veterinary Medicine College, Michael Okpara University of Agriculture, Umudike, Abia State, Nigeria, were used in the experiment. Prior to the experiments,

the rats were allowed to acclimatize for two weeks, maintained under normal standard laboratory conditions of 12 h light/12 h dark cycle at the temperature of  $25 \pm 3$  °C and relative humidity of 50%–70%. The rats were fed with standard commercial growers feed produced by Flour Mills of Nigeria and allowed free access to water. All the animal handling and experimental procedures were strictly adhered to throughout the study as specified by international standards and ethical principles established by Abia State University. This study was approved by Research Ethical Clearance Committee of Abia State University (ABSU/REC/BMR/0117).

#### 2.4.1. Acute Toxicity Study

The method established by The Organization for Economic Cooperation and Development (OECD) guideline 423 [22,23] with some modifications were adopted for this study. Seventy (70) matured male and female rats were randomly divided into 7 groups of 10 rats (5 males and 5 females (kept in different cages) in each group). Group 1 served as a normal control and received 10 mL/kg distilled water whereas Groups 2–7 received graded single dose of 500, 1000, 2000, 3000, 4000, and 5000 mg/kg of *C. pepo* extract, respectively, by oral gavage. The rats were allowed free access to water and feed and were monitored for signs of toxicity and death within and after a period of 24 h.

#### 2.4.2. Subacute Toxicity Study

The method established by OECD [22,24] guideline 407 and 425 with some modifications was adopted for this study. Twenty-four (24) albino rats were randomly divided into four (4) groups of six rats. Group 1 served as a normal control and received 0 mg/kg *C. pepo* extract, whereas groups 2, 3, and 4 received 200, 400, and 800 mg/kg of *C. pepo* extract, respectively, daily for 14 days.

#### 2.4.3. Blood Sample and Organ Collection

After two weeks (14 days) of extract treatment, the rats were starved of food but without restriction to water for about 12 hr and sacrificed on the 15th day by intraperitoneally administration of a combination of 50 mg/kg of ketamine and 5 mg/kg of xylazine. Then, the blood samples were collected via cardiac puncture with a needle and syringe. The blood samples for serum biochemistry and haematological analysis were dispensed into plain and ethylenediaminetetraacetic acid (EDTA) bottles, respectively. The vital organs, spleen, lungs, liver, kidneys, testes and heart, were harvested, and their respective weights recorded. The liver and kidney were fixed into 10% *v/v* formalin saline prior to histology evaluation.

#### 2.4.4. Blood Analysis

The complete haematological parameters were performed using an Automated Haematology Analyser (model BC-2800 Mindray Company, Hyderabad, Telangana, India). The haematological parameters evaluated include haemoglobin (Hb) concentration, packed cell volume (PCV), white blood cell (WBC) count, platelets and red blood cell (RBC) indices (mean corpuscular haemoglobin (MCH), mean corpuscular haemoglobin concentration (MCHC), and mean corpuscular volume (MCV).

#### 2.4.5. Clinical Biochemical Analysis

Renal function parameters (creatinine, urea, sodium, potassium, bicarbonate, and chloride), liver enzymes parameters (alanine aminotransferase, alkaline phosphatase aspartate aminotransferase, bilirubin, total protein, globulin, and albumin), and lipid profile parameters (total cholesterol, triacylglycerol, high-density lipoprotein cholesterol, low density lipoprotein cholesterol, and very low-density lipoprotein cholesterol) levels were evaluated spectrophotometrically using standard laboratory kits (Randox Laboratory Ltd., Co., Antrim, UK).

Oxidative stress markers were evaluated using the methods previously described by the following authors: superoxide dismutase [25], catalase [26], malondialdehyde [27], and glutathione [28].

#### 2.4.6. Histopathology

The histopathological studies were performed on the liver and kidney. The liver and kidney were fixed in 10% formalin and routinely processed and embedded in paraffin wax. Thereafter, the tissues were sectioned (5  $\mu$ m thickness), stained with haematoxylin and eosin (H and E) dyes, and then mounted and viewed under a light microscope at 400 $\times$  g magnification.

### 2.5. Wound Healing Experiments

Excision and incision wound models were used to evaluate the wound healing potential of aqueous extract of *C. pepo*.

#### 2.5.1. Excision Wound Models

Eighteen (18) healthy male rats (200–240 g) were divided into three (3) groups of six (6) rats each as follows. Group 1 was a negative control (treated with normal saline), while groups 2 and 3 were treated with 5% *w/w* povidone iodine (PI) and 10% *w/w* *C. pepo* extract, respectively, for 16 days. The rats were anaesthetized with 50 mg/kg of ketamine hydrochloride via intraperitoneal route [29,30]. The dorsal surface of the rats was shaved with a rechargeable clipper. After 30 min, an excisional wound of approximately 500 mm<sup>2</sup> and 2 mm depth was created on the shaved back of the rats. Treatment of the wounds started immediately after creation of the wounds by daily application of the ointments as described above. Day 0 was considered as wound day. Prior to epithelialization and complete wound closure, the wounds were observed daily, whereas the dimensions of the excision wounds were measured every 4 days with transparent paper and thereafter estimated on a 1 mm<sup>2</sup> graph sheet. Percentage wound contraction [6,31] was calculated using the formula:

$$\% \text{ Wound contraction} = \frac{\text{wound area on day 0} - \text{wound area on specific day(s)}}{\text{wound area on day 0}} \times 100 \quad (1)$$

where s = number of days (4th, 8th, 12th, 16th, and 20th day).

The period of epithelialization was calculated as described in [32,33].

#### 2.5.2. Wound Incision Model

Eighteen (18) healthy male rats (200–240 g) were divided into three (3) groups of six (6) rats each. The rats were anaesthetized with 50 mg/kg of ketamine hydrochloride via intraperitoneal route [29,30]. The dorsal surface of the rats was shaved with a rechargeable clipper. After 30 min, a sterile scalpel blade was used to make long paravertebral incision wounds of about 5 cm length and 1.5 cm from the middle of vertebral column on the shaved back [34]. Afterward, the incised wounds were closed by stitching 0.5 cm apart using sterile surgical thread and a curve needle no. 11 [35]. The rats were treated with normal saline, 5% *w/w* PI, and 10% *w/w* *C. pepo* extract for groups 1, 2, and 3, respectively, for 7 days. On the 8th day post wounding, the sutures were removed, and wound breaking strength was measured on the 10th day post-wounding.

#### 2.5.3. Wound Breaking Strength Measurement

The wound breaking strength was determined using Lee's constant water flow method [36]. The sedated rats were fastened on the laboratory bench on the 10th day after wounding, and a 3.5 mm line was drawn away from either side of the paravertebral long incision wounds, then two forceps were firmly applied to the line with both ends facing each other. The other forceps were attached to a freely suspended light weight graduated polypropylene container by a string flowing over to a pulley, and water was

permitted to flow slowly and steadily into the graduated polypropylene container from the reservoir, while one of the forceps was fixed. The tensile strength of the healed wound was assessed by gradually raising the water levels drop by drop until the wound broke or opened, then stopping the water flow and measuring and recording the weight of the water in the container.

The following formula was used to compute the tensile strength:

$$\text{Tensile strength} = \frac{\text{Breaking strength (g)}}{\text{Cross section area of skin (mm}^2\text{)}} \quad (2)$$

## 2.6. Anti-Inflammatory

In the anti-inflammatory experiment, the method described by Orieki et al. [37] was adopted for the study. Twenty-five (25) sets of male albino rats (200–240 g) were randomly divided into 5 groups of 5 rats each ( $n = 5/\text{group}$ ). Group 1 served as a normal control and was orally administered 0.2 mL/kg of normal saline. Group 2 received 100 mg/kg of aspirin, while groups 3, 4, and 5 orally received 200, 400, and 800 mg/kg of *C. pepo* extract, respectively. Thirty minutes (30 min) after oral treatments, paw edema was induced by sub-plantar injection of 0.1 mL egg albumin to each rat the right hind paw. After the induction, paw circumferences of the treated rats and control were measured and recorded at 0 min, 30 min, 60 min, and 120 min time intervals. The degree of edema was obtained by subtracting the initial paw circumference from the final paw circumference.

$$\% \text{ Rise in paw circumference (c) at induction} = \frac{\text{C at induction} - \text{C before induction}}{\text{C before induction}} \times 100 \quad (3)$$

$$\% \text{ Fall in paw circumference (c) at intervals} = \frac{\text{C at induction} - \text{C at interval}}{\text{C at induction}} \times 100 \quad (4)$$

$$\% \text{ Anti-inflammatory activity at 120 min} = \frac{\text{Mean fall in Test} - \text{Mean fall in control}}{\text{Mean fall in control}} \times 100 \quad (5)$$

## 2.7. Data Analysis

Calculations and statistics analysis were performed using Microsoft excel, R<sup>TM</sup> Statistic software, version 3.0.3 (<https://cran.r-project.org/src/base/R-3/>, accessed on 17 November 2021) and GraphPad Prism version 5.0 (San Diego, CA, USA). Results were expressed as mean  $\pm$  standard deviation. One-way analysis of variance (ANOVA) with a Tukey post hoc test was used to establish statistical significance at  $p$ -value of  $\leq 0.05$ .

## 3. Results

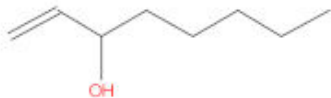

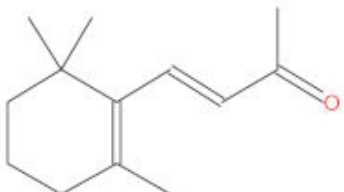


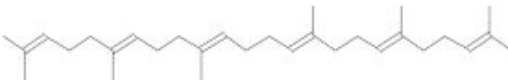
### 3.1. Identification of Chemical Compounds Present in Methanol Extract of *C. Pepo* by GC-MS

GC-MS analysis of methanol extract of *C. pepo* leaf (Table 1A) revealed the presence of fifteen (15) chemical compounds, namely 1-octen-3-ol, hexane, 4-ethyl-2-methyl-, nonanal, 1-cyclohexene-1-carboxaldehyde, 2,6,6-trimethyl-, 6,6-trimethyl-7-(3-oxobut-1-enyl)- 3,8-dioxatricyclo [5.1.0.0(2,4)]octan-5-one, cyclohexene, 2-ethenyl-1,3,3-trimethyl-, trans- $\beta$ -ionone, cyclohexane, 1,1'-(1,2-dimethyl-1, 2-ethanediyl)bis-, 2-pentadecanone, 6,10,14-trimethyl-, 4-tetradecene, (Z)-, 1-heneicosanol, phytol, trans-farnesol, 1,5,9-undecatriene, 2,6,10-trimethyl-, (Z)-, and squalene. Of the compounds identified, 1-heneicosanol (12.32) was the most abundant, whereas squalene (1.73) was the least abundant. In addition, out of 15 chemical compounds identified, only six (6) compounds are bioactive compounds with pharmacological activities. The six (6) bioactive compounds are 1-octen-3-ol, nonanal, trans- $\beta$ -ionone, phytol, trans-farnesol, and squalene (Table 1B). The chromatogram of the GC-MS spectral analysis of *C. pepo* reflecting the peaks of the distinct compounds, their elution, as well as their retention time are shown in Figure 1A,B.

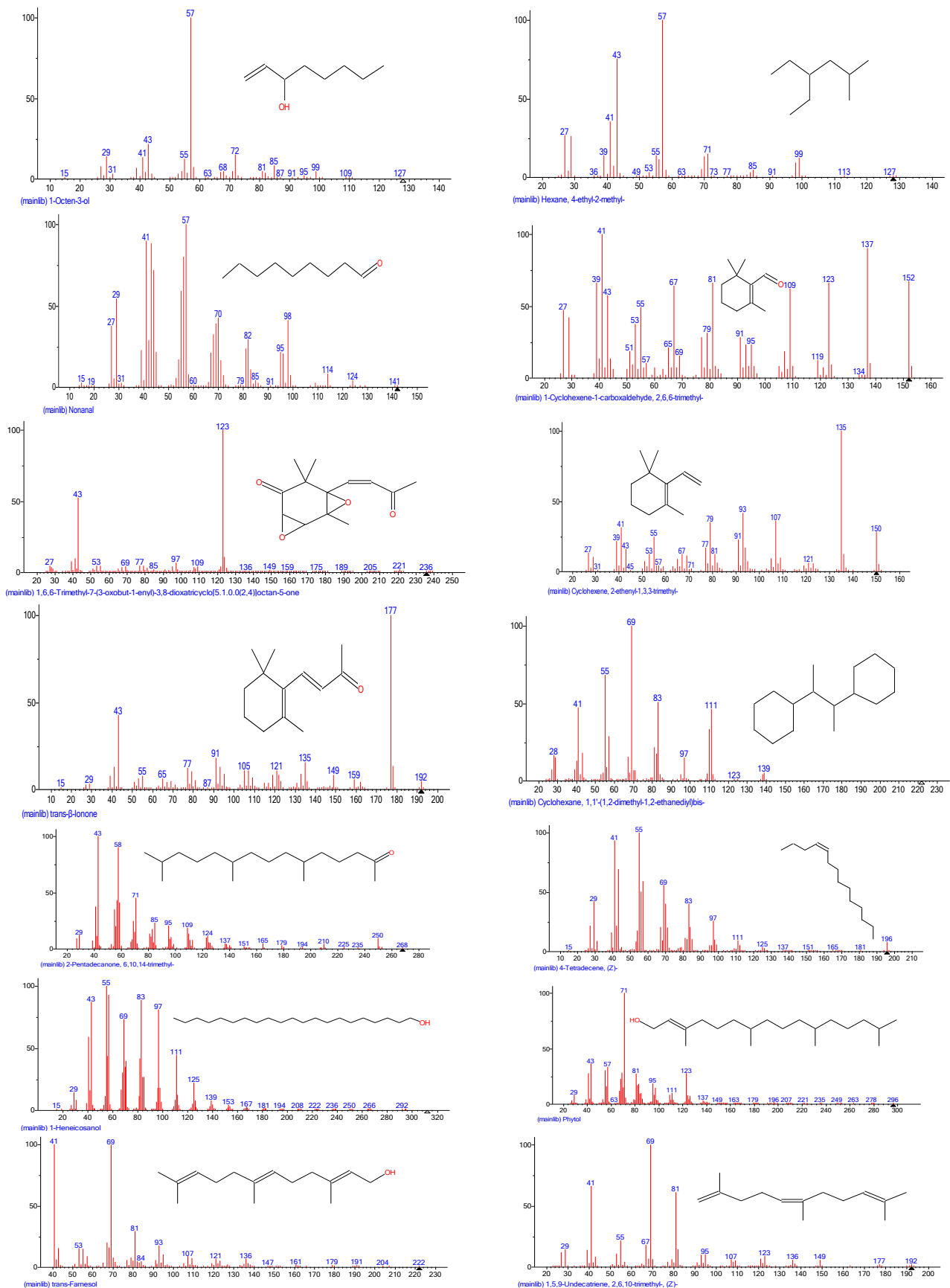
**Table 1.** A. Compounds identified from methanol extract of *C. pepo* leaf. B. Structural and pharmacological potentials of major bioactive compounds identified from methanol extract of *C. pepo*.

A			
Peak No.	Compound	Retention Time	Quantity (%)
1	1-Octen-3-ol	4.45	2.71
2	Hexane, 4-ethyl-2-methyl-	4.580	8.42
3	Nonanal	6.79	6.18
4	1-Cyclohexene-1-carboxaldehyde, 2,6,6-trimethyl-	9.10	2.32
5	1,6,6-Trimethyl-7-(3-oxobut-1-enyl)-3,8-dioxatricyclo[5.1.0.0(2,4)]octan-5-one	13.04	1.87
6	Cyclohexene, 2-ethenyl-1,3,3-trimethyl-	13.46	2.01
7	Trans- $\beta$ -Ionone	13.76	1.84
8	Cyclohexane, 1,1'-(1,2-dimethyl-1,2-ethanediyl)bis-	16.03	1.86
9	2-Pentadecanone, 6,10,14-trimethyl	20.20	2.24
10	4-Tetradecene, (Z)-	21.00	6.99
11	1-Heneicosanol	25.29	12.32
12	Phytol	25.80	3.09
13	Trans-Farnesol	27.39	3.96
14	1,5,9-Undecatriene, 2,6,10-trimethyl-, (Z)-	27.49	6.33
15	Squalene	27.53	1.73

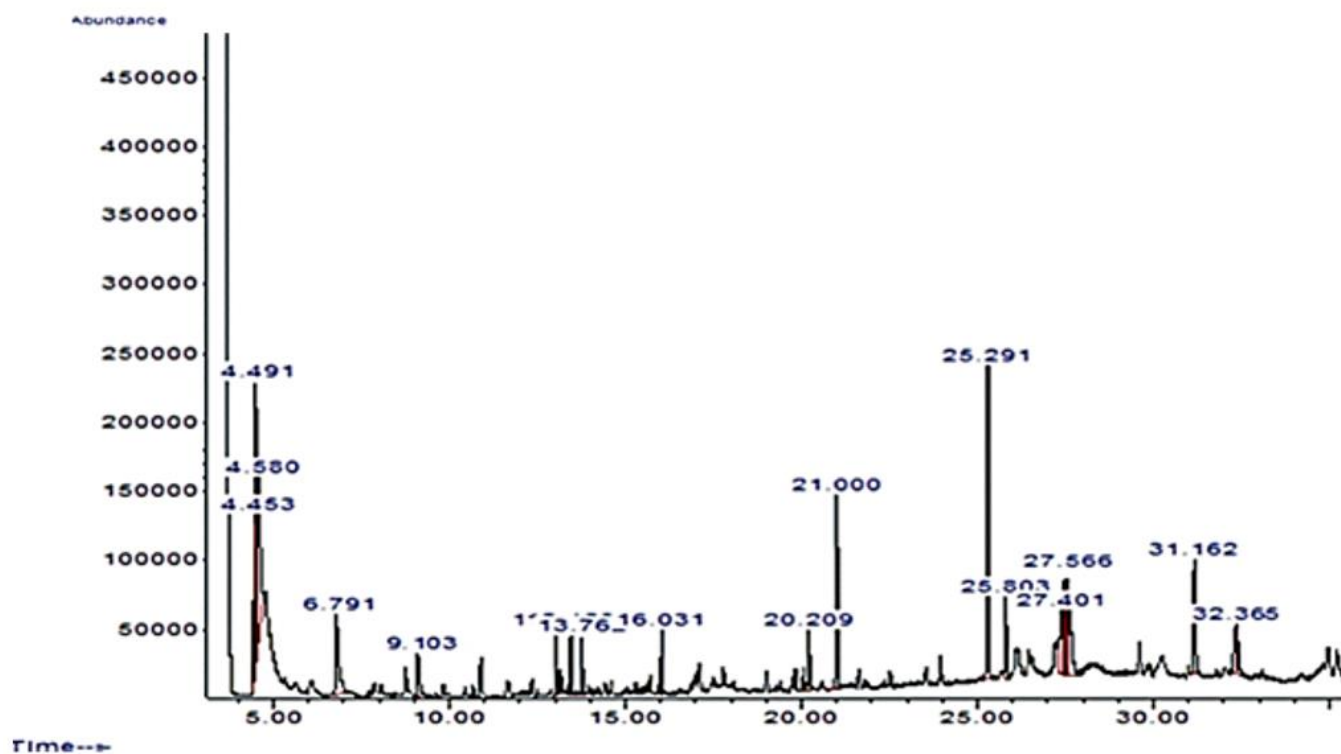
B			
Compound Name	Structure	Medicinal Uses	Reference
1-Octen-3-ol		Antimicrobial properties	[38]
Nonanal		Antifungal activity	[39,40]
trans- $\beta$ -Ionone		Anti-inflammatory, cancer-preventing, antibacterial, antifungal, and antileishmanial	[41]
Phytol		Anti-inflammatory, antinociceptive and antioxidant effects	[42]
trans-Farnesol		Anti-Inflammatory, antimicrobial and anti-Cancer properties	[43]
Squalene		Anticancer and antioxidant activities	[44]





(A)

Figure 1. Cont.



(B)

**Figure 1.** (A). Chromatograms of methanol extract of *C. pepo* by Gas Chromatography-Mass Spectrometry. (B): Chromatograms of methanol extract of *C. pepo* by Gas Chromatography-Mass Spectrometry.

### 3.2. Acute Oral Toxicity

Table 2 shows the acute toxicity study of *C. pepo* in albino rats. The study was carried out via oral administration of *C. pepo* aqueous leaf extract at the single doses of 500, 1000, 2000, 3000, 4000, and 5000 mg/kg. There were no deaths, behavioural changes, or adverse clinical and toxicity signs recorded within 24 h and thereafter for 14 days of *C. pepo* extract treatments.

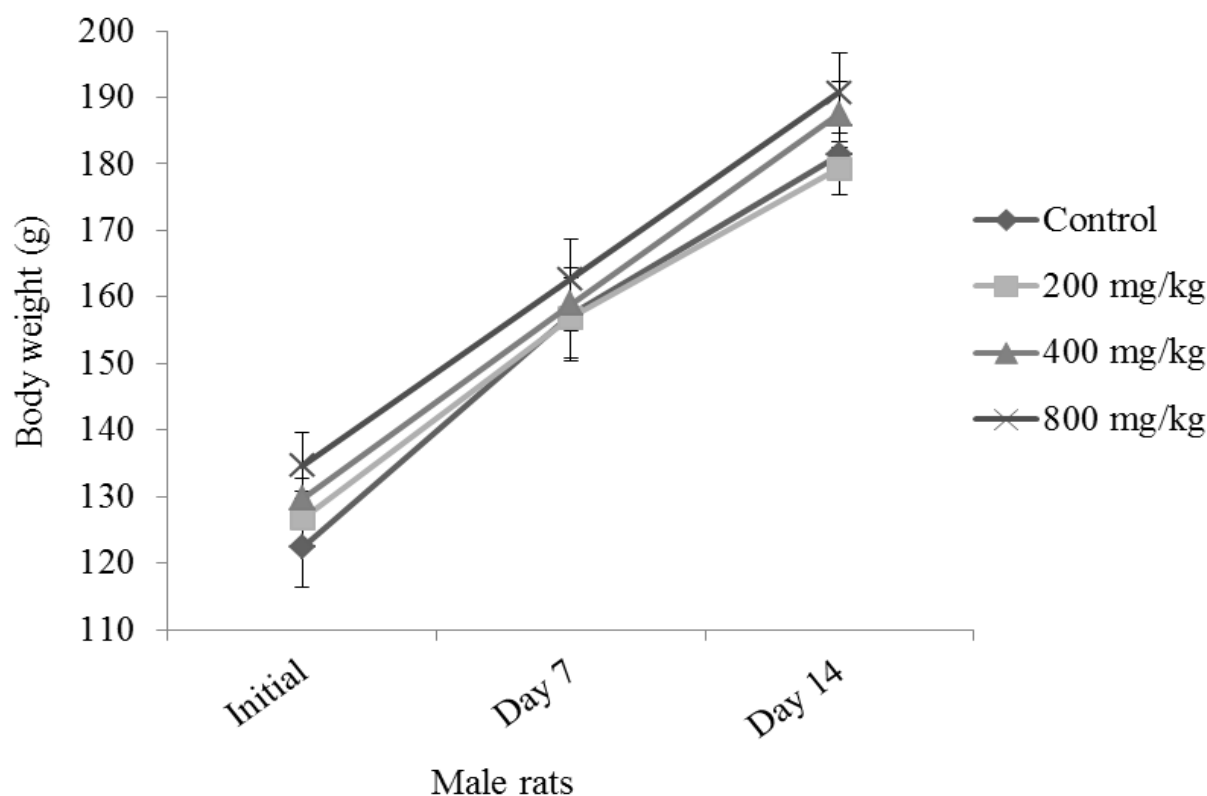
**Table 2.** Acute (oral) toxicity study of albino rats after 24 h oral administration of aqueous *C. pepo* leaf extract.

Dose (mg/kg)	Death/Number of Animals		Death/Total Number of Rats
	Male	Female	
0	0/5	0/5	0/10
500	0/5	0/5	0/10
1000	0/5	0/5	0/10
2000	0/5	0/5	0/10
3000	0/5	0/5	0/10
4000	0/5	0/5	0/10
5000	0/5	0/5	0/10

### 3.3. Subacute Toxicity

The experimental animals did not lose weight throughout the study (Figure 2). Following the body weight increase, there was no significant difference ( $p > 0.05$ ) observed in the final body weight (Day 14) of male rats treated with various doses of *C. pepo* compared to the control. The effect of *C. pepo* did not distort the organ weight of the male rats, and there was no significant difference ( $p > 0.05$ ) observed in the extract treated groups compared to the control group (Table 3).





**Figure 2.** Body weight measurements of male rats treated with aqueous leaf extract of *C. pepo* for 14 days.

**Table 3.** Effect of aqueous *C. pepo* leaf extract on organ weights of male rats.

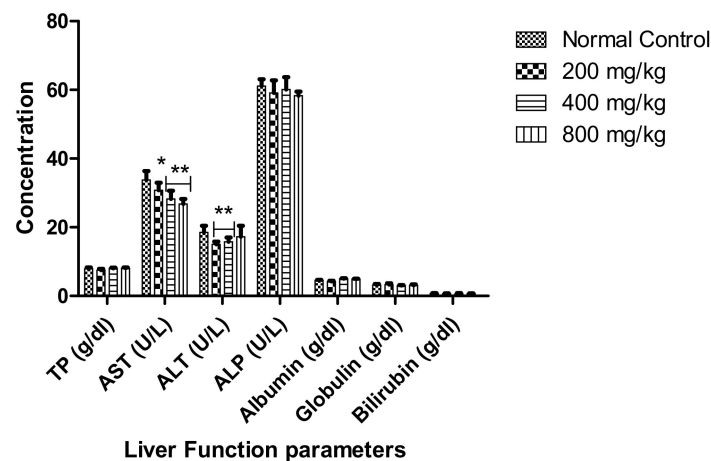
Organs	Cucurbita pepo Extract (mg/kg)			
	Normal Control	200 mg/kg	400 mg/kg	800 mg/kg
Kidney	1.17 ± 0.35	1.01 ± 0.06	0.98 ± 0.15	0.96 ± 0.06
Lungs	1.17 ± 0.35	1.05 ± 0.12	0.98 ± 0.12	0.96 ± 0.29
Spleen	0.97 ± 0.25	0.81 ± 0.17	0.76 ± 0.20	0.77 ± 0.10
Liver	6.53 ± 0.58	5.69 ± 0.12	5.46 ± 0.47	5.19 ± 0.26
Heart	0.57 ± 0.06	0.49 ± 0.12	0.49 ± 0.06	0.50 ± 0.06
Testes	2.37 ± 0.06	2.07 ± 0.12	1.99 ± 0.20	1.97 ± 0.12

Values represent the mean ± SD for  $n = 6$ .

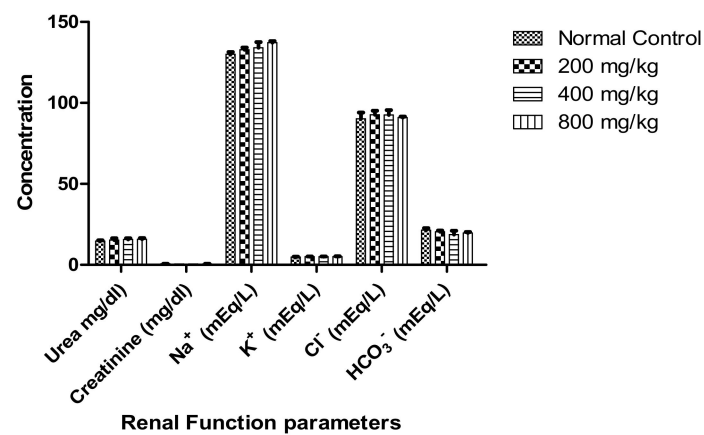
### 3.4. Effect on Biochemical and Hematological Parameters

There was significant decrease following a dose-dependent manner in the values of aspartate transaminase (AST) of the *C. pepo* groups. A significant ( $p < 0.05$ ) decrease in ALT content was observed in 200 and 400 mg/kg body weight *C. pepo* treated rats when compared to the control group. However, other liver biomarkers, including total protein, alkaline phosphatase (ALP), albumin, globulin, and bilirubin, were not significantly affected ( $p > 0.05$ ) when compared to the control group (Figure 3).

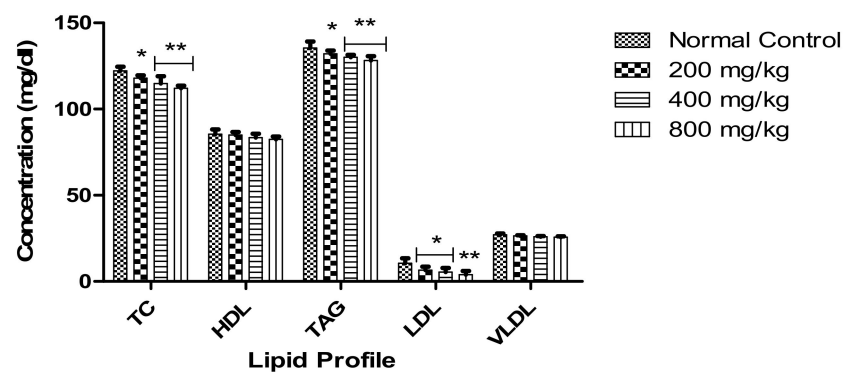
Administration of *C. pepo* did not reveal any statistical difference ( $p > 0.05$ ) in the renal functional biomarkers (urea, creatinine,  $\text{Na}^+$ ,  $\text{K}^+$ ,  $\text{Cl}^-$ , and  $\text{HCO}_3^-$ ) among the *C. pepo* treated groups and the control group (Figure 4). The extract revealed a significant decrease in the values of TC, TAG, and LDL compared to the control, while HDL and VLDL did not reveal any statistical difference ( $p > 0.05$ ) compared to the control (Figure 5). Administration of *C. pepo* increased all the analysed enzymatic antioxidant parameters (GSH, SOD, and CAT) with statistical increase ( $p < 0.05$ ) recorded in the values of GSH in the treated groups compared to the control (Figure 6).



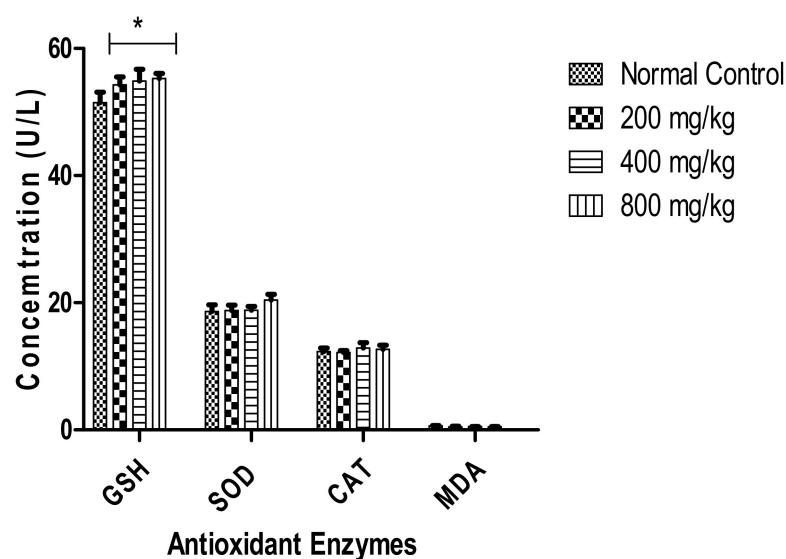
**Figure 3.** Effect of aqueous *C. pepo* leaf extract on liver function parameters of male rats. Values represent the mean  $\pm$  SD for  $n = 6$ . \* indicates significance at ( $p < 0.05$ ) and double asterisk (\*\*) indicates significance at  $p < 0.01$ . TP, Total Protein; AST, Aspartate Aminotransferase; ALT, Alanine Transaminase; and ALP, Alkaline Phosphatase.



**Figure 4.** Effect of aqueous *C. pepo* leaf extract on kidney function parameters of male rats. Values represent the mean  $\pm$  SD for  $n = 6$ . Cl<sup>-</sup>, Chloride ion; Na<sup>+</sup>, Sodium ion; K<sup>+</sup>, Potassium ion; and HCO<sub>3</sub><sup>-</sup>, Bicarbonate.



**Figure 5.** Effect of aqueous *C. pepo* leaf extract on lipid profile of male rats. Values represent the mean  $\pm$  SD for  $n = 6$ . \* indicates significance at ( $p < 0.05$ ) and \*\* indicates significance at  $p < 0.01$ . TC Total Cholesterol; HDL-C, High-Density Lipoprotein Cholesterol; TAG, Triglyceride; LDL-C, Low-Density Lipoprotein Cholesterol; and VLDL-C, Very Low-Density Lipoprotein Cholesterol.



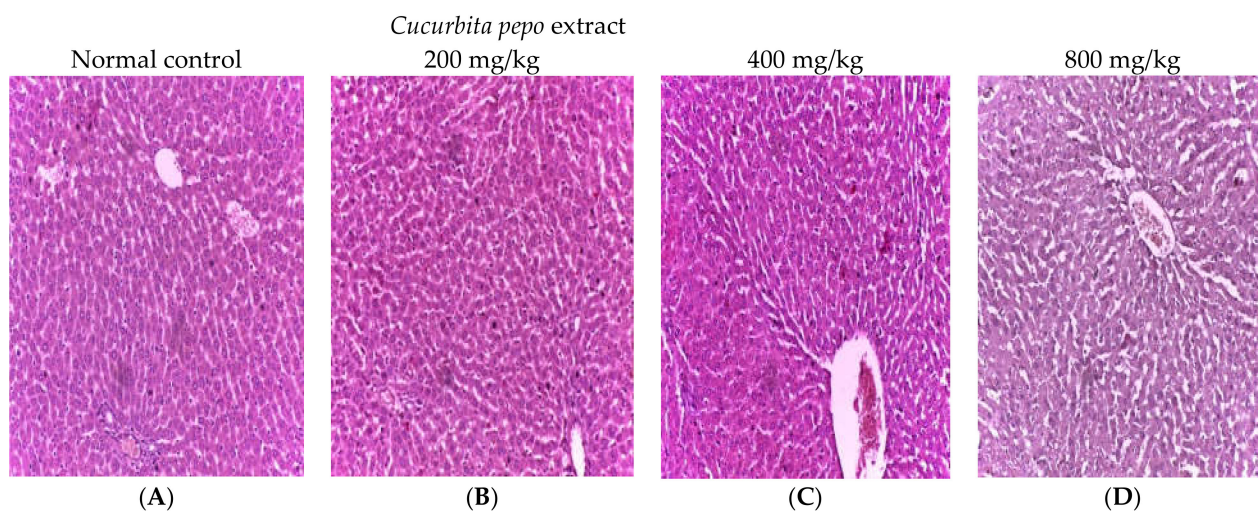
**Figure 6.** Effect of aqueous extract of *C. pepo* on antioxidant enzyme on male rats. Values represent the mean  $\pm$  SD for  $n = 6$ . \* indicates significance at ( $p < 0.05$ ). Group of bars without asterisks are not significant at  $p < 0.05$ . GSH, Glutathione; SOD, Superoxide Dismutase; CAT, Catalase; and MDA, Malondialdehyde.

The effects of aqueous leaf extract of *C. pepo* administration after 14 days treatment on haematological parameters is shown in Table 4. The parameters of RBC, PCV, HB, WBC, MCH, platelet, monocyte, eosinophil, and basophil did not significantly differ ( $p > 0.05$ ) from the control group, whereas there was a significant ( $p < 0.05$ ) dose-dependent decrease in the values of MCV, MCHC, neutrophil, and lymphocyte when compared to the control group. The histopathological analysis of the liver and kidney of the *C. pepo*-treated rats and the control group did not reveal any alteration or detrimental changes in the architecture of the liver and kidney (Figures 7 and 8).

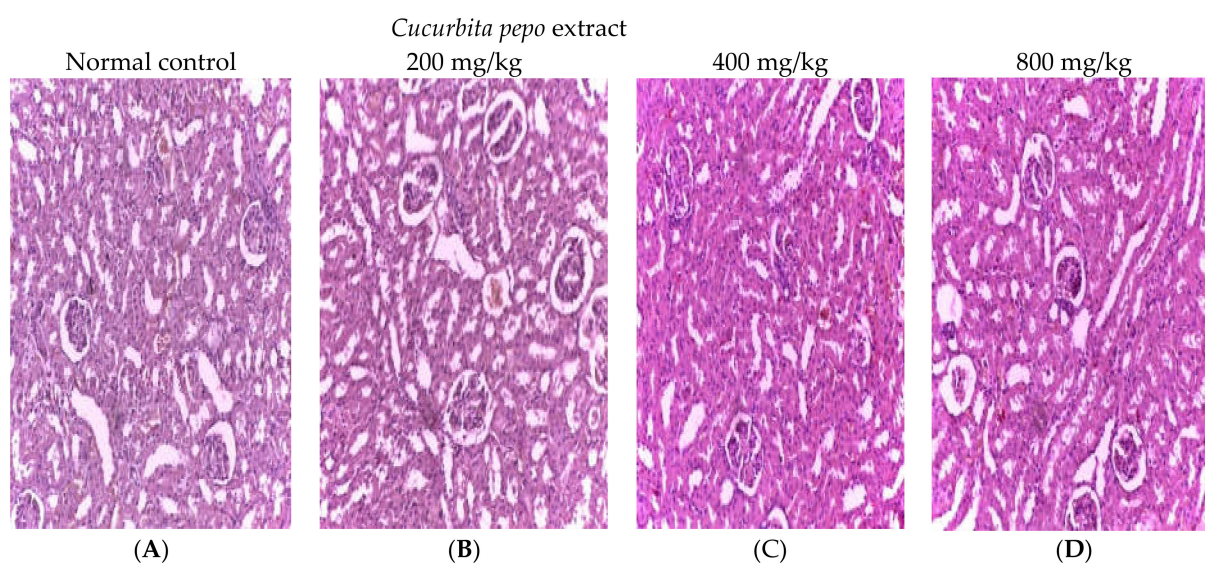
**Table 4.** Effect of aqueous *C. pepo* leaf extract on haematological parameters of male rats.

Parameters	Cucurbita pepo Leaf Extract (mg/kg)			
	Normal Control	200 mg/kg	400 mg/kg	800 mg/kg
RBC ( $\times 10^{12}/L$ )	6.19 $\pm$ 0.23 <sup>a</sup>	5.91 $\pm$ 0.39 <sup>a</sup>	5.82 $\pm$ 0.14 <sup>a</sup>	5.78 $\pm$ 0.75 <sup>a</sup>
PCV (%)	40.75 $\pm$ 0.96 <sup>a</sup>	38.37 $\pm$ 2.22 <sup>a</sup>	37.52 $\pm$ 0.82 <sup>a</sup>	36.98 $\pm$ 5.20 <sup>a</sup>
HB (g/dL)	12.41 $\pm$ 0.19 <sup>a</sup>	11.86 $\pm$ 1.00 <sup>a</sup>	11.62 $\pm$ 0.24 <sup>a</sup>	11.54 $\pm$ 0.52 <sup>a</sup>
WBC ( $\times 10^9/L$ )	12.99 $\pm$ 4.60 <sup>a</sup>	11.08 $\pm$ 0.32 <sup>a</sup>	10.34 $\pm$ 0.87 <sup>a</sup>	9.97 $\pm$ 1.02 <sup>a</sup>
Platelet ( $\times 10^9/L$ )	307.25 $\pm$ 26.22 <sup>a</sup>	282.15 $\pm$ 18.39 <sup>a</sup>	279.19 $\pm$ 18.63 <sup>a</sup>	280.54 $\pm$ 35.00 <sup>a</sup>
MCV (fl)	65.91 $\pm$ 1.24 <sup>a</sup>	59.18 $\pm$ 2.15 <sup>b</sup>	56.67 $\pm$ 1.75 <sup>b</sup>	54.25 $\pm$ 9.82 <sup>b</sup>
MCH (pg)	20.07 $\pm$ 0.50 <sup>a</sup>	18.14 $\pm$ 0.48 <sup>a</sup>	17.40 $\pm$ 0.41 <sup>a</sup>	17.12 $\pm$ 0.73 <sup>a</sup>
MCHC (g/L)	30.29 $\pm$ 0.59 <sup>a</sup>	27.79 $\pm$ 0.75 <sup>b</sup>	26.88 $\pm$ 0.33 <sup>b</sup>	26.63 $\pm$ 1.16 <sup>b</sup>
Neutrophil (%)	57.25 $\pm$ 2.22 <sup>a</sup>	50.35 $\pm$ 1.71 <sup>b</sup>	48.85 $\pm$ 1.29 <sup>b</sup>	47.80 $\pm$ 2.16 <sup>b</sup>
Lymphocyte (%)	34.50 $\pm$ 2.38 <sup>b</sup>	32.49 $\pm$ 1.73 <sup>b</sup>	31.13 $\pm$ 2.22 <sup>b</sup>	30.66 $\pm$ 2.06 <sup>b</sup>
Monocyte (%)	5.00 $\pm$ 0.82 <sup>a</sup>	4.48 $\pm$ 0.50 <sup>a</sup>	4.42 $\pm$ 0.50 <sup>a</sup>	4.44 $\pm$ 0.58 <sup>a</sup>
Eosinophil (%)	3.00 $\pm$ 0.20 <sup>a</sup>	2.60 $\pm$ 0.96 <sup>a</sup>	2.53 $\pm$ 0.50 <sup>a</sup>	2.53 $\pm$ 0.82 <sup>a</sup>
Basophil (%)	0.25 $\pm$ 0.50 <sup>a</sup>	0.48 $\pm$ 0.50 <sup>a</sup>	0.55 $\pm$ 0.50 <sup>a</sup>	0.58 $\pm$ 0.50 <sup>a</sup>

Values represent the mean  $\pm$  SD for  $n = 6$ . Values in the same row bearing the same letter of the alphabet are not significantly different from each other ( $p > 0.05$ ). RBC, Red Blood Cells; PCV, Packed Cell Volume; HB, Haemoglobin; MCV, Mean Corpuscular Volume; MCH, Mean Corpuscular Haemoglobin; MCHC, Mean Corpuscular Haemoglobin Concentration; and WBC, White Blood Cell.



**Figure 7.** Micrographs of the liver sections from untreated (control) and treated albino rats with various doses of aqueous leaf extract of *C. pepo*. Haematoxylin and eosin staining (H and E), magnification ( $400\times$  g). (A), control; (B), Albino rats treated with 200 mg/kg aqueous leaf extract of *C. pepo*; (C), Albino rats treated with 400 mg/kg aqueous leaf extract of *C. pepo*; and (D), Albino rats treated with 800 mg/kg aqueous leaf extract of *C. pepo*.



**Figure 8.** Micrographs of the kidney sections from untreated (control) and treated albino rats with various doses of aqueous leaf extract of *C. pepo*. Haematoxylin and eosin staining (H and E), magnification ( $400\times$  g). (A), control; (B), Albino rats treated with 200 mg/kg aqueous leaf extract of *C. pepo*; (C), Albino rats treated with 400 mg/kg aqueous leaf extract of *C. pepo*; and (D), Albino rats treated with 800 mg/kg aqueous leaf extract of *C. pepo*.

### 3.5. Wound Healing Activity

Table 5 represents the effects of aqueous leaf extract of *C. pepo* on circular excision % wound contraction and epithelialization time. In this study, application of *C. pepo* extract on the excision wound rats resulted in a significantly ( $p < 0.05$ ) higher rate of wound healing in comparison to the control group. The rats treated with *C. pepo* extract had a significant ( $p < 0.05$ ) % WC on days 4, 8, 12, and 16 compared to the 5% w/w PI treated rats and control group. On day 16, 100% wound contraction was recorded for the *C. pepo* extract-treated group, whereas 94.06% and 65.88% were recorded for 5% w/w PI-treated rats and control groups, respectively. A complete and better healing closure was observed in

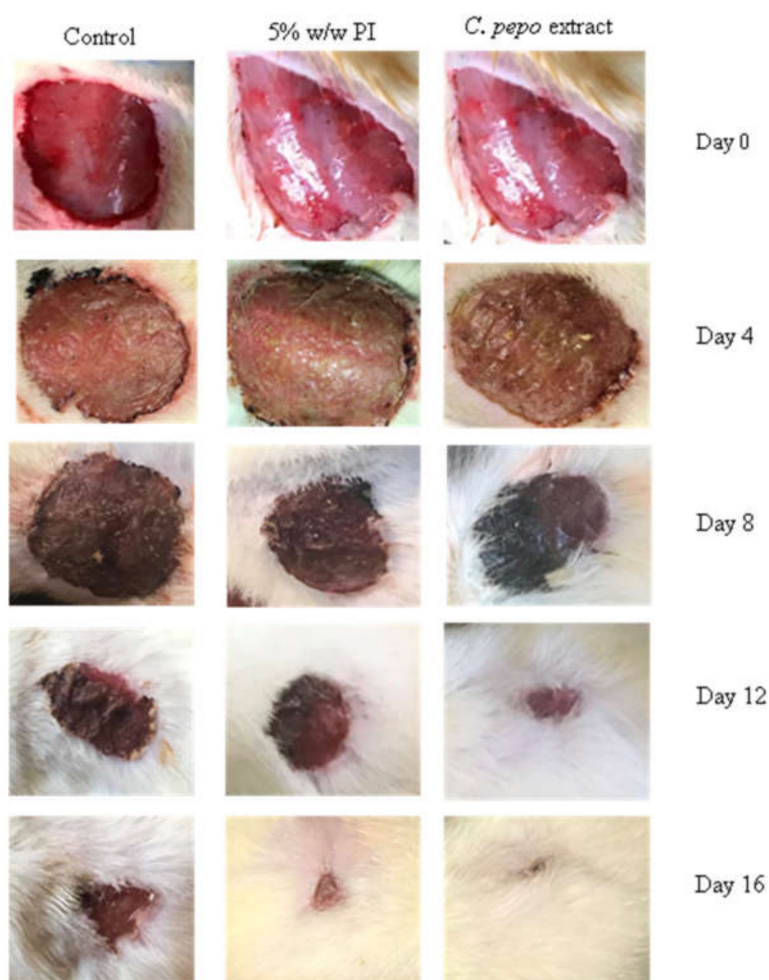


*C. pepo*-treated rats (12–16 days) compared to the 5% *w/w* PI-treated rats and control group (12–16 days) (Figure 9). In addition, *C. pepo* extract-treated group had the shortest epithelialization period of 16 days compared to 5% *w/w* PI-treated rats (20 days) and control group (22 days).

**Table 5.** Effect of *C. pepo* extract on circular excision wound model.

Group	Day 0	Day 4	Day 8	Day 12	Day 16	Day 20	EIN (Days)
C (HA)	440.00 ± 10.00	350.00 ± 20.00	280.00 ± 26.45	243.33 ± 15.28	150.00 ± 10.00	60.00 ± 10.00 <sup>b</sup>	22
% WC	-	20.46 ± 2.23 <sup>a</sup>	36.25 ± 6.52 <sup>a</sup>	44.64 ± 4.46 <sup>a</sup>	65.88 ± 2.71 <sup>a</sup>	86.39 ± 1.97 <sup>b</sup>	
PI (HA)	416.00 ± 6.56	270.00 ± 10.00	160.00 ± 10.00	90.00 ± 10.00	40.00 ± 10.00	0.00 ± 0.00	20
% WC	-	35.10 ± 2.23 <sup>b</sup>	61.54 ± 2.25 <sup>b</sup>	78.34 ± 2.74 <sup>b</sup>	94.06 ± 4.61 <sup>b</sup>	100 ± 0.00	
<i>C. pepo</i> extract (HA)	412.33 ± 2.52	211.67 ± 7.64	126.67 ± 20.82	40.00 ± 10.00	0.00 ± 0.00	0.00 ± 0.00	16
% WC	-	48.66 ± 1.81 <sup>c</sup>	65.93 ± 4.46 <sup>b</sup>	90.05 ± 2.83 <sup>c</sup>	100 ± 0.00	100 ± 0.00	

C, Control; PI, Povidone iodine; HA, Healed area; WC, % of wound contraction; and EIN: Epithelialization. Data indicate mean ± SD, *n* = 6, *p* < 0.05. Values in the same row bearing the same letter of the alphabet are not significantly different from each other (*p* > 0.05).



**Figure 9.** Photographs of post-excision wound contraction of control, povidone (PI) iodine and *C. pepo* extract treated rats.

In the measurement of tensile strength, the *C. pepo* extract-treated group had a significant ( $p < 0.05$ ) increase in tensile strength (334.03 g) compared to 5% *w/w* PI-treated rats (240.33 g) and control group (192.83 g) (Table 6).

**Table 6.** Effect of applying Povidone iodine and *C. pepo* extract on tensile strength of rats' incision wounds.

Group	Tensile Strength (g)
Control	192.83 ± 7.15 <sup>a</sup>
Providone iodine	240.33 ± 6.50 <sup>b</sup>
<i>C. pepo</i> extract	334.03 ± 12.48 <sup>c</sup>

Data indicates mean ± SD,  $n = 6$ ,  $p < 0.05$ . Values in the same column bearing the same letter of the alphabets are not significantly different from each other ( $p > 0.05$ ).

### 3.6. Effect of *C. pepo* Extract on Egg Albumin-Induced Paw Inflammation

All doses of orally administered *C. pepo* extract significantly inhibited egg albumin induced paw inflammations in experimental rats when compared with control ( $p < 0.05$ ), with the degrees of anti-inflammatory activities produced by 200, 400, and 800 mg/kg of the extract comparing favourably with that of 100 mg/kg body weight of aspirin (Table 7).

**Table 7.** Effects of paw treatments on paw circumferences.

Parameters	<i>Cucurbita pepo</i> Extract				
	Control	Aspirin 100 mg/kg	200 mg/kg	400 mg/kg	800 mg/kg
Pre induction paw circumference (mm)	23.67 ± 2.62 <sup>a</sup>	25.67 ± 1.89 <sup>a</sup>	26.33 ± 0.94 <sup>a</sup>	21.33 ± 2.62 <sup>a</sup>	24.33 ± 0.47 <sup>a</sup>
Paw circumference at induction (mm)	34.33 ± 1.70 <sup>a</sup>	34.67 ± 1.25 <sup>a</sup>	33.67 ± 0.47 <sup>a</sup>	33.67 ± 0.47 <sup>a</sup>	33.33 ± 1.89 <sup>a</sup>
Paw circumference, 30 min. post-induction (mm)	38.67 ± 2.62 <sup>c</sup>	31.67 ± 1.25 <sup>a</sup>	33.67 ± 0.47 <sup>a</sup>	33.00 ± 0.00 <sup>a</sup>	35.00 ± 0.00 <sup>b</sup>
Paw circumference, 60 min. post-induction (mm)	40.67 ± 0.47 <sup>b</sup>	28.00 ± 2.16 <sup>a</sup>	31.67 ± 1.25 <sup>a</sup>	30.00 ± 0.82 <sup>a</sup>	32.00 ± 0.00 <sup>a</sup>
Paw circumference, 120 min. post-induction (mm)	37.33 ± 1.70 <sup>c</sup>	24.33 ± 2.62 <sup>a</sup>	30.00 ± 0.82 <sup>b</sup>	28.33 ± 0.47 <sup>b</sup>	30.00 ± 0.82 <sup>b</sup>

Data indicate mean ± SD,  $n = 6$ ,  $p < 0.05$ . Values in the same row bearing the same letter of the alphabet are not significantly different from each other ( $p > 0.05$ ).

Although at induction only the lowest dose (200 mg/kg) group had a significantly lower percentage rise in paw circumference when compared with control, the anti-inflammatory effects of all doses of the extract and that of aspirin became visible after 30 min of induction as the degrees of inflammations steadily dropped in the extract and aspirin groups but continued to rise in control (Table 8).



**Table 8.** Effect of treatments on percentage increase in paw circumferences.

Parameters	<i>Cucurbita pepo</i> Extract (mg/kg)				
	Control	Aspirin 100 mg/kg	200 mg/kg	400 mg/kg	800 mg/kg
% Rise in paw circumference at induction	46.15 ± 9.81 <sup>c</sup>	35.91 ± 12.36 <sup>b</sup>	27.95 ± 2.86 <sup>a</sup>	60.31 ± 20.35 <sup>d</sup>	37.11 ± 9.37 <sup>b</sup>
% Fall in paw circumference, 30 min. post-induction	−13.21 ± 12.64 <sup>a</sup>	8.66 ± 0.32 <sup>d</sup>	−0.03 ± 2.44 <sup>b</sup>	1.96 ± 1.39 <sup>c</sup>	−5.33 ± 5.73 <sup>b</sup>
% Fall in paw circumference, 60 min. post-induction	−14.16 ± 12.79 <sup>a</sup>	19.32 ± 3.90 <sup>d</sup>	5.91 ± 4.14 <sup>b</sup>	10.90 ± 1.48 <sup>c</sup>	3.70 ± 5.24 <sup>b</sup>
% Fall in paw circumference, 120 min. post-induction	−8.79 ± 2.43 <sup>a</sup>	26.14 ± 5.09 <sup>d</sup>	10.87 ± 2.72 <sup>b</sup>	15.84 ± 1.29 <sup>c</sup>	9.61 ± 7.07 <sup>b</sup>

Data indicate mean ± SD,  $n = 6$ ,  $p < 0.05$ . Values in the same row bearing the same letter of the alphabet are not significantly different from each other ( $p > 0.05$ ).

By the end of 120 min, the percentage fall in paw circumference in control was  $-6.27 \pm 12.38$  (still indicating steady rise) while in the 200, 400, and 800 mg/kg treated groups, percentage fall in paw circumferences were  $11.66 \pm 2.49\%$ ,  $15.36 \pm 2.52\%$ , and  $14.95 \pm 8.58\%$ , respectively, comparing favourably with the aspirin group where the fall was  $25.74 \pm 5.14\%$  (Table 8).

Percentage anti-inflammatory activities for 200, 400, and 800 mg/kg treatment levels of *C. pepo* extract were  $175.95 \pm 75.93\%$ ,  $217.14 \pm 105.79\%$ , and  $215.00 \pm 176.57\%$ , respectively and compared well with  $314.52 \pm 193.20\%$  obtained for aspirin (Table 9).

**Table 9.** Change in paw circumference and percentage anti-inflammatory activities after 120 min.

	<i>Cucurbita pepo</i> Extract				
	Control	Aspirin 100 mg/kg	200 mg/kg	400 mg/kg	800 mg/kg
Fall in paw circumference after 120 min (mm)	−3.00 ± 0.82 <sup>a</sup>	9.00 ± 1.41 <sup>c</sup>	3.67 ± 0.94 <sup>b</sup>	5.33 ± 0.47 <sup>b</sup>	3.33 ± 2.62 <sup>b</sup>
Percentage anti-inflammatory activity	0.00 ± 0.00	318.65 ± 73.88 <sup>d</sup>	225.00 ± 20.41 <sup>b</sup>	288.89 ± 43.74 <sup>c</sup>	163.89 ± 30.68 <sup>a</sup>

Data indicate mean ± SD,  $n = 6$ ,  $p < 0.05$ . Values in the same row bearing the same letter of the alphabet are not significantly different from each other ( $p > 0.05$ ).

#### 4. Discussion

There are several acclaimed therapeutic potentials of *C. pepo* as alternative medicine in the management and treatment of various diseases such as diabetes, benign prostatic hyperplasia, and rheumatism as well as inflammations, burns, and wound injuries. However, no scientific study has documented the toxicity profile or anti-inflammatory and wound healing potentials of *C. pepo*. Therefore, it is pertinent to investigate the safety profile, wound healing, and anti-inflammatory properties of phytochemical characterized aqueous leaf extract of *C. pepo* in rats.

The use of gas chromatography-mass spectrometry (GC-MS) for a very detailed evaluation of bioactive chemicals in plant-based compounds is a well-accepted approach [45]. The GC-MS analysis of *C. pepo* showed the presence of fifteen (15) chemical compounds with 1-heneicosanol (12.32%) and squalene (1.73%) as the most abundant and least abundant, respectively. Six out of the fifteen identified compounds are known to have some pharmacological potential. These include 1-Octen-3-ol, noanal, trans- $\beta$ -lonone, phytol, trans-farnesol, and squalene. Xiong et al. [38] reported the antimicrobial properties of 1-Octen-3-ol, while Zhang et al. [39] and Li et al. [40] revealed the antifungal properties of noanal. In other studies, trans- $\beta$ -lonone has been shown to possess anti-inflammatory, cancer-preventing, antibacterial, antifungal, and anti-leishmanial activities [41], while phy-

tol, trans-farnesol, and squalene have biological activities including anti-inflammatory, antinociceptive, antioxidant, anti-cancer, and antimicrobial properties [42–44].

In acute and subacute toxicity studies, appropriate animal models such as rats or mice can be commonly used to evaluate the health risk of any plant extracts or chemical substances [46]. In an acute toxicity study, single-dose oral administration of aqueous leaf extract of *C. pepo* up to 5000 mg/kg did not cause any death or toxicity signs. Based on the result, the LD<sub>50</sub> of *C. pepo* is higher than 5000 mg/kg, and following OECD [23] guidelines *C. pepo* can be classified as a class 5 substance and therefore considered a safe and non-toxic substance.

In the subacute toxicity study, there was no change in body weight after 14 days of *C. pepo* treatment, indicating that it is safe at all dose levels. Adverse effects of medications and chemicals are identified by changes in body weight [47]. Organ weight changes have long been known as a sensitive sign of chemical-induced organ toxicity, such as organ hypertrophy [48]. As a result, relative organ weight is an important measure in toxicity investigations. When compared to normal control animals, no significant change ( $p > 0.05$ ) in relative organ weight was found after treatment with *C. pepo* at all dose levels.

Hepatic and renal function tests are used as fingerprint markers to determine the inherent toxicity and pathological states that are tracked to determine organ toxicity or dysfunction caused by hazardous substances [49]. Electrolytes, urea, and creatinine can all be used to determine renal toxicity [50]. Cirrhosis, fibrosis, and liver destruction are all symptoms of hepatotoxicity, which is caused by exposure to toxic substances. Hepatic enzymes such as AST, ALT, and ALP were measured to determine the amount of liver necrosis [51]. In humans, elevated plasma bilirubin levels suggest haemolytic anaemia [52]. The *C. pepo* administration reduced AST levels but did not affect total protein, ALP, albumin, globulin, or bilirubin levels when compared to the control group. Electrolytes are necessary for the body's homeostatic balance to be maintained. Sodium keeps the body's acid–base balance in check and protects it from excessive fluid loss [53]. Pathological conditions can be caused by changes in plasma electrolyte balance. When compared to the normal control group, there was no significant change ( $p > 0.05$ ) in plasma electrolyte levels ( $\text{Na}^+$ ,  $\text{K}^+$ ,  $\text{Cl}^-$ , and  $\text{HCO}_3^-$ ) after treatment with *C. pepo*, indicating that there was no harmful effect on electrolyte levels. Furthermore, there was no statistical difference ( $p < 0.05$ ) in the values of urea and creatinine after administration of *C. pepo*, indicating no detrimental effect on the functionality of the renal system.

Toxic substances primarily influence the haematopoietic system, which is a very sensitive and significant indicator of physiological and pathological conditions in humans and animals [54]. Toxicants change haematological parameters, resulting in disorders such as anaemia, leukopenia, thrombocytopenia, and bone marrow depression, among others [52]. *C. pepo* leaf extract did not have a deleterious effect on WBC, RBC, or platelets, nor did it interfere with the haematopoiesis and leucopoiesis processes according to the findings. When compared to the normal control, no toxic changes in all of the studied haematological parameters were seen after 14 days of treatment with *C. pepo*, indicating no haematotoxic effect and safety at all dose levels.

When compared to the control, *C. pepo* administration reduced atherogenic lipid markers including TC, TAG, and LDL considerably, while HDL and VLDL showed no statistical change ( $p > 0.05$ ). This suggests that *C. pepo* may have hypolipidemic properties.

*C. pepo* administration slightly increased the enzymatic antioxidant parameters GSH, SOD, and CAT with a statistically significant increase ( $p < 0.05$ ) in GSH levels in the treated groups compared to the control group. Other studies have shown that intake of toxic chemicals affects antioxidant enzymes and elevates MDA levels [55]. MDA is a lipid peroxidation biomarker that may be elevated as a result of toxin ingestion or other diseases [55]. Membrane polyunsaturated fatty acids are reduced by lipid peroxidation, which produces aldehydes including MDA, 4-hydroxynonenal, and acrolein, disrupting and changing the functions of the membrane [56,57]. Lipid peroxidation has been considered an indication of oxidative stress [58,59]. It alters the membrane's structure by causing changes in fluidity

and permeability [60]. Reduced MDA levels and higher GSH, SOD, and CAT levels seen in this study have been reported to protect against oxidative stress [61]. The results supported that *C. pepo* possesses antioxidant properties. Nkosi et al. [62] reported the antioxidative activity of *C. pepo* against carbon tetrachloride-induced hepatotoxicity in rats fed with a low protein diet.

In humans and animals, exposure to various hazardous chemicals raises oxidant levels and induces oxidative DNA damage, which leads to cellular damage and tissue necrosis [63]. A histopathological examination can assist us to determine whether organs have been damaged at the cellular level as a result of a harmful chemical action. The liver and kidneys of rats given varying doses of *C. pepo* showed no signs of pathological damage. These findings backed up the results of biochemical tests, as well as the safety of *C. pepo* leaf extract in rats.

The wound healing process aids in the recovery of injured tissue layers and cellular structure. The wound area shrinks as the fibroblast stage begins [64]. Contraction, granulation, epithelization, and collagenation are all part of this complicated process [65,66]. Microbial infections, the presence of free radicals, and metabolic disruptions can all cause the multifactorial process of wound healing to be delayed or interrupted [67]. Wound closure, wound contraction, and functional barrier reorganization are significant markers in the wound healing process [68]. Again, because the type of injury has an impact on wound healing, healing phases of wound models, including excision and incision wound models and dead space, are all affected differently [69]. The fundamental goal of wound management is to heal the damage as quickly as possible while causing the least amount of pain and discomfort to the patient. In the current study, the effect of *C. pepo* leaf extract on tissue regeneration was investigated utilizing experimental rat models. Rats were continuously observed and treated topically with prepared ointment from *C. pepo* leaf extract as well as a reference drug after various types of wounds were created. When compared to the control group animals, the *C. pepo* leaf treatment groups and the reference drug-treated group (povidone-iodine) in the excision and incision wounds showed significant ( $p < 0.05$ ) reductions in the wound area, rapid epithelization, and rapid rate of wound closure.

It has been reported that, at wound sites, high amounts of reactive oxygen species such as oxygen singlet, hydroxyl radicals, superoxide anion, and hydrogen peroxide stimulate collagen breakdown and hence extracellular matrix degradation (ECM). When the ECM is damaged, processes such as angiogenesis and re-epithelization that are necessary for wound healing are reduced [70,71]. The photograph section of the post-excision wound contraction is shown in Figure 9. From the result, there was a great tissue restoration in the groups that were treated with *C. pepo*, and this wound restoration manifested as the day progressed, significantly showed on day 4, and completely healed on day 16. Interestingly, the improvement in the excision wound healing compared favourably to the group that was treated with 5% *w/w* PI (standard drug). On day 16, the extract-treated group revealed a stronger healing effect compared to the untreated group. Our study showed that *C. pepo* increased % WC and tensile strength and reduced epithelialization days which are evidence of potent wound healing capacity. A phytochemical enriched antioxidant such as squalene may boost the production of antioxidants such as superoxide dismutase and catalase in excised wounds and lower the activity of malondialdehyde [42,72]. The findings from the antioxidant activities as well as the bioactive constituents of *C. pepo* leaf extract may have synergistically aided in the elicited wound healing potential of the resource plant.

This study also investigated the anti-inflammatory activity of *C. pepo* extract in egg albumin-induced paw inflammation in rats with results indicating significant inhibition of paw inflammations in all test rats pre-treated with the extract before induction. Paw circumferences of these treated rats were also found to be significantly lower than those of the control rats and compared favourably with those of rats pretreated with aspirin, a standard anti-inflammatory agent. The entire results, therefore, suggest that *C. pepo* extract may contain substances with anti-inflammatory activities and may have achieved this effect by truncating the established physiologic inflammatory pathway of egg albumin-induced

inflammation. Usually, egg albumin induces edema due to its ability to trigger the release of histamine and serotonin and eventual prostaglandin release, leading to inflammation [73]. Another inflammatory pathway is activating the release of cyclo-oxygenase (COX) which also leads to prostaglandins release and eventual onset of pain, swelling (inflammation) and fever [37]. The extract at all administered doses progressively reduced the increased paw circumference (oedema) induced by egg albumin in the test rats and may have achieved this effect by inhibiting/reducing the release of histamine and serotonin due to egg albumin injection and by inhibiting COX activity, having produced activity like that of aspirin, a non-steroidal anti-inflammatory agent known for its anti-inflammatory activity via COX activity inhibition [37].

## 5. Conclusions

The present study demonstrated that *C. pepo* leaf has relevant bioactive compounds with known pharmacological activities. This study also showed that *C. pepo* leaf extract is non-toxic and could be used in ethnomedicine for the management and treatment of various diseases and as a source of nutrients without any detrimental effect. This is demonstrated by the extract's non-distortive influence on the haematological and biochemical parameters of the treated rats. The therapeutic potential of aqueous leaf extract of *C. pepo* in wound healing was established in this study.

The topical ointment made from the aqueous extract of *C. pepo* leaf extract has a wide range of healing qualities for both the incision and excision wound models. The results demonstrated a remarkable improvement in percentage wound contraction. It also clearly exhibits enhanced wound tensile strength and significantly reduced epithelization days in rats treated with *C. pepo* leaf extract. In addition, the results obtained from this study also established the anti-inflammatory activity of *C. pepo* extract against egg albumin-induced paw oedema in rats. Based on the findings of this present study, *C. pepo* could be considered a wound healing and anti-inflammatory agent with a wide margin of safety. However, additional studies on the chronic toxicity of *C. pepo* and histological examination of the healed wound sites treated with *C. pepo* extract should be investigated.

**Author Contributions:** E.I.A., E.A.U. and O.E. designed the study; E.A.U., C.N.E., O.C.U., O.G.E. and T.R.O. conducted the experiment. E.A.U. and O.E. analysed the data. All the authors participated in data interpretation and writing of the manuscript. All authors have read and agreed to the published version of the manuscript.

**Funding:** This research was funded by Tertiary Education Trust Fund Institutional Base Research, grant number TETFUND/ABSU/RP/2018.

**Institutional Review Board Statement:** The animal study protocol was approved by the Institutional Ethics Committee of Abia State University (ABSU/REC/BMR/0117, 11 May 2021).

**Informed Consent Statement:** Not applicable.

**Data Availability Statement:** Not applicable.

**Acknowledgments:** All the authors wish to thank Solomon N. Ijioma and our undergraduate Biochemistry project students (2018 and 2019 academic session) who participated in the preliminary phases of this study.

**Conflicts of Interest:** The authors declare no conflict of interest. The funders had no role in the design of the study; in the collection, analyses, or interpretation of data; in the writing of the manuscript, or in the decision to publish the results.

## Abbreviations

ALT—Alanine transaminase, AST—aspartate transaminase, ALP—alanine phosphatase, CAT—catalase, Cl—chloride ion, COX—cyclooxygenase, ECM—extracellular matrix, EDTA—ethylenediaminetetraacetic acid, EIN—Epithelialization, HA—Healed area, HB—haemoglobin, HCO<sub>3</sub>—bicarbonate, HDL—high density lipoprotein, GSH—glutathione, K<sup>+</sup>—potassium ion, LDL—low density lipoprotein,

MCV—mean corpuscular volume, MCH—mean corpuscular haemoglobin, MCHC—mean corpuscular haemoglobin concentration, MDA—malondialdehyde, Na<sup>+</sup>—sodium ion, PCV—packed cell volume, PI—povidone—iodine, RBC—red blood cell, ROS—reactive oxygen species, SOD—superoxide dismutase, TC—total cholesterol, VLDL—very low density lipoprotein, WBC—white blood cell, and WC—wound contraction.

## References

- Saleem, U.; Khalid, S.; Zaib, S.; Anwar, F.; Ahmad, B.; Ullah, I.; Zeb, A.; Ayaz, M. Phytochemical analysis and wound healing studies on ethnomedicinally important plant *Malva neglecta* Wallr. *J. Ethnopharmacol.* **2020**, *249*, 112401. [CrossRef] [PubMed]
- Ovais, M.; Zia, N.; Ahmad, I.; Khalil, A.T.; Raza, A.; Ayaz, M.; Sadiq, A.; Ullah, F.; Shinwari, Z.K. Phyto-therapeutic and nanomedicinal approach to cure Alzheimer disease: Present status and future opportunities. *Front. Aging Neurosci.* **2018**, *10*, 284. [CrossRef] [PubMed]
- Ayaz, M.; Ullah, F.; Sadiq, A.; Ullah, F.; Ovais, M.; Ahmed, J.; Devkota, H.P. Synergistic interactions of phytochemicals with antimicrobial agents: Potential strategy to counteract drug resistance. *Chem. Biol. Interact.* **2019**, *308*, 294–303. [CrossRef]
- Damiano, R.; Cai, T.; Fornara, P.; Franzese, C.A.; Leonardi, R.; Mirone, V. The role of *Cucurbita pepo* in the management of patients affected by lower urinary tract symptoms due to benign prostatic hyperplasia: A narrative review. *Arch. Ital. Urol. Androl.* **2016**, *88*, 136–143. [CrossRef] [PubMed]
- Ugbogu, E.A.; Ude, V.C.; Elekwa, I.; Arunsi, U.O.; Uche-Ikonne, C.; Nwakanma, C. Toxicological profile of the aqueous-fermented extract of *Musa paradisiaca* in rats. *Avicenna J. Phytomed.* **2018**, *8*, 478–487. [PubMed]
- Lei, Z.Y.; Chen, J.J.; Cao, Z.J.; Ao, M.Z.; Yu, L.J. Efficacy of *Aeschynomene indica* L. leaves for wound healing and isolation of active constituent. *J. Ethnopharmacol.* **2019**, *228*, 156–163. [CrossRef]
- Esimone, C.; Nworu, C.; Jackson, C. Cutaneous wound healing activity of herbal ointment containing the leaf extract of *Jatropha curcas* L. (Euphorbiaceae). *Int. J. Appl. Res. Nat. Prod.* **2008**, *1*, 1–4.
- Ghuman, S.; Ncube, B.; Finnie, J.F.; McGaw, L.J.; Mfotie Njoya, E.; Coopooosamy, R.M.; van Staden, J. Antioxidant, anti-inflammatory and wound healing properties of medicinal plant extracts used to treat wounds and dermatological disorders. *S. Afr. J. Bot.* **2019**, *126*, 232–240. [CrossRef]
- Bowler, P.G.; Duerden, B.I.; Armstrong, D.G. Wound microbiology and associated approaches to wound management. *Clin. Microbiol. Rev.* **2001**, *14*, 244–269. [CrossRef]
- Meguellati, H.; Ouafi, S.; Saad, S.; Djemouai, N. Evaluation of acute, subacute oral toxicity and wound healing activity of mother plant and callus of *Teucrium polium* L. subsp. *geyrii* Maire from Algeria. *S. Afr. J. Bot.* **2019**, *127*, 25–34. [CrossRef]
- Chabane, S.; Boudjelal, A.; Keller, M.; Doubakh, S.; Potterat, O. *Teucrium polium*—Wound healing potential, toxicity and polyphenolic profile. *S. Afr. J. Bot.* **2021**, *137*, 228–235. [CrossRef]
- Okur, M.E.; Karadağ, A.E.; Özhan, Y.; Sipahi, H.; Ayla, Ş.; Daylan, B.; Kültür, Ş.; Demirci, B.; Demirci, F. Anti-inflammatory, analgesic and in vivo-in vitro wound healing potential of the *Phlomis rigida* Labill. extract. *J. Ethnopharmacol.* **2021**, *266*, 113408. [CrossRef] [PubMed]
- Procida, G.; Stancher, B.; Cateni, F.; Zacchigna, M. Chemical composition and functional characterisation of commercial pumpkin seed oil. *J. Sci. Food Agric.* **2013**, *93*, 1035–1041. [CrossRef] [PubMed]
- Adnan, M.; Gul, S.; Batool, S.; Fatima, B.; Rehman, A.; Yaqoob, S.; Shabir, H.; Yousaf, T.; Mussarat, S.; Ali, N.; et al. A review on the ethnobotany, phytochemistry, pharmacology and nutritional composition of *Cucurbita pepo* L. *J. Phytopharmacol.* **2017**, *6*, 133–139.
- Müller, C.; Bracher, F. Determination by GC-IT/MS of phytosterols in herbal medicinal products for the treatment of lower urinary tract symptoms and food products marketed in Europe. *Planta Med.* **2015**, *81*, 613–620. [CrossRef] [PubMed]
- Jafarian, A.; Zolfaghari, B.; Parnianifard, M. The effects of methanolic, chloroform, and ethylacetate extracts of the *Cucurbita pepo* L. on the delay type hypersensitivity and antibody production. *Res. Pharm. Sci.* **2012**, *7*, 217–224. [PubMed]
- Sharma, P.; Kaur, G.; Kehinde, B.A.; Chhikara, N.; Panghal, A.; Kaur, H. Pharmacological and biomedical uses of extracts of pumpkin and its relatives and applications in the food industry: A review. *Int. J. Veg. Sci.* **2020**, *26*, 79–95. [CrossRef]
- Xanthopoulou, M.N.; Nomikos, T.; Fragopoulou, E.; Antonopoulou, S. Antioxidant and lipooxygenase inhibitory activities of pumpkin seed extracts. *Food Res. Int.* **2009**, *42*, 641–646. [CrossRef]
- Badr, S.E.; Shaaban, M.; Elkholy, Y.M.; Helal, M.H.; Hamza, A.S.; Masoud, M.S.; El Safty, M.M. Chemical composition and biological activity of ripe pumpkin fruits (*Cucurbita pepo* L.) cultivated in Egyptian habitats. *Nat. Prod. Res.* **2011**, *25*, 1524–1539. [CrossRef] [PubMed]
- Rahimi, V.B.; Askari, V.R.; Tajani, A.S.; Hosseini, A.; Rakhshandeh, H. Evaluation of the sleep-prolonging effect of *Lagenaria vulgaris* and *Cucurbita pepo* extracts on pentobarbital-induced sleep and possible mechanisms of action. *Medicina* **2018**, *54*, 55. [CrossRef]
- Asowata-Ayodele, A.M.; Afolayan, A.J.; Otunola, G.A. Ethnobotanical survey of culinary herbs and spices used in the traditional medicinal system of Nkonkobe Municipality, Eastern Cape, South Africa. *S. Afr. J. Bot.* **2016**, *104*, 69–75. [CrossRef]
- OECD. Guidance document on acute oral toxicity testing. In *OECD Series on Testing and Assessment*; OECD: Paris, France, 2001. Available online: [https://www.oecd.org/officialdocuments/publicdisplaydocumentpdf/?doclanguage=en&cote=env/jm/mono\(2007\)10](https://www.oecd.org/officialdocuments/publicdisplaydocumentpdf/?doclanguage=en&cote=env/jm/mono(2007)10) (accessed on 20 June 2022).



23. OECD. Test No. 425: Acute Oral Toxicity: Up-And-Down Procedure. In *Guidelines for the Testing of Chemicals*; OECD: Paris, France, 2008.
24. OECD. Test No. 407: Repeated Dose 28-Day Oral Toxicity Study in Rodents. In *Guidelines for the Testing of Chemicals*; OECD: Paris, France, 2008. [\[CrossRef\]](#)
25. Sun, M.; Zigma, S. An improved spectrophotometer assay of superoxide dismutase based on epinephrine antioxidation. *Anal. Biochem.* **1978**, *90*, 81–89. [\[CrossRef\]](#)
26. Aebi, H. Catalase in vitro. In *Method in Enzymology*, 105; Academic Press: New York, NY, USA, 1984; pp. 121–126. [\[CrossRef\]](#)
27. Buege, J.A.; Aust, S.D. Microsomal lipid peroxidation. *Methods Enzymol.* **1978**, *52*, 302–310. [\[CrossRef\]](#)
28. Sedlak, J.; Lindsay, R.H. Estimation of total, protein-bound, and nonprotein sulfhydryl groups in tissue with Ellman's reagent. *Anal. Biochem.* **1968**, *25*, 1192–11205. [\[CrossRef\]](#)
29. Gautam, M.K.; Purohit, V.; Agarwal, M.; Singh, A.; Goel, R.K. In vivo healing potential of aegle marmelos in excision, incision, and dead space wound models. *Sci. World J.* **2014**, *2014*, 740107. [\[CrossRef\]](#)
30. Adewumi, S.S.; Akinpelu, B.A.; Akinpelu, D.A.; Aiyegoro, O.A.; Alayande, K.A.; Agunbiade, M.O. Studies on wound healing potentials of the leaf extract of *Terminalia avicennioides* (Guill. & parr.) on Wistar rats. *S. Afr. J. Bot.* **2020**, *133*, 285–297. [\[CrossRef\]](#)
31. Kumar, M.S.; Kirubanandan, S.; Sripriya, R.; Sehgal, P.K. Triphala promotes healing of infected full-thickness dermal wound. *J. Surg. Res.* **2008**, *144*, 94–101. [\[CrossRef\]](#) [\[PubMed\]](#)
32. Nayak, B.S.; Anderson, M.; Pinto Pereira, L.M. Evaluation of wound-healing potential of *Catharanthus roseus* leaf extract in rats. *Fitoterapia* **2007**, *78*, 540–544. [\[CrossRef\]](#) [\[PubMed\]](#)
33. Singh, H.; Ali, S.S.; Khan, N.A.; Mishra, A.; Mishra, A.K. Wound healing potential of *Cleome viscosa* Linn. seeds extract and isolation of active constituent. *S. Afr. J. Bot.* **2017**, *112*, 460–465. [\[CrossRef\]](#)
34. Agarwal, P.K.; Singh, A.; Gaurav, K.; Goel, S.; Khanna, H.D.; Goel, R.K. Evaluation of wound healing activity of extracts of plantain banana (*Musa sapientum* var. paradisiaca) in rats. *Indian J. Exp. Biol.* **2009**, *47*, 32–40.
35. Kumar, B.; Vinaykumar, M.; Govindarajan, R.; Pushpangadan, P. Ethanopharmacological approaches to wound healing exploring medicinal plants of India. *J. Ethnopharmacol.* **2007**, *114*, 103–113. [\[CrossRef\]](#) [\[PubMed\]](#)
36. Lee, K.H. Studies on mechanism of action of salicylates. Retardation of wound healing by aspirin. *J. Pharm. Sci.* **1968**, *51*, 1042–1043. [\[CrossRef\]](#) [\[PubMed\]](#)
37. Oriek, D.; Ohaeri, O.C.; Ijeh, I.I.; Ijioma, S.N. Gastrointestinal and uterine smooth muscles relaxant and anti-inflammatory effects of *Corchorus olitorius* leaf extract in laboratory animal models. *J. Ethnopharmacol.* **2020**, *247*, 112224. [\[CrossRef\]](#)
38. Xiong, C.; Li, Q.; Li, S.; Chen, C.; Chen, Z.; Huang, W. In vitro antimicrobial activities and mechanism of 1-octen-3-ol against food-related bacteria and pathogenic fungi. *J. Oleo Sci.* **2017**, *66*, 1041–1049. [\[CrossRef\]](#) [\[PubMed\]](#)
39. Zhang, J.H.; Sun, H.L.; Chen, S.Y.; Zeng, L.; Wang, T.T. Anti-fungal activity, mechanism studies on  $\alpha$ -phellandrene and nonanal against *Penicillium cyclopium*. *Bot. Stud.* **2017**, *58*, 13. [\[CrossRef\]](#)
40. Li, Q.; Zhu, X.; Xie, Y.; Liang, J. Antifungal properties and mechanisms of three volatile aldehydes (octanal, nonanal and decanal) on *Aspergillus flavus*. *Grain Oil Sci. Technol.* **2021**, *4*, 131–140. [\[CrossRef\]](#)
41. Paparella, A.; Shaltiel-Harpaza, L.; Ibdah, M.  $\beta$ -Ionone: Its occurrence and biological function and metabolic engineering. *Plants* **2021**, *10*, 754. [\[CrossRef\]](#)
42. De Moraes, J.; de Oliveira, R.N.; Costa, J.P.; Junior, A.L.; de Sousa, D.P.; Freitas, R.M.; Allegretti, S.M.; Pinto, P.L. Phytol, a diterpene alcohol from chlorophyll, as a drug against neglected tropical disease *Schistosomiasis mansoni*. *PLoS Negl. Trop. Dis.* **2014**, *8*, e2617. [\[CrossRef\]](#)
43. Jung, Y.Y.; Hwang, S.T.; Sethi, G.; Fan, L.; Arfuso, F.; Ahn, K.S. Potential anti-inflammatory and anti-cancer properties of farnesol. *Molecules* **2018**, *23*, 2827. [\[CrossRef\]](#)
44. Kim, S.K.; Karadeniz, F. Biological importance and applications of squalene and squalane. *Adv. Food Nutr. Res.* **2012**, *65*, 223–233. [\[CrossRef\]](#)
45. Ugbogu, E.A.; Nwoku, C.D.; Ude, V.C.; Emmanuel, O. Evaluating bioactive constituents and toxicological effect of aqueous extract of fermented *Pentaclethra macrophylla* seeds in rats. *Avicenna J. Phytomed.* **2020**, *10*, 101–113.
46. Bello, I.; Bakkouri, A.S.; Tabana, Y.M.; Al-Hindi, B.; Al-Mansoub, M.A.; Mahmud, R.; Asmawi, M.Z. Acute and sub-acute toxicity evaluation of the methanolic extract of *Alstonia scholaris* stem bark. *Med. Sci.* **2016**, *4*, 4. [\[CrossRef\]](#)
47. Teo, S.; Stirling, D.; Thomas, S.; Hoberman, A.; Kiorpes, A.; Khetani, V. A 90-day oral gavage toxicity study of D-methylphenidate and D, L-methylphenidate in Sprague-Dawley rats. *Toxicology* **2002**, *179*, 183–196. [\[CrossRef\]](#)
48. Michael, B.; Yano, B.; Sellers, R.S.; Perry, R.; Morton, D.; Roome, N.; Johnson, J.K.; Schafer, K.; Pitsch, S. Evaluation of organ weights for rodent and non-rodent toxicity studies: A review of regulatory guidelines and a survey of current practices. *Toxicol. Pathol.* **2007**, *35*, 742–750. [\[CrossRef\]](#) [\[PubMed\]](#)
49. James, R.W. The relevance of clinical pathology to toxicology studies. *Comp. Haematol. Int.* **1993**, *3*, 190–195. [\[CrossRef\]](#)
50. Emmanuel, O.; Okezie, U.M.; Iweala, E.J.; Ugbogu, E.A. Pretreatment of red palm oil extracted from palm fruit (*Elaeis guineensis*) attenuates carbon tetrachloride induced toxicity in Wistar rats. *Phytomed. Plus* **2021**, *1*, 100079. [\[CrossRef\]](#)
51. Nagata, S.; Nagase, H.; Kawane, K.; Mukae, N.; Fukuyama, H. Degradation of chromosomal DNA during apoptosis. *Cell Death Differ.* **2003**, *10*, 108–116. [\[CrossRef\]](#)
52. Auti, S.; Kulkarni, Y. Acute and 28-day repeated dose oral toxicity study of caraway oil in rats. *Drug Metab. Pers. Ther.* **2019**, *34*, 20190011. [\[CrossRef\]](#)



53. Thounaojam, M.C.; Jadeja, R.N.; Sankhari, J.M.; Devkar, R.V.; Ramachandran, A.V. Safety evaluations on ethanolic extract of red cabbage (*Brassica oleracea* L.) in mice. *J. Food Sci.* **2011**, *76*, 35–39. [\[CrossRef\]](#)
54. Mukinda, J.T.; Syce, J.A. Acute and chronic toxicity of the aqueous extract of *Artemisia afra* in rodents. *J. Ethnopharmacol.* **2007**, *112*, 138–144. [\[CrossRef\]](#)
55. Ismail, M.D.; Hossain-Faruk, M.D.; Tanu, R.A.; Shekhar, H.U. Effect of spirulina intervention on oxidative stress, antioxidant status, and lipid profile in chronic obstructive pulmonary disease patients. *Biomed. Res. Int.* **2015**, *2015*, 486120. [\[CrossRef\]](#) [\[PubMed\]](#)
56. Buffone, M.G.; Verstraeten, S.V.; Calamera, J.C.; Doncel, G.F. High cholesterol content and decreased membrane fluidity in human spermatozoa are associated with protein tyrosine phosphorylation and functional deficiencies. *J. Androl.* **2009**, *30*, 552–558. [\[CrossRef\]](#) [\[PubMed\]](#)
57. Erukainure, O.L.; Ajiboye, J.A.; Adejobi, R.O.; Okafor, O.Y.; Kosoko, S.B.; Owolabi, F.O. Effect of pineapple peel extract on total phospholipids and lipid peroxidation in brain tissues of rats. *Asian Pac. J. Trop. Med.* **2011**, *4*, 182–184. [\[CrossRef\]](#)
58. Onyema, O.O.; Farombi, E.O.; Emerole, G.O.; Ukoha, A.I.; Onyeze, G.O. Effect of vitamin E on monosodium glutamate induced hepatotoxicity and oxidative stress in rats. *Indian J. Biochem. Biophys.* **2005**, *43*, 20–24.
59. Okafor, O.Y.; Erukainure, O.L.; Ajiboye, J.A.; Adejobi, R.O.; Owolabi, F.O.; Kosoko, S.B. Pineapple peel extract modulates lipid peroxidation, catalase activity and hepatic biomarker levels in blood plasma of alcohol-induced oxidative stressed rats. *Asian Pac. J. Trop. Biomed.* **2011**, *1*, 12–14. [\[CrossRef\]](#)
60. Nigam, S.; Schewe, T. Phospholipase A2s and lipid peroxidation. *Biochimica Biophysica Acta* **2000**, *1488*, 167–181. [\[CrossRef\]](#)
61. Okereke, G.; Emmanuel, O.; Ude, V.C.; Ekweogu, C.N.; Ikpeazu, V.O.; Ugbogu, E.A. Physicochemical characteristics, acute and subacute toxicity of cashew nut shell oil in Wistar rats. *Sci. Afr.* **2020**, *8*, e00391. [\[CrossRef\]](#)
62. Nkosi, C.Z.; Opoku, A.R.; Terblanche, S.E. Antioxidative effects of pumpkin seed (*Cucurbita pepo*) protein isolate in CCl<sub>4</sub>-induced liver injury in low-protein fed rats. *Phytother. Res.* **2006**, *20*, 935–940. [\[CrossRef\]](#)
63. Lynn, S.; Gurr, J.R.; Lai, H.T.; Jan, K.Y. NADH oxidase activation is involved in arsenite-induced oxidative DNA damage in human vascular smooth muscle cells. *Circ. Res.* **2000**, *86*, 514–519. [\[CrossRef\]](#)
64. Chitra, S.; Patil, M.B.; Ravi, K. Wound healing activity of *Hyptis suaveolens* (L.) poit (Lamiaceae). *Int. J. Pharmtech. Res.* **2009**, *1*, 737–744.
65. Ayyanar, M.; Ignacimuthu, S. Herbal medicines for wound healing among tribal people in Southern India: Ethnobotanical and scientific evidences. *Int. J. Appl. Res. Nat. Prod.* **2009**, *2*, 29–42.
66. Wild, T.; Rahbarnia, A.; Kellner, M.; Sobotka, L.; Eberlein, T. Basics in nutrition and wound healing. *Nutrition* **2010**, *26*, 862–866. [\[CrossRef\]](#) [\[PubMed\]](#)
67. Frangez, I.; Cankar, K.; Frangez, H.B.; Smrke, D.M. The effect of LED on blood microcirculation during chronic wound healing in diabetic and on diabetic patients—a prospective, double-blind randomized study. *Lasers Med. Sci.* **2017**, *32*, 887–894. [\[CrossRef\]](#)
68. Ozay, Y.; Guzel, S.; Erdogan, I.H.; Yildirim, Z.; Pehlivanoglu, B.; Aydın Turk, B.; Darcan, S. Evaluation of the wound healing properties of luteolin ointments on excision and incision wound models in diabetic and non-diabetic rats. *Records Nat. Prod.* **2018**, *12*, 350–366. [\[CrossRef\]](#)
69. Ananth, K.; Asad, M.; Kumar, N.P.; Asdaq, M.B.; Rao, G.S. Evaluation of wound healing potential of *Bauhinia purpurea* leaf extracts in rats. *Indian J. Pharm. Sci.* **2010**, *72*, 122–127.
70. Siwik, D.A.; Pagano, P.J.; Colucci, W.S. Oxidative stress regulates collagen synthesis and matrix metalloproteinase activity in cardiac fibroblasts. *Am. J. Physiol.* **2001**, *280*, 53–60. [\[CrossRef\]](#)
71. Rodriguez, P.G.; Felix, F.N.; Woodley, D.T.; Shim, E.K. The role of oxygen in wound healing: A review of the literature. *Dermatol. Surg.* **2008**, *34*, 1159–1169. [\[CrossRef\]](#) [\[PubMed\]](#)
72. Boakye, Y.D.; Agyare, C.; Hensel, A. Anti-infective properties and time-kill kinetics of *Phyllanthus muellerianus* and its major constituent, geraniin. *Med. Chem.* **2016**, *6*, 95–104. [\[CrossRef\]](#)
73. Akindele, J.A.; Oladimeji-Salami, J.A.; Usuwah, B.A. Antinociceptive and anti-inflammatory activities of *Telfairia occidentalis* hydroethanolic leaf extract (Cucurbitaceae). *J. Med. Food* **2015**, *18*, 1157–1163. [\[CrossRef\]](#)