

## Case Report

# Pilot Study of Microfocused Ultrasound, Incobotulinum Toxin, and Calcium Hydroxyapatite in Triple Therapy for Skin Tightening after Weight Loss

Lisa Kwin Wah Chan , Kar Wai Alvin Lee  and Cheuk Hung Lee 

Ever Keen Medical Centre, Hong Kong, China; alvin429@yahoo.com (K.W.A.L.); andylee618@hotmail.com (C.H.L.)

\* Correspondence: lisa827@gmail.com

**Abstract:** Background: After significant weight loss, the abdominal skin can become permanently stretched, resulting in stretch marks, laxity, and thinning of the dermis. For many patients, surgical methods such as abdominoplasty are too risky due to the potential for complications, the lengthy recovery period, and the high cost. Objective: The purpose of this pilot study was to use microfocused ultrasound, calcium hydroxyapatite, and Incobotulinum toxin A to improve the appearance of patients who were suffering from abdominal skin laxity after heavy weight loss. The combination of these treatments can provide comprehensive results with minimal downtime and lower risk compared to traditional surgical procedures. Methods: Our team treated four female Chinese patients with microfocused ultrasound, diluted calcium hydroxylapatite, and Incobotulinum toxin A with different combinations, respectively. The first and second cases were only treated with 810 shots of microfocused ultrasound. The third case received 850 shots of microfocused ultrasound plus 5 mL of diluted calcium hydroxylapatite and 50 units of Incobotulinum toxin A on the left abdominal skin, and the fourth case was treated with 900 shots of microfocused ultrasound plus 5 mL of diluted calcium hydroxylapatite and 10 units of Incobotulinum toxin A on the left abdominal skin. All four patients received a single treatment session. Clinical photographs were taken before each treatment, and two individual blinded investigators were asked to assess photographs taken after 4 weeks and compare them with the pretreatment photos. Results: All four cases showed an overall clinical improvement, with the third and fourth cases demonstrating more significant skin tightening based on photographic analysis. The data indicate that the inclusion of calcium hydroxylapatite and Incobotulinum toxin A in microfocused ultrasound treatment yields superior results for abdominal rejuvenation. Conclusions: Abdominal skin laxity can be treated with a triple therapy combining microfocused ultrasound, diluted calcium hydroxylapatite, and Incobotulinum toxin A.

**Keywords:** ultrasonic therapy; calcium hydroxyapatite; botulinum toxins; abdominoplasty; cosmetic techniques; minimally invasive surgical procedures



**Citation:** Chan, L.K.W.; Lee, K.W.A.; Lee, C.H. Pilot Study of Microfocused Ultrasound, Incobotulinum Toxin, and Calcium Hydroxyapatite in Triple Therapy for Skin Tightening after Weight Loss. *Cosmetics* **2023**, *10*, 168. <https://doi.org/10.3390/cosmetics10060168>

Academic Editors: Danuta Nowicka and Sekyoo Jeong

Received: 1 November 2023

Revised: 23 November 2023

Accepted: 7 December 2023

Published: 11 December 2023



**Copyright:** © 2023 by the authors. Licensee MDPI, Basel, Switzerland. This article is an open access article distributed under the terms and conditions of the Creative Commons Attribution (CC BY) license (<https://creativecommons.org/licenses/by/4.0/>).

## 1. Introduction

As people age, changes occur in the skin's elasticity, causing sagging and laxity in various parts of the body, including the abdomen. Loose abdominal skin can be caused by severe diet control, the heavy scale of exercises, pregnancy, weight fluctuations, and other factors, which can make people self-conscious about their appearance [1]. Fortunately, there are noninvasive and minimally invasive options available to improve the appearance of loose abdominal skin, such as using microfocused ultrasound [2], calcium hydroxyapatite [3], and botulinum toxin (which is mainly used on neck skin laxity, with the technique of microbotox) [4].

Microfocused ultrasound is an innovative treatment that has shown promising results in reducing abdominal weight loss skin laxity. This non-invasive procedure utilizes focused ultrasound energy to specifically target loose skin and underlying tissues in the abdominal area. Calcium hydroxyapatite is a filler material commonly used for cosmetic procedures such as wrinkle reduction and skin rejuvenation. However, it is also becoming a popular option for reducing abdominal skin laxity. Incobotulinum toxin A (IncoBTX-A) is a type of neurotoxin that is commonly used for cosmetic purposes such as wrinkle reduction and skin rejuvenation. It has been found to offer promising benefits in the treatment of neck skin laxity [5]. Our team found that injecting small dispersed doses of botulinum toxin in the abdominal skin can achieve good cosmetic results together with other modalities of treatment.

## 2. Material and Methods

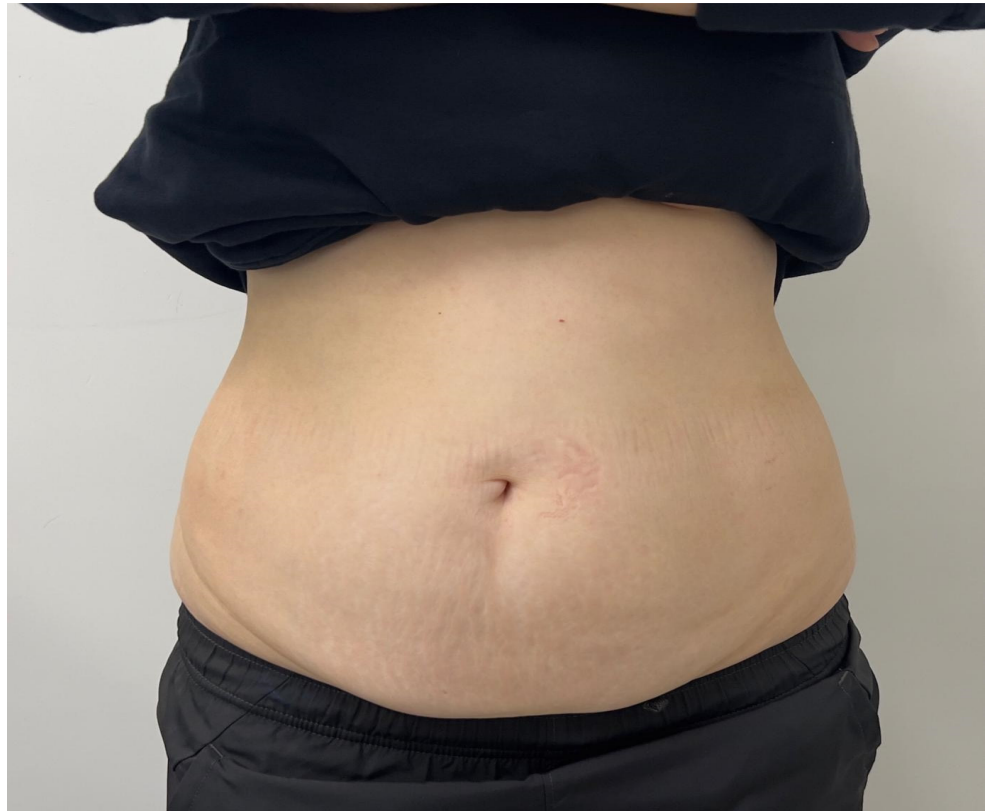We studied four cases of abdominal skin loosening. The first and second cases were only treated with 810 shots of microfocused ultrasound. The third case received 850 shots of microfocused ultrasound plus 5 mL of diluted calcium hydroxylapatite (CaHA) and 50 units of Incobotulinum toxin A (IncoBTX-A) on the left abdominal skin, and the fourth case was treated with 900 shots of microfocused ultrasound plus 5 mL of diluted calcium hydroxylapatite (CaHA) and 100 units of Incobotulinum toxin A (IncoBTX-A) on the left abdominal skin. All four patients received a single treatment session. Clinical photographs were taken before each treatment, and two individual blinded investigators were asked to assess photographs taken after 4 weeks and compare them with the pretreatment photos. Patients were specifically asked to provide their own perceptions of any changes they observed in their skin quality and the degree of abdominal skin sagging following the treatment.

## 3. Case 1

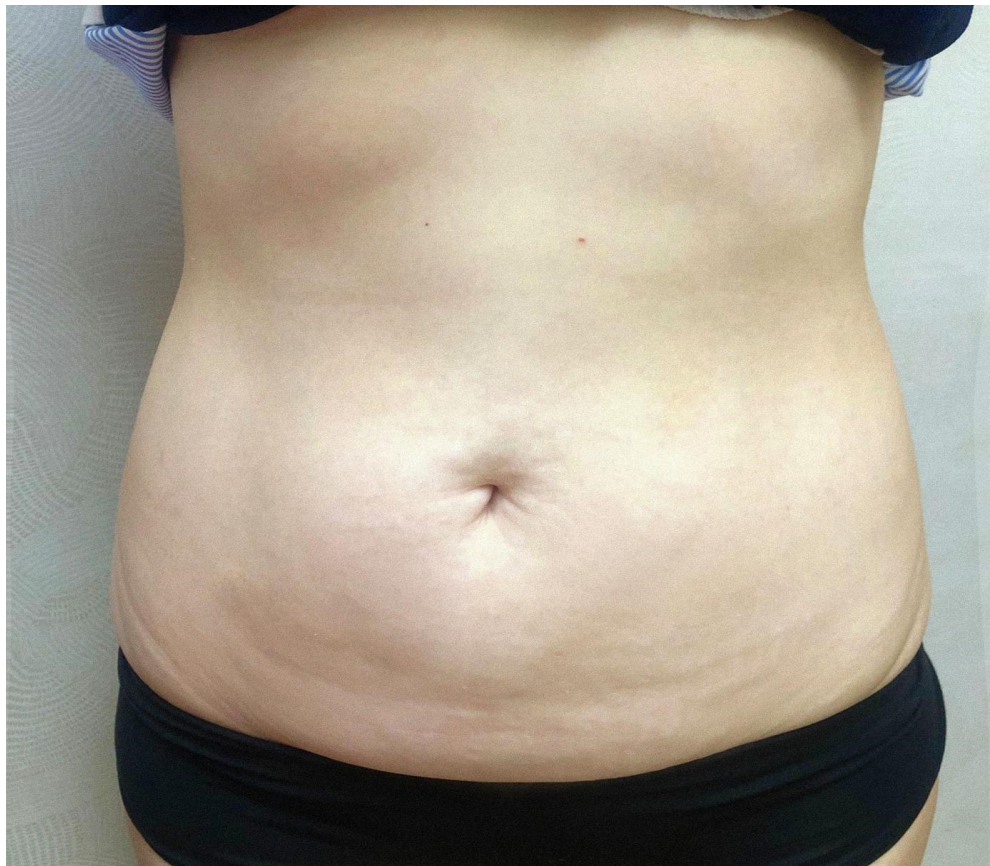
Case 1 was a 50-year-old Chinese female teacher who lost weight from 60 kg to 49 kg in 2 years. She presented with recurrent rashes, skin irritation, and discomfort in the abdominal region due to excess skin. Because of the pouch-like appearance of the lower abdomen, which hung down over the pubic area, she struggled to find clothing that fit well and flattered her figure due to the presence of the skin laxity of her abdomen. She also felt self-conscious and avoided intimate engagements with her husband because of her poor self-image.

Upon physical examination, the patient presented with an apron-like pattern of excess skin folds that wrapped around the lower abdomen. The loose skin made the skin folds appear heavy but had no underlying subcutaneous adiposity (Figure 1).

After doing 810 shots of focused ultrasound, the patient reported a gentle yet meaningful improvement in the sagging of her abdomen. improvement in self-esteem and overall physical comfort. She was able to comfortably perform activities and without the embarrassment of excess skin folds (Figure 2). The procedure allowed the patient to achieve a natural-looking appearance that significantly increased her self-confidence and overall satisfaction with her body image. The gentle enhancement, though not dramatic, contributed to a remarkable boost in her self-confidence and a catalyst for a surge in her self-assurance.



**Figure 1.** Case 1, Microfocused Ultrasound 810 shots only (before treatment).



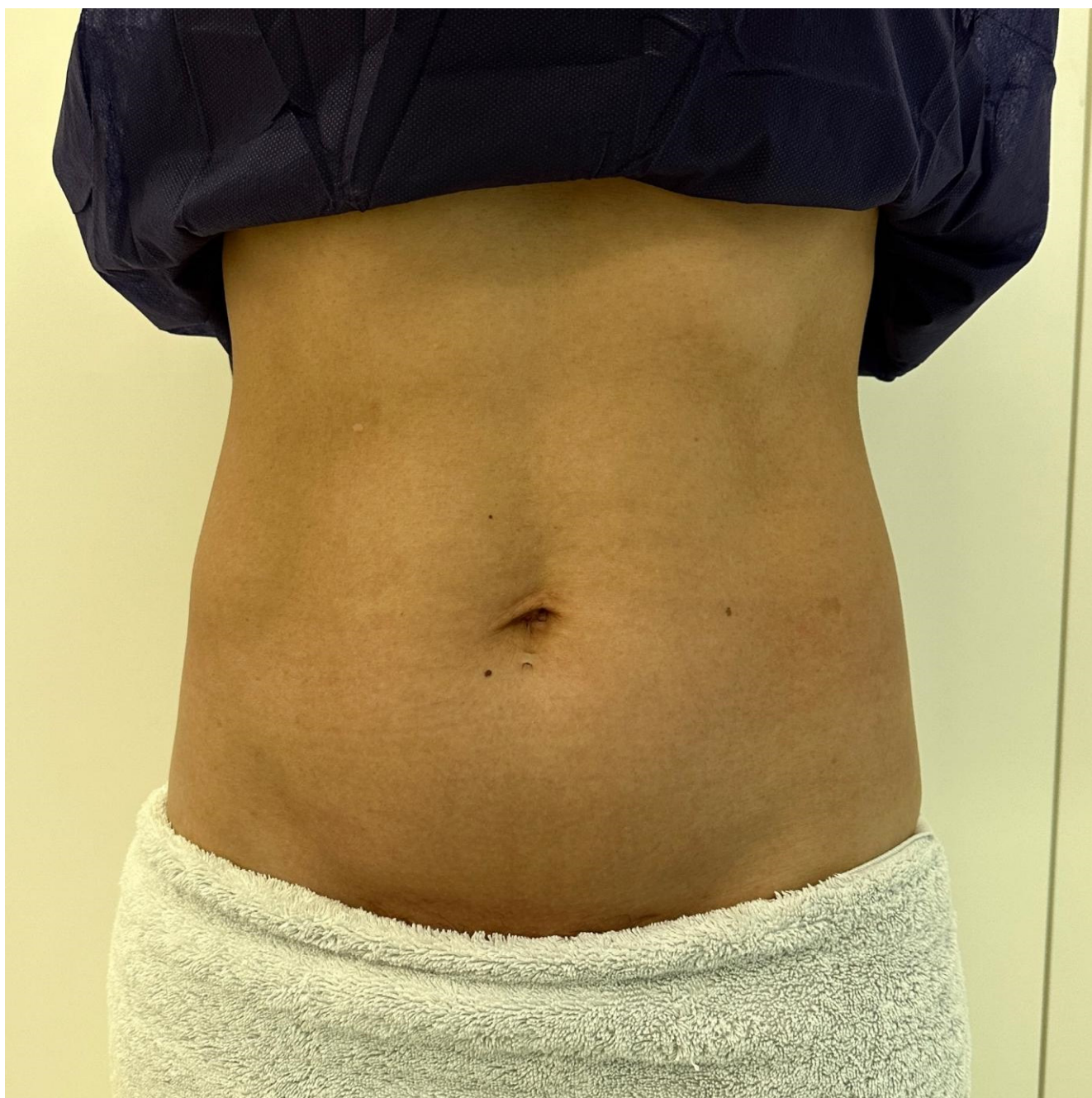
**Figure 2.** Case 1, Microfocused Ultrasound 810 shots only (4 weeks after treatment).



#### 4. Case 2

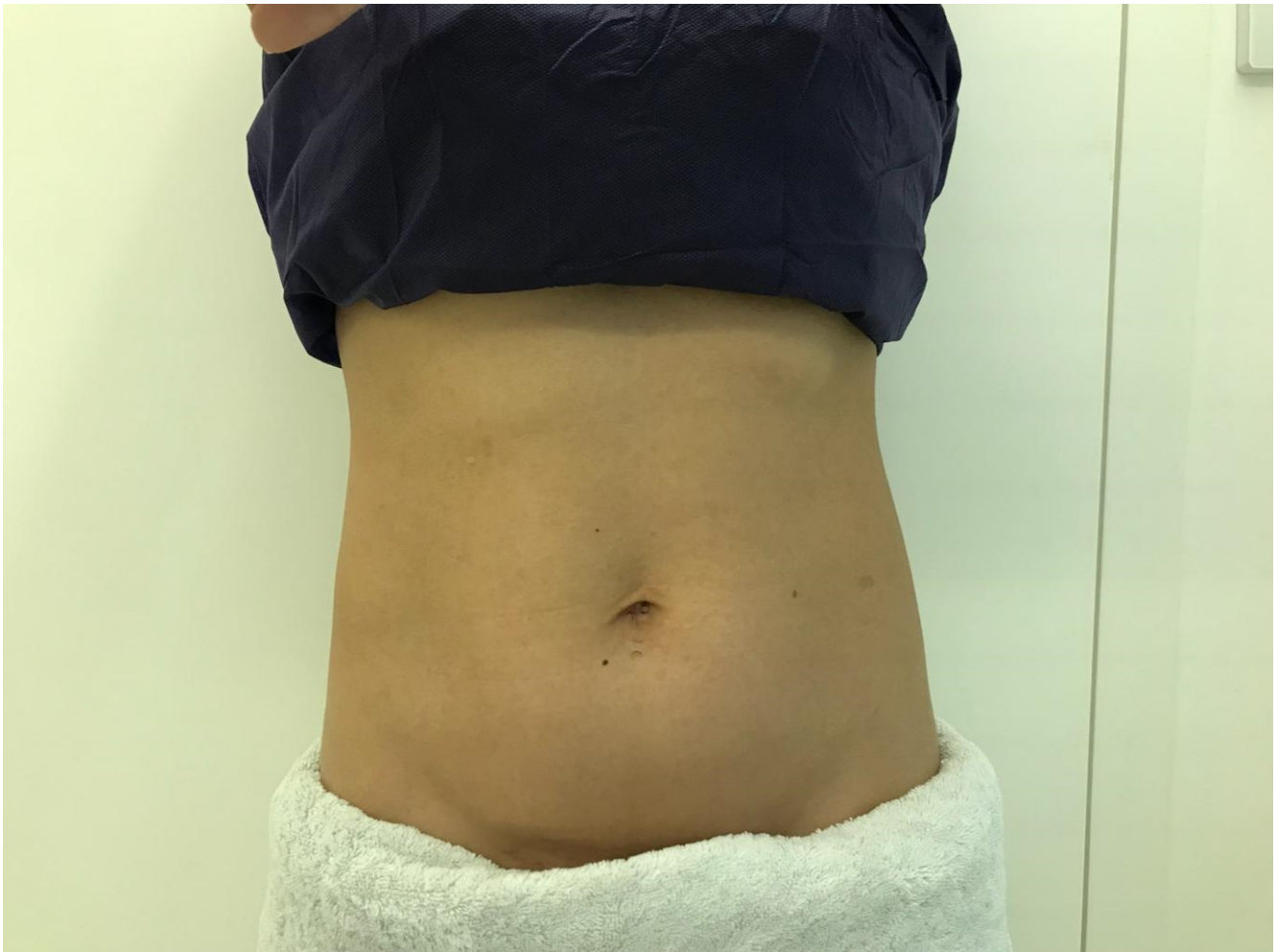
Case 2 was a 48-year-old female Chinese lawyer who decreased her weight from 73 kg to 49.5 kg in 20 years. Following substantial weight loss, she noticed the presence of loose and sagging skin in her abdominal area, resulting in a loss of the firmness that was once present. Consequently, she actively avoided wearing cropped tops due to self-consciousness.

During the physical examination, visible fine lines and irregular contours were observed in the abdominal region, although the presence of striae was not significant (Figure 3). Subsequently, the patient underwent Microfocused Ultrasound treatment consisting of 810 shots.



**Figure 3.** Case 2, Microfocused Ultrasound 810 shots only (before treatment).

Post treatment, the patient reported an improvement in skin quality and smoothness within the abdominal region (Figure 4), leading to an enhanced level of self-confidence. The Microfocused Ultrasound treatment played a role in addressing the concerns related to loose and sagging skin, thus contributing to the patient's positive subjective experience and overall satisfaction with the outcome.



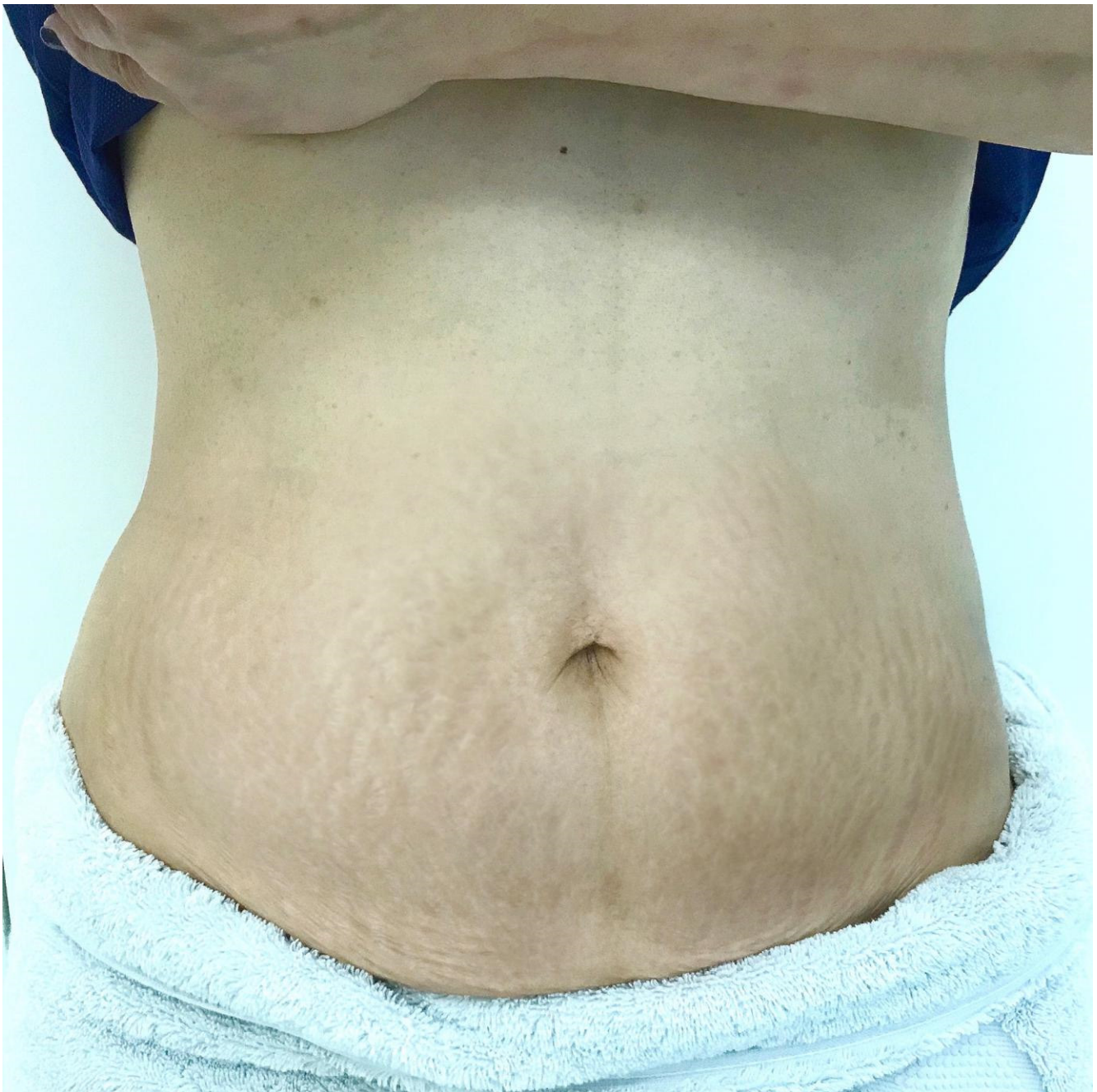
**Figure 4.** Case 2, Microfocused Ultrasound 810 shots only (4 weeks after treatment).

### 5. Case 3

Case 3 was a 58-year-old Chinese female Uber driver who presented with severe abdominal skin laxity for 20 years after heavy weight loss from 60 kg to 50 kg at the age of 38. She never managed her abdominal skin situation and never showed her tummy to anyone including her husband. She also presented with a dysfunctional body image due to remaining skin folds around the abdomen, back pain, and discomfort during daily activities. She was non-smoker and non-drinker, with good past health.

Physical examination showed circumferential excess skin folds encircling the whole abdomen region, appearing like a “panniculus”, a lower-abdominal apron of tissue that hangs over the pubic area (Figure 5). This made her hesitant to wear a swimming suit due to her negative body image and perceived imperfections. She consistently declined invitations to pool parties and always wore loose-fitting or tummy-control clothing that hid her abdomen, even in situations where swimwear was expected.



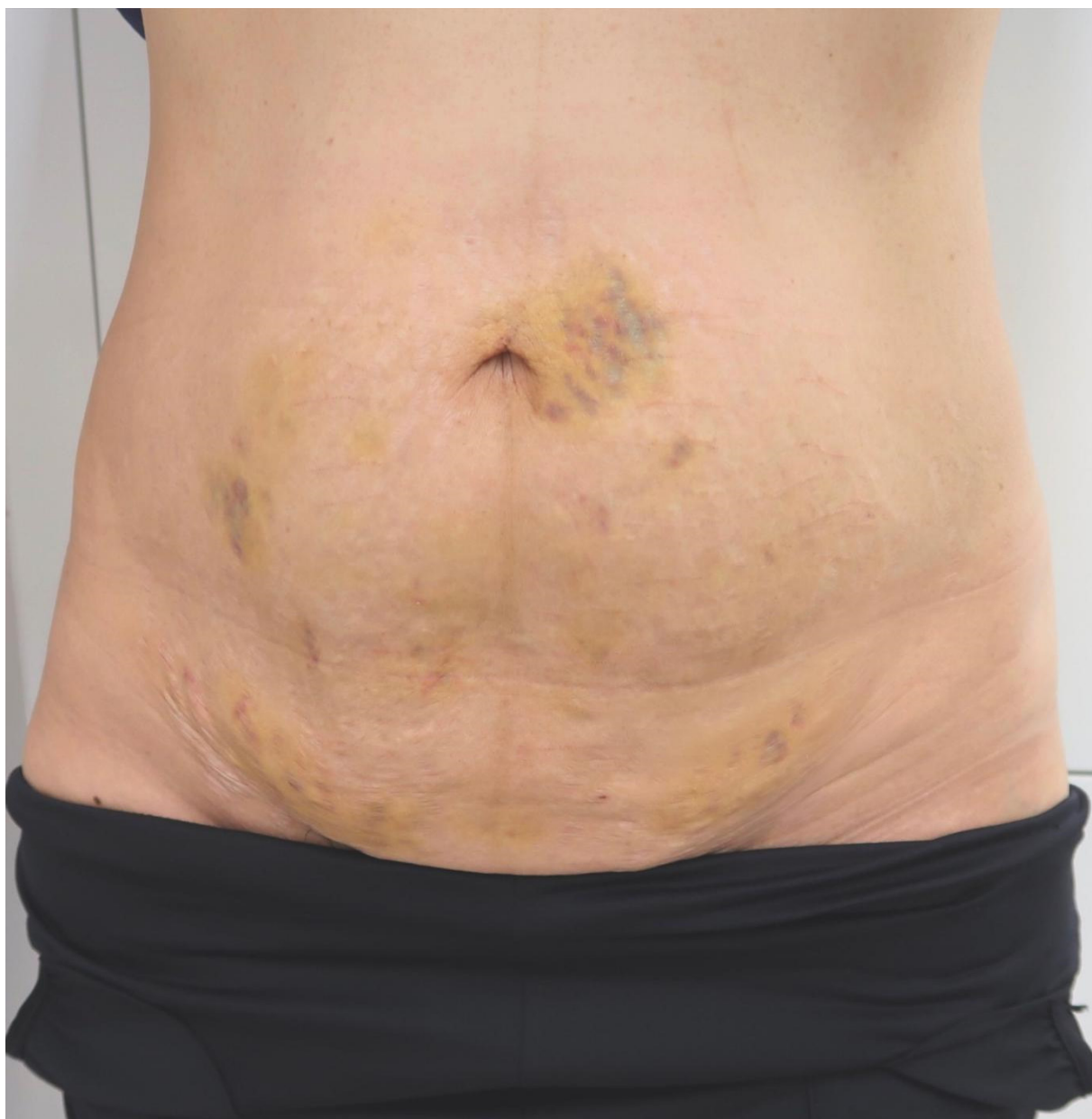


**Figure 5.** Case 3, Microfocused Ultrasound 850 shots + 5 mL diluted CaHA + 50 U IncoBTX-A to the left side of abdomen only (pretreatment).

After undergoing a comprehensive treatment regimen consisting of microfocused ultrasound with 850 shots, 5 mL of calcium hydroxylapatite (CaHA) diluted with a 1:1 ratio of normal saline and injected on both sides of her abdomen, and 50 units of IncoBTX-A exclusively administered to the left side of her abdomen for the purpose of comparing the results, the patient experienced notable improvements in her abdominal appearance (Figures 6 and 7). Particularly, the addition of IncoBTX-A to the left side of her abdomen yielded more significant enhancements compared to previous cases, and the inclusion of CaHA further augmented the overall outcome.

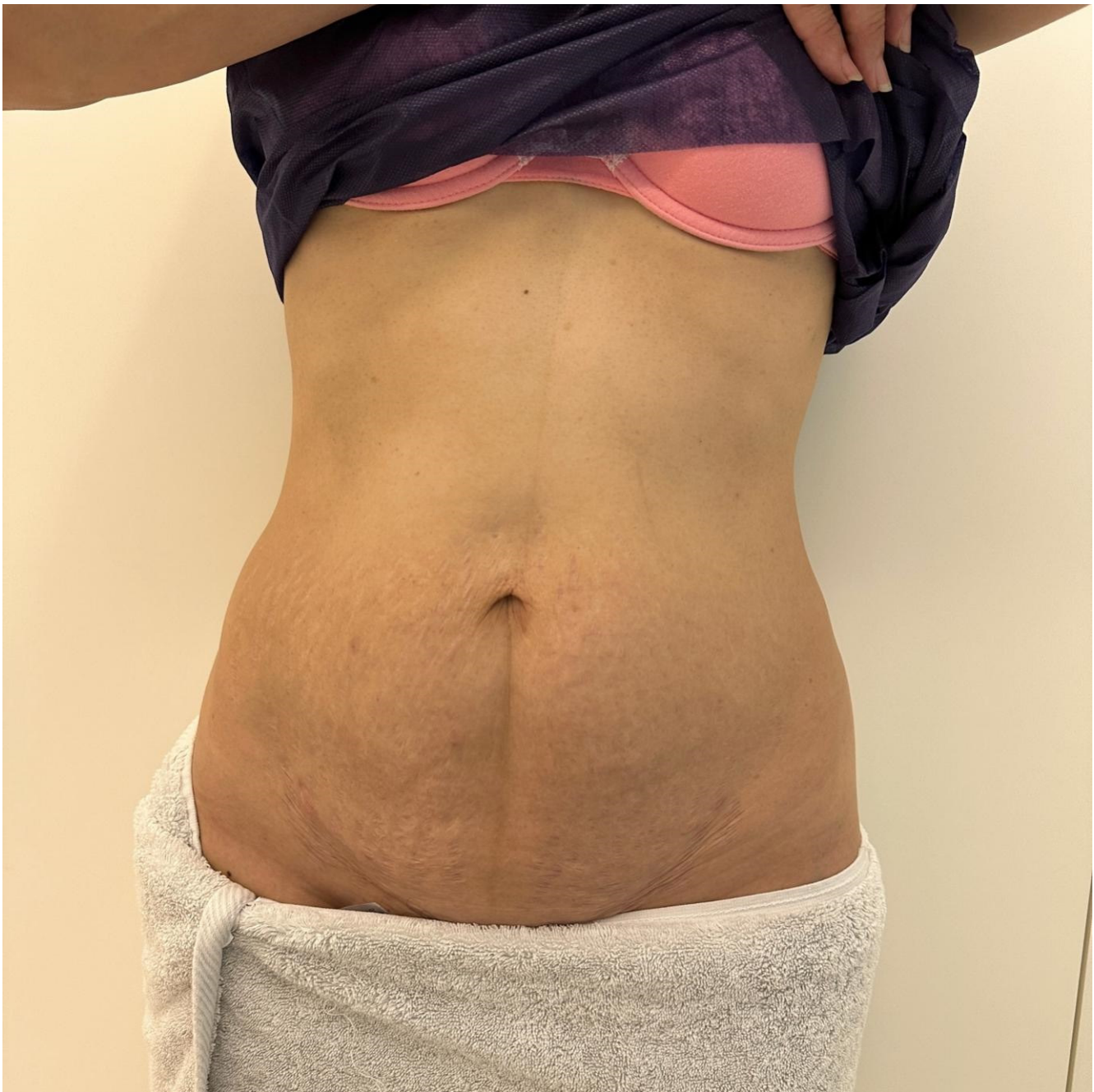
The patient reported increased satisfaction with the appearance of her abdomen, although she still felt some residual discomfort preventing her from being completely at ease wearing a swimsuit. Nevertheless, she expressed a willingness to undergo additional treatment sessions in the future and remained hopeful about her ongoing progress.

Post-treatment photo (after 1 week)



**Figure 6.** Case 3, Microfocused Ultrasound 850 shots + 5 mL diluted CaHA + 50 U IncoBTX-A to the left side of abdomen only (1 week after treatment).





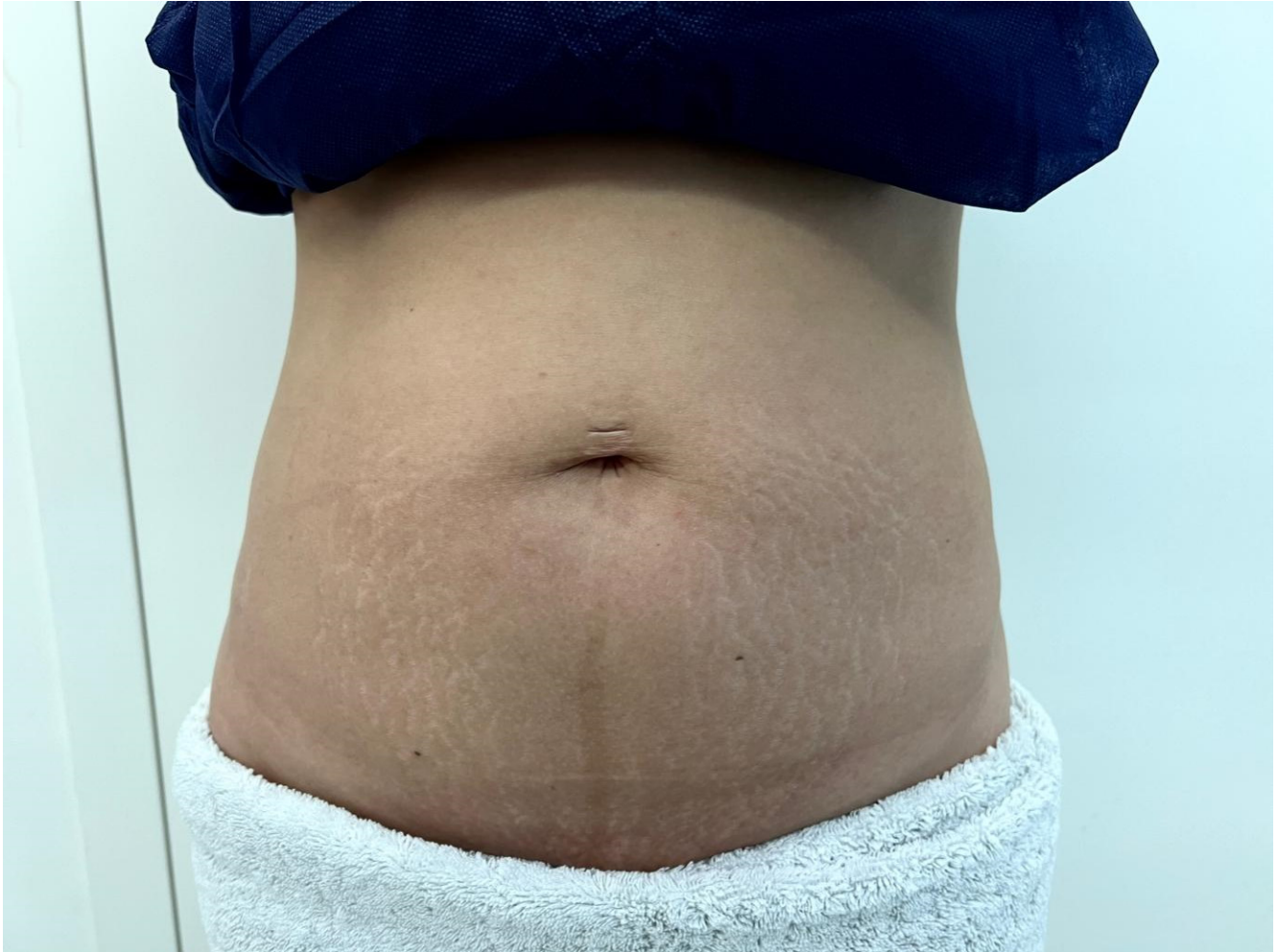**Figure 7.** Case 3, Microfocused Ultrasound 850 shots + 5 mL diluted CaHA + 50 U IncoBTX-A to the left side of abdomen only (4 weeks after treatment).

#### 6. Case 4

Case 4 involved a 42-year-old Chinese female beauty therapist who presented with a significant amount of excess skin around her abdomen for a duration of three years. This condition arose following a notable weight reduction from 60 kg to 41 kg within a three-month period after giving birth. The patient experienced discomfort during physical movement and activities, as well as challenges in finding clothing that could properly fit and conceal the laxity of her skin. As someone who was image-conscious, the embarrassment caused by the abdominal strain and loosening was particularly pronounced. This situation was further compounded by recurrent rashes in the folds and occasional itching, which added to her discomfort. It is important to note that she had a non-smoking, non-drinking history and a generally good state of health.

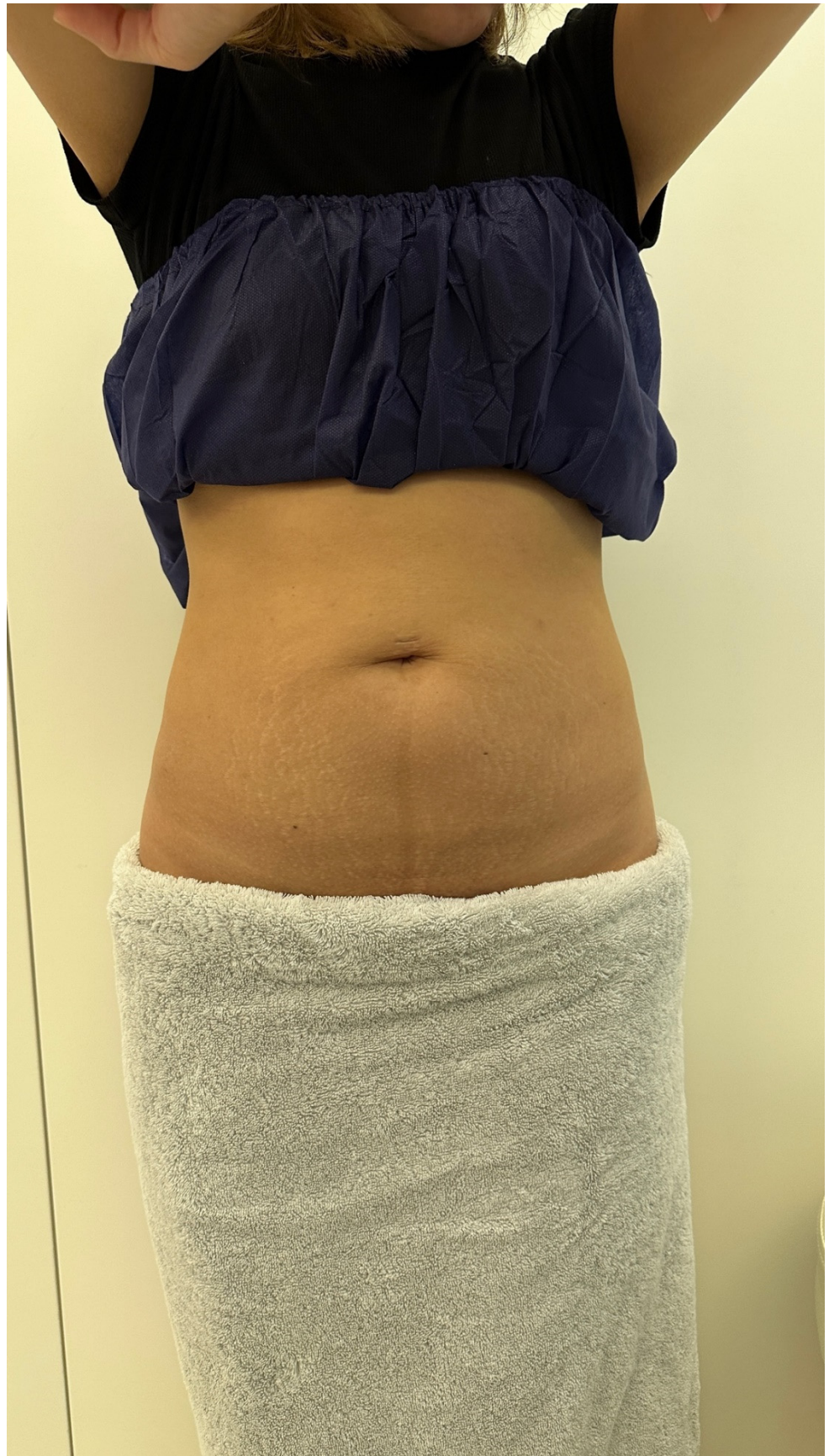


Upon physical examination, visible loose skin folds with prominent striae in the abdomen region were observed, underscoring the extent of her condition (Figure 8). To address her concerns, a comprehensive treatment plan was devised. This included performing Microfocused Ultrasound with 900 shots on both sides of her abdomen, administering 5 mL of diluted CaHA to both sides of her abdomen, and injecting 100 units of IncoBTX-A exclusively on the left side of her abdomen.



**Figure 8.** Case 4, Microfocused Ultrasound 900 shots + 5 mL diluted CaHA + 100 U IncoBTX-A to the left side of abdomen only (pretreatment).

As a result of the treatment, the patient's abdomen exhibited a more toned and natural-looking appearance, characterized by aesthetically pleasing abdominal contours (Figure 9). The marked improvement was especially noticeable on the left side of her abdomen, surpassing the results achieved in Case 3. However, it is important to mention that the extent of this improvement was not adequately captured in the photos taken, and this limitation will be further discussed in the paper's subsequent sections.



**Figure 9.** Case 4, Microfocused Ultrasound 900 shots + 5 mL diluted CaHA + 100 U IncoBTX-A to the left side of abdomen only (4 weeks after treatment).

## 7. Results

All four cases exhibited an overall clinical improvement. The third and fourth cases showed more pronounced skin tightening compared to cases 1 and 2. The data, as evidenced by both photographs and subjective patient feedback, indicates that the inclusion of CaHA and Incobotulinum toxin A (IncoBTX-A) in microfocused ultrasound treatment yields superior results for abdominal rejuvenation. While the level of improvement in the abdominal skin sagging condition did not significantly differ between the third and fourth cases, the visual superiority of the left side of the abdomen, where IncoBTX-A was administered, compared to the untreated right side in both cases, provided evidence of the positive contribution of IncoBTX-A.

## 8. Discussion

Severe active weight loss through strict diet control and heavy exercises result in complex changes to a woman's body; loose abdominal skin appears as connective tissue fibers of collagen and elastin stretch.

The demand for noninvasive esthetic procedures for skin tightening has increased. Technologies other than microfocused ultrasound, calcium hydroxyapatite, and botulinum toxins, such as radiofrequency (RF) [6–10], high-intensity focused ultrasound (HIFU) [11,12], laser [13], and pressure energy devices, which have been discussed in previous studies, improve the aesthetic appearance and self-confidence of patients. Nevertheless, while there have been studies combining microfocused ultrasound and calcium hydroxyapatite to treat abdominal skin laxity, there has never been any research combining microfocused ultrasound, calcium hydroxyapatite, and botulinum toxin to treat abdominal skin laxity.

### 8.1. Microfocused Ultrasound

The procedure works by delivering controlled bursts of ultrasound waves to the targeted area, which penetrate deep into the skin and stimulate collagen production, resulting in skin tightening and improved elasticity. The heat generated by the ultrasound waves effectively triggers the body's natural regenerative response, leading to firmer and more toned skin.

What sets microfocused ultrasound apart is its ability to precisely target the area of concern without causing harm to the surrounding tissues. This makes it a safe and effective option for individuals looking to improve the appearance of their abdominal region after weight loss.

Patients undergoing microfocused ultrasound for abdominal skin laxity can expect minimal discomfort during the procedure, with no downtime required afterward. Multiple treatment sessions may be recommended to achieve optimal results, depending on the severity of the laxity [2]. It is important to note that microfocused ultrasound is not a weight loss treatment itself but rather a procedure designed to address skin laxity. Therefore, individuals seeking significant weight loss should explore appropriate diet and exercise plans before considering skin tightening procedures.

### 8.2. Calcium Hydroxyapatite

The use of calcium hydroxyapatite for skin tightening purposes works by stimulating collagen production. As we age or lose weight, our skin tends to lose collagen, which leads to skin laxity. Calcium hydroxyapatite injections stimulate the production of new collagen, which fills up the sagging skin and tightens it, helping to achieve a firmer and more toned abdominal appearance.

The procedure involves injecting the calcium hydroxyapatite directly into the affected area, after which the body responds by producing more collagen in the injected area. This method also has the added benefit of providing an immediate visible improvement, with the full effects of the treatment slowly becoming more visible over time [14].



Calcium hydroxyapatite is also known for its longevity, lasting up to a year or more in some cases. This means that the patient can enjoy the benefits of the procedure for an extended period before requiring follow-up treatments.

While calcium hydroxyapatite injections are considered safe, it is important to note that the procedure is not for everyone. Patients who are allergic to calcium, have bleeding disorders, or are taking blood-thinning medications should not undergo this treatment.

### 8.3. *Incobotulinum Toxin A (IncoBTX-A)*

The main skin laxity area using botulinum toxin is the neck area [5,15]. For improving abdominal skin laxity and skin quality, it involves injecting IncoBTX-A directly intradermally into the affected area. Park et al. [16] proposed that following the intradermal injection of botulinum toxin treatment, the patterns of change for dynamic wrinkles and skin quality are not the same. The two are different in that the former has a quick onset and brief duration while the latter has a slow onset but prolonged duration, demonstrating that the fundamental mechanisms for minimizing dynamic wrinkles and enhancing skin laxity are different. By creating an irreversible link with the synaptic membrane and obstructing the neuronal pulse, botulinum toxin paralyzes the face muscles. The rapid onset is due to the neuronal transmission being inhibited as soon as the previously stored acetylcholine has been eliminated. Botulinum toxin, however, primarily affects skin quality through nonneuronal cholinergic mechanisms, including neuroendocrine activity and ensuing metabolic reactions. While it can move slowly at first, the process ultimately takes longer.

IncoBTX-A has the advantage of being minimally invasive, with minimal discomfort and no downtime required. Patients can typically resume their normal activities immediately following treatment. The results of IncoBTX-A treatment can last for several months, depending on the individual's metabolism.

IncoBTX-A is generally considered safe when administered by a qualified healthcare professional. However, as with any medical treatment, there is always a risk of adverse reactions, so it is important to discuss potential risks and benefits with a healthcare provider before undergoing the procedure [17].

In consideration of its reduced likelihood of causing immune responses, we opted to utilize IncoBTX-A. Our team of authors recently participated in a panel discussion addressing the Real-World Challenges of Developing Immuno-resistance to Botulinum Neurotoxin A in Aesthetic Practice [18]. During this discussion, we reached a consensus that when efficacy and safety are comparable, selecting a formulation with a demonstrated track record of low immunogenicity should be the primary choice. Specifically, for patients who have not undergone previous treatments, the panel agreed that initiating therapy with a BoNT-A formulation possessing the lowest potential for immune reactions is a prudent approach, as it minimizes the risk of developing immuno-resistance. Given that dendritic cells are predominantly situated in the upper layer of the dermis, we expressed concern about the possibility of provoking immune responses. Consequently, we decided to administer IncoBTX-A, which exhibits the lowest known risk of immunogenicity among available options such as AboBTX-A, OnaBTX-A, and IncoBTX-A [18].

Previously, there have been groups of researchers using a combination approach of different modalities of therapy (microfocus ultrasound plus calcium hydroxyapatite [19], or a high-intensity electromagnetic field procedure (HIFEM) plus radiofrequency (RF) combined with targeted pressure energy (TPE) [20]) to treat abdominal skin laxity. Our research is a pilot study combining three totally different treatment modalities (an energy-based device, a filler, and botulinum toxin) to manage abdominal skin laxity.

### 8.4. *Limitation*

While the combination of microfocused ultrasound, calcium hydroxyapatite, and botulinum toxin can be effective in treating abdominal skin laxity, there are some limitations to these treatments that people should consider before deciding to undergo them.

Firstly, microfocused ultrasound may not be suitable for everyone due to certain skin conditions, such as active acne or eczema, as well as for those with pacemakers or other implantable medical devices. Additionally, the procedure may not be effective for individuals with severe skin laxity or those looking for significant improvement.

Secondly, the administration of calcium hydroxyapatite injections carries potential side effects, including temporary swelling, redness, or bruising at the injection site, which may persist for several days. There is also a risk of developing palpable lumps or granulomas in the injected areas. To minimize these risks, it is advisable to adopt a technique of even and widespread injection, uniformly distributing small quantities of CaHA across the treatment sites. To reduce the likelihood of palpable lump formation, it is recommended to avoid injecting CaHA within a 1.5 cm radius of the needle puncture site.

Moreover, it is important to recognize that calcium hydroxyapatite injections may not yield satisfactory results for individuals with significant skin laxity, as their intended purpose is to address concerns related to mild to moderate sagging. Additionally, individuals who have known allergies to any components present in the product should refrain from undergoing this particular treatment.

Furthermore, botulinum toxin is not a permanent solution for abdominal skin laxity and typically offers only temporary results. To maintain the effects of the treatment, people often need to undergo periodic injections, which can create a long-term financial commitment. Additionally, the procedure is not suitable for people with certain medical conditions, such as muscular disorders or those taking blood thinners, as it could interfere with their treatment.

In our study, the left side of the abdomen in cases 3 and 4, where both CaHA and IncoBTX-A were added after microfocused ultrasound treatment, exhibited more significant improvement in terms of skin texture and firmness compared to the right side of the abdomen, where only CaHA was added after microfocused ultrasound treatment. This observation suggests that IncoBTX-A played a role in enhancing skin texture and firmness. However, documenting the precise difference in the extent of improvement between the left side of the abdomen in case 3 and case 4 was challenging. In case 3, 50 U of IncoBTX-A was intradermally injected into the left abdomen, while case 4 received 100 U of IncoBTX-A intradermally injected into the left side of the abdomen. Consequently, it remains unclear whether 100 U of IncoBTX-A is superior to IncoNTX-A. It is worth noting that neither case experienced any issues associated with IncoBTX-A. Further studies could be conducted to investigate whether the efficacy of IncoBTX-A for improving abdominal skin texture is dose-dependent. Considering the large area of the abdomen and the safety profile of IncoBTX-A, we propose the addition of 100 U of IncoBTX-A to each side of the abdomen, following the application of diluted CaHA and microfocused ultrasound, to achieve the optimal outcome without notable side effects.

Another important consideration is the suboptimal photography documentation. Despite the suboptimal setting, good improvements could still be observed in the post-treatment photos. However, the extent of these improvements could have been better documented if there had been consistent settings and standardized lighting conditions throughout the study. In fact, the extent of improvement, as subjectively perceived by the patients, appeared to be greater than what was objectively documented in the photos. Inconsistent lighting in a well-controlled environment often leads to variations in image quality, making it difficult to precisely evaluate the impact of the interventions or treatments being studied.

In addition to the photo quality concerns, another factor that affected the accuracy of the study results was the pose of the patients during photography sessions. It was observed that some patients wore tight pants, which left marks on their abdomen. These marks interfered with the visual assessment of certain parameters and had the potential to skew the results. To mitigate this issue, we learned that patients should be informed in advance about the importance of wearing loose-fitting clothing during the photography sessions.

By doing so, potential interference from marks or indentations on the abdomen can be minimized, leading to more accurate and reliable results.

By addressing these limitations and implementing measures to improve photo quality and patient positioning, we believe our future medical studies can enhance their overall data quality and generate more robust findings.

Despite the limitations, these treatments still offer some advantages over other surgical procedures, particularly for people with mild to moderate skin laxity. While surgical procedures such as tummy tucks can offer long-lasting results, they also involve significant recovery time and the potential for serious complications. Noninvasive treatments such as ultrasound, injectables, and fillers can deliver noticeable improvements with much shorter recovery times and fewer risks.

## 9. Conclusions

Our pilot study suggests that combining microfocused ultrasound, diluted calcium hydroxylapatite (CaHA), and Incobotulinum toxin A (IncoBTX-A) can be an effective approach for improving the skin quality and texture of abdominal skin laxity. By stimulating collagen production with microfocused ultrasound, providing volume and support with diluted calcium hydroxylapatite (CaHA), and relaxing muscles and smoothing lines with Incobotulinum toxin A (IncoBTX-A), we were able to achieve a promising option for patients seeking to improve abdominal skin laxity without the need for surgery.

**Author Contributions:** Conceptualization, C.H.L., L.K.W.C. and K.W.A.L.; methodology, C.H.L., L.K.W.C. and K.W.A.L.; software, C.H.L., L.K.W.C. and K.W.A.L.; validation, C.H.L., L.K.W.C. and K.W.A.L.; formal analysis, C.H.L., L.K.W.C. and K.W.A.L.; investigation, C.H.L., L.K.W.C. and K.W.A.L.; resources, C.H.L., L.K.W.C. and K.W.A.L.; data curation, C.H.L., L.K.W.C. and K.W.A.L.; writing—original draft preparation, C.H.L., L.K.W.C. and K.W.A.L.; writing—review and editing, C.H.L., L.K.W.C. and K.W.A.L.; visualization, C.H.L., L.K.W.C. and K.W.A.L.; supervision, C.H.L., L.K.W.C. and K.W.A.L.; project administration, C.H.L., L.K.W.C. and K.W.A.L.; funding acquisition, C.H.L., L.K.W.C. and K.W.A.L. All authors have read and agreed to the published version of the manuscript.

**Funding:** This research received no external funding.

**Institutional Review Board Statement:** Not applicable.

**Informed Consent Statement:** Informed consent was obtained from all subjects involved in the study. Written informed consent has been obtained from the patients to publish this paper.

**Data Availability Statement:** No new data were created or analyzed in this study. Data sharing is not applicable to this article.

**Conflicts of Interest:** The authors declare no conflict of interest.

## References

1. Brightman, L.; Weiss, E.; Chapas, A.M.; Karen, J.; Hale, E.; Bernstein, L.; Geronemus, R.G. Improvement in arm and post-partum abdominal and flank subcutaneous fat deposits and skin laxity using a bipolar radiofrequency, infrared, vacuum and mechanical massage device. *Lasers Surg. Med. Off. J. Am. Soc. Laser Med. Surg.* **2009**, *41*, 791–798. [[CrossRef](#)] [[PubMed](#)]
2. Park, J.Y.; Lin, F.; Suwanchinda, A.; Wanitphakdeedecha, R.; Yu, J.; Lim, T.S.; Chen, J.F.; Ho, W.; Lim, J.; Juniarty, L.; et al. Customized treatment using microfocused ultrasound with visualization for optimized patient outcomes: A review of skin-tightening energy technologies and a pan-Asian adaptation of the expert panel's gold standard consensus. *J. Clin. Aesthetic Dermatol.* **2021**, *14*, E70.
3. Lapatina, N.G.; Pavlenko, T. Diluted calcium hydroxylapatite for skin tightening of the upper arms and abdomen. *J. Drugs Dermatol.* **2017**, *16*, 900–906. [[PubMed](#)]
4. Wu, W.T. Microbotox of the lower face and neck: Evolution of a personal technique and its clinical effects. *Plast. Reconstr. Surg.* **2015**, *136*, 92S–100S. [[CrossRef](#)]
5. Brandt, F.S.; Bellman, B. Cosmetic use of botulinum A exotoxin for the aging neck. *Dermatol. Surg.* **1998**, *24*, 1232–1234. [[CrossRef](#)]
6. Kaplan, H.; Gat, A. Clinical and histopathological results following TriPollar™ radiofrequency skin treatments. *J. Cosmet. Laser Ther.* **2009**, *11*, 78–84. [[CrossRef](#)] [[PubMed](#)]



7. Suh, D.-H.; Chang, K.-Y.; Son, H.-C.; Ryu, J.-H.; Lee, S.-J.; Song, K.-Y. Radiofrequency and 585-nm pulsed dye laser treatment of striae distensae: A report of 37 Asian patients. *Dermatol. Surg.* **2007**, *33*, 29–34. [[CrossRef](#)] [[PubMed](#)]
8. Anolik, R.; Chapas, A.M.; Brightman, L.A.; Geronemus, R.G. Radiofrequency devices for body shaping: A review and study of 12 patients. *Semin. Cutan. Med. Surg.* **2009**, *28*, 236–243. [[CrossRef](#)] [[PubMed](#)]
9. Kapoor, R.; Shome, D.; Ranjan, A. Use of a novel combined radiofrequency and ultrasound device for lipolysis, skin tightening and cellulite treatment. *J. Cosmet. Laser Ther.* **2017**, *19*, 266–274. [[CrossRef](#)] [[PubMed](#)]
10. Moreno-Moraga, J.; Muñoz, E.; Navarro, P.C. Multisource, phase-controlled radiofrequency for treatment of skin laxity: Correlation between clinical and in-vivo confocal microscopy results and real-time thermal changes. *J. Clin. Aesthetic Dermatol.* **2011**, *4*, 28.
11. Ko, E.J.; Hong, J.Y.; Kwon, T.R.; Choi, E.J.; Jang, Y.J.; Choi, S.Y.; Yoo, K.H.; Kim, S.Y.; Kim, B.J. Efficacy and safety of non-invasive body tightening with high-intensity focused ultrasound (HIFU). *Ski. Res. Technol.* **2017**, *23*, 558–562. [[CrossRef](#)] [[PubMed](#)]
12. Laubach, H.J.; Makin, I.R.; Barthe, P.G.; Slayton, M.H.; Manstein, D. Intense focused ultrasound: Evaluation of a new treatment modality for precise microcoagulation within the skin. *Dermatol. Surg.* **2008**, *34*, 727–734. [[CrossRef](#)] [[PubMed](#)]
13. Voravutinon, N.; Seawthaweesin, K.; Bureethan, A.; Srivipatana, A.; Vejanurug, P. Efficacy of diode laser (810 and 940 nm) for facial skin tightening. *J. Cosmet. Dermatol.* **2015**, *14*, E7–E14. [[CrossRef](#)] [[PubMed](#)]
14. Yutskovskaya, Y.A.; Sergeeva, A.D.; Kogan, E.A. Combination of Calcium Hydroxylapatite Diluted with Normal Saline and Microfocused Ultrasound with Visualization for Skin Tightening. *J. Drugs Dermatol.* **2020**, *19*, 405–411. [[CrossRef](#)] [[PubMed](#)]
15. Jabbour, S.F.; Kechichian, E.G.; Awaida, C.J.; Tomb, R.R.; Nasr, M.W. Botulinum toxin for neck rejuvenation: Assessing efficacy and redefining patient selection. *Plast. Reconstr. Surg.* **2017**, *140*, 9e–17e. [[CrossRef](#)] [[PubMed](#)]
16. Park, J.Y.; Chen, J.F.; Choi, H.; Ho, W.W.; Lesthari, N.N.I.; Lim, J.T.E.; Lim, T.S.; Lowe, S.; Ong-Amoranto, B.; Vachirammon, V.; et al. Insights on skin quality and clinical practice trends in Asia pacific and a practical guide to good skin quality from the inside out. *J. Clin. Aesthetic Dermatol.* **2022**, *15*, 10.
17. Fabi, S.G.; Burgess, C.; Carruthers, A.; Carruthers, J.; Day, D.; Goldie, K.; Kerscher, M.; Nikolis, A.; Pavicic, T.; Rho, N.-K.; et al. Consensus recommendations for combined aesthetic interventions using botulinum toxin, fillers, and microfocused ultrasound in the neck, décolletage, hands, and other areas of the body. *Dermatol. Surg.* **2016**, *42*, 1199–1208. [[CrossRef](#)] [[PubMed](#)]
18. Ho, W.W.S.; Chan, L.; Corduff, N.; Lau, W.-T.; Martin, M.U.; Tay, C.M.; Wang, S.; Wu, R. Addressing the Real-World Challenges of Immuno-resistance to Botulinum Neurotoxin A in Aesthetic Practice: Insights and Recommendations from a Panel Discussion in Hong Kong. *Toxins* **2023**, *15*, 456. [[CrossRef](#)] [[PubMed](#)]
19. Bartsch, R.; Casabona, G.; Sitzwohl, C.; Kimberger, O.; Green, J.B.; Stanger, J.; Frank, K.; Onishi, E.C.; Cotozana, S. The Influence of Different Treatment Combinations on Skin Laxity and Dimpling. *J. Drugs Dermatol.* **2020**, *19*, 1030–1038. [[CrossRef](#)] [[PubMed](#)]
20. Duncan, D.I. Combination treatment for buttock and abdominal remodeling and skin improvement using HIFEM procedure and simultaneous delivery of radiofrequency and targeted pressure energy. *J. Cosmet. Dermatol.* **2021**, *20*, 3893–3898. [[CrossRef](#)] [[PubMed](#)]

**Disclaimer/Publisher’s Note:** The statements, opinions and data contained in all publications are solely those of the individual author(s) and contributor(s) and not of MDPI and/or the editor(s). MDPI and/or the editor(s) disclaim responsibility for any injury to people or property resulting from any ideas, methods, instructions or products referred to in the content.