

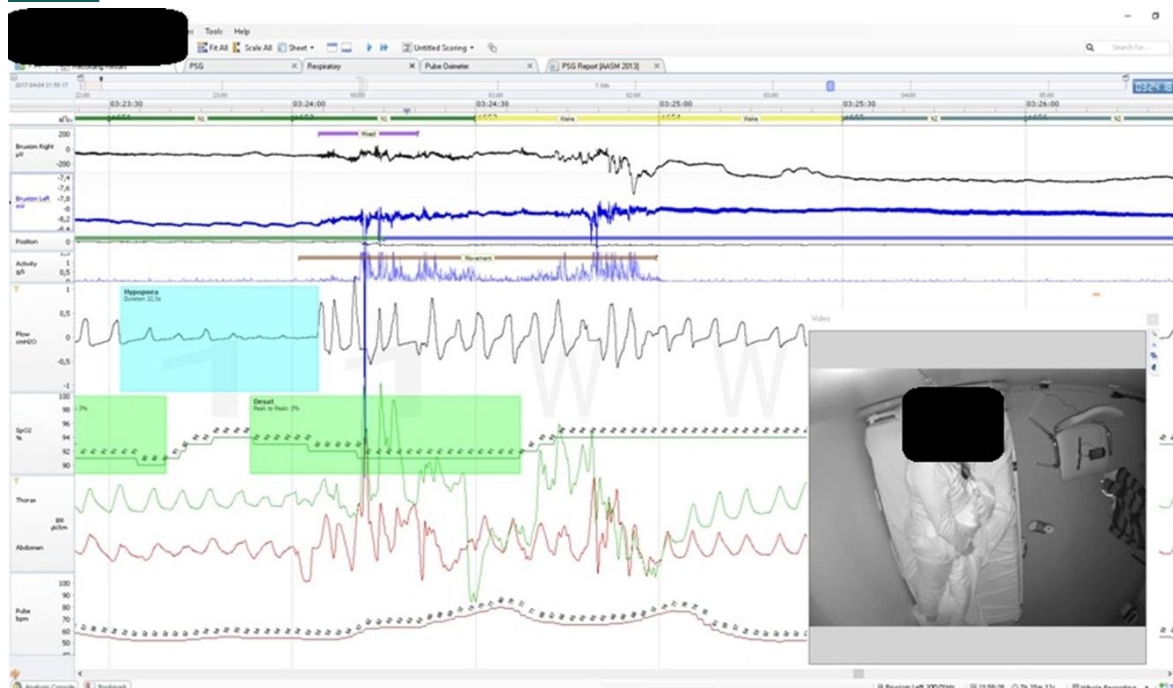Figure S1. Sexsomnia episode on N1/N2 transition with bruxism activity preceding the episode.

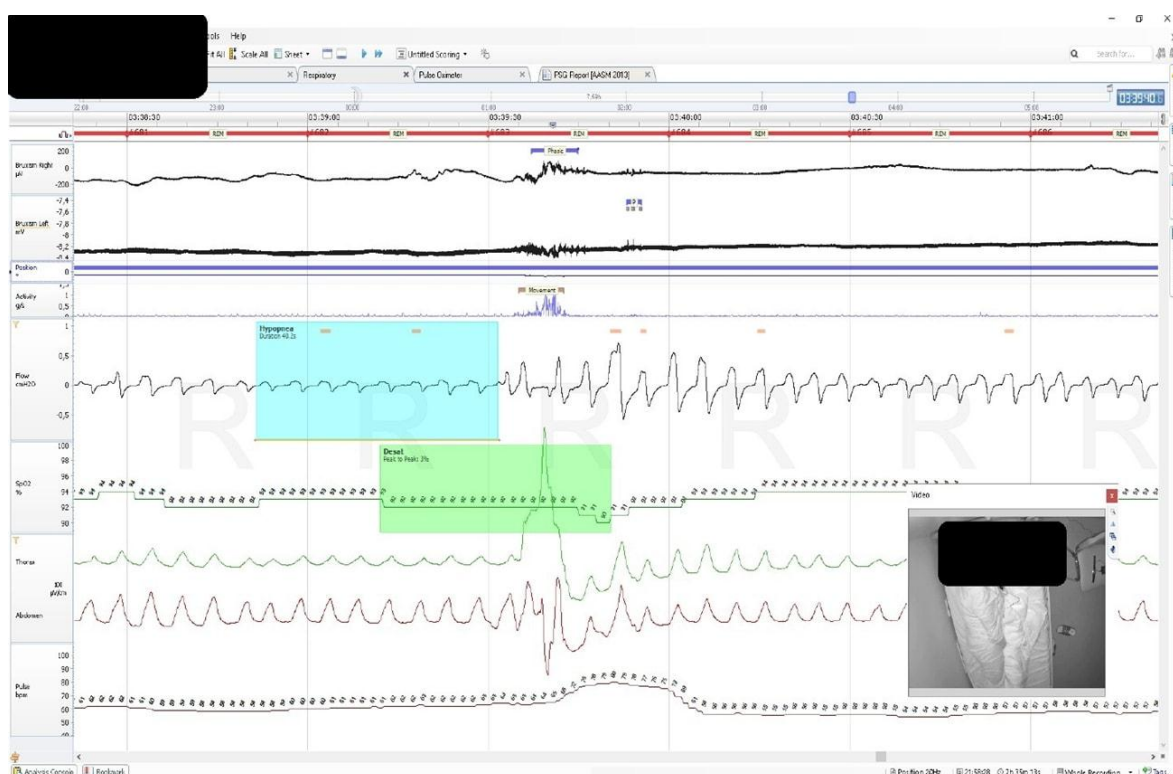


Figure S2. Bruxism episode followed by sexsomnia in REM sleep.

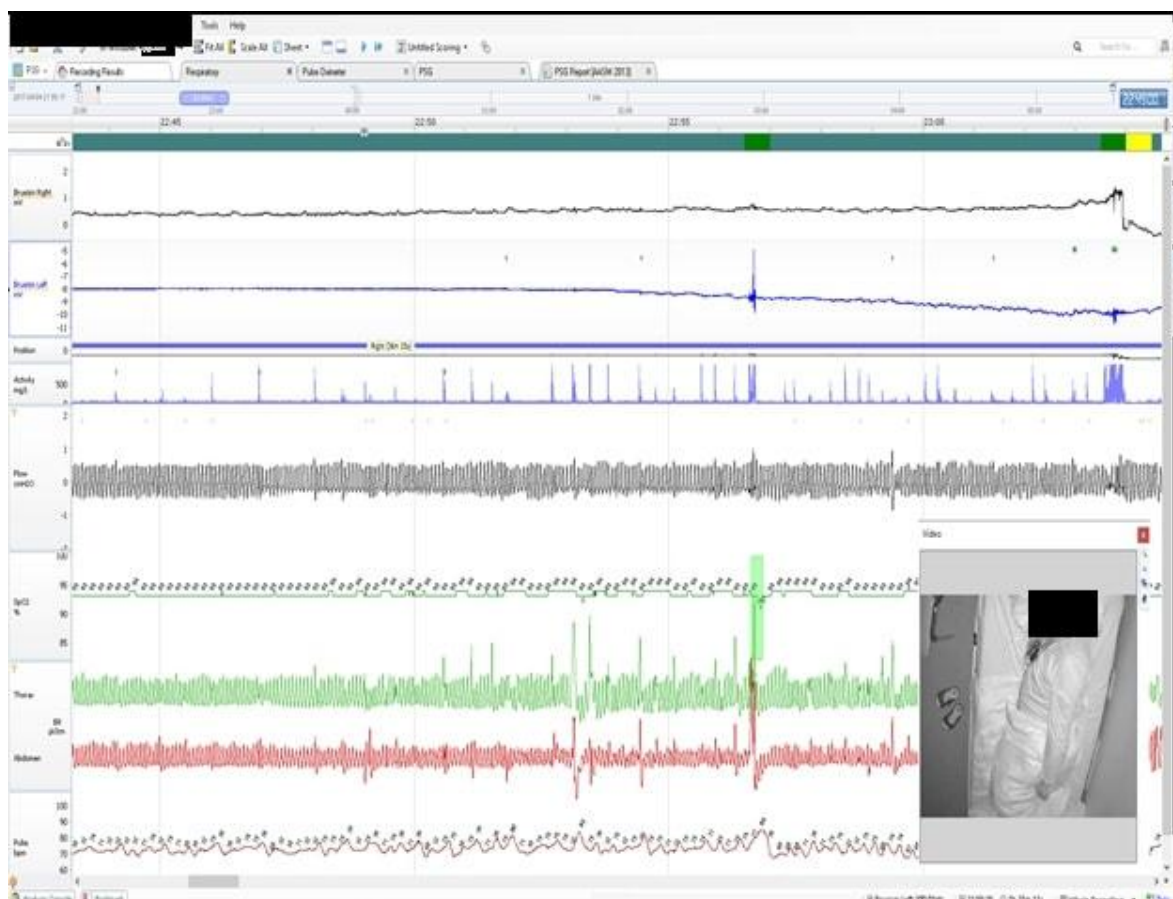


Figure S3. Myoclonic activity—21 min episode.

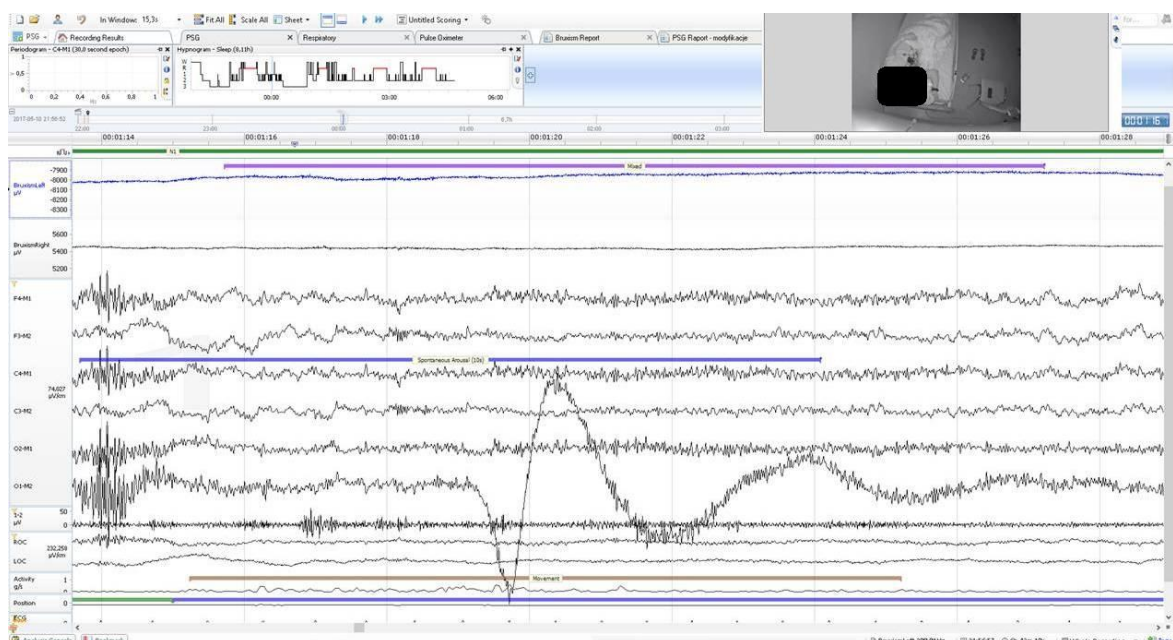


Figure S4. EEG of a single sexsomnia event.

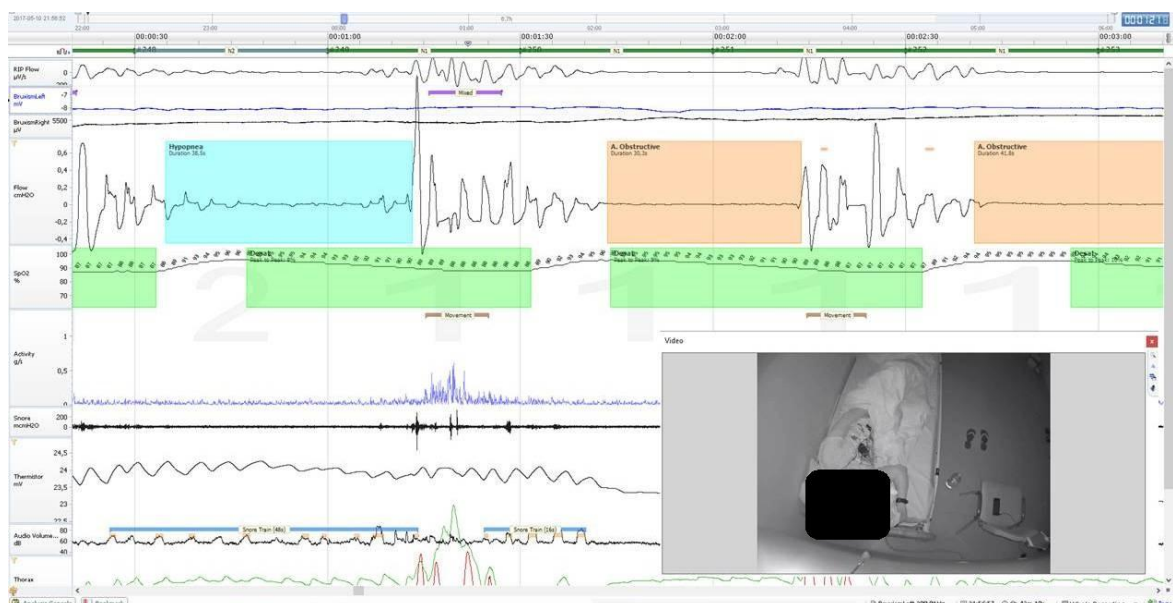


Figure S5. First two sexsomnia events.

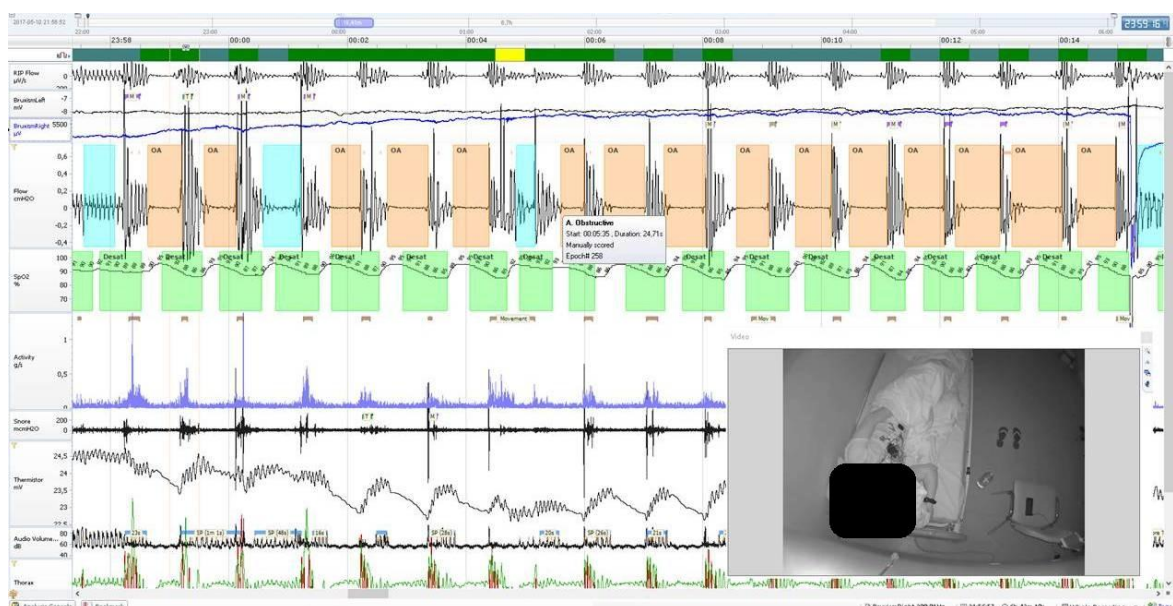


Figure S6. Whole sexsomnia episode.