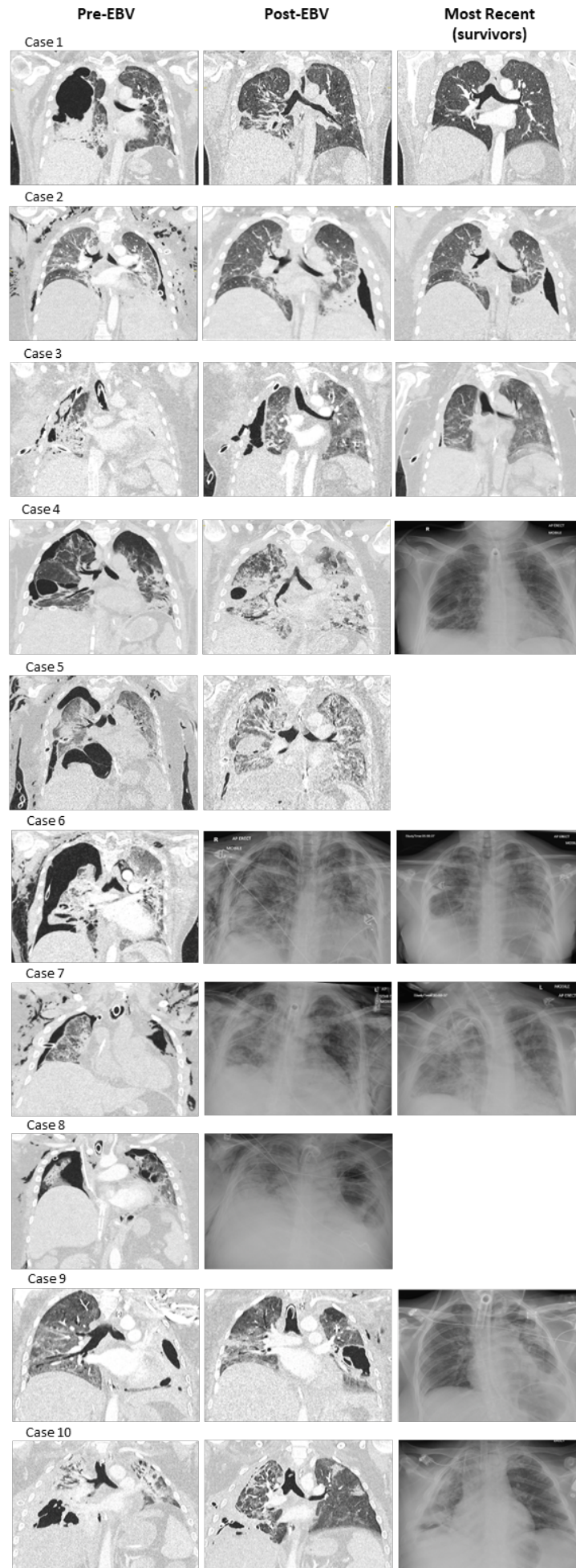


Bronchoscopic Endobronchial Valve Therapy for Persistent Air Leaks in COVID-19 Patients Requiring Veno-Venous Extracorporeal Membrane Oxygenation

*Barbara Ficial, Stephen Whebell, Daniel Taylor, Rita Fernández-Garda, Lawrence Okiror,
and Christopher I. S. Meadows*

Supplementary Material



Supplementary Figure SA: Imaging of all cases before EBV placement, after EBV placement and the most recent imaging available for survivors
 CT imaging used where available, plain film x-ray presented otherwise
 EBV – endobronchial valve