

Supplementary Materials:

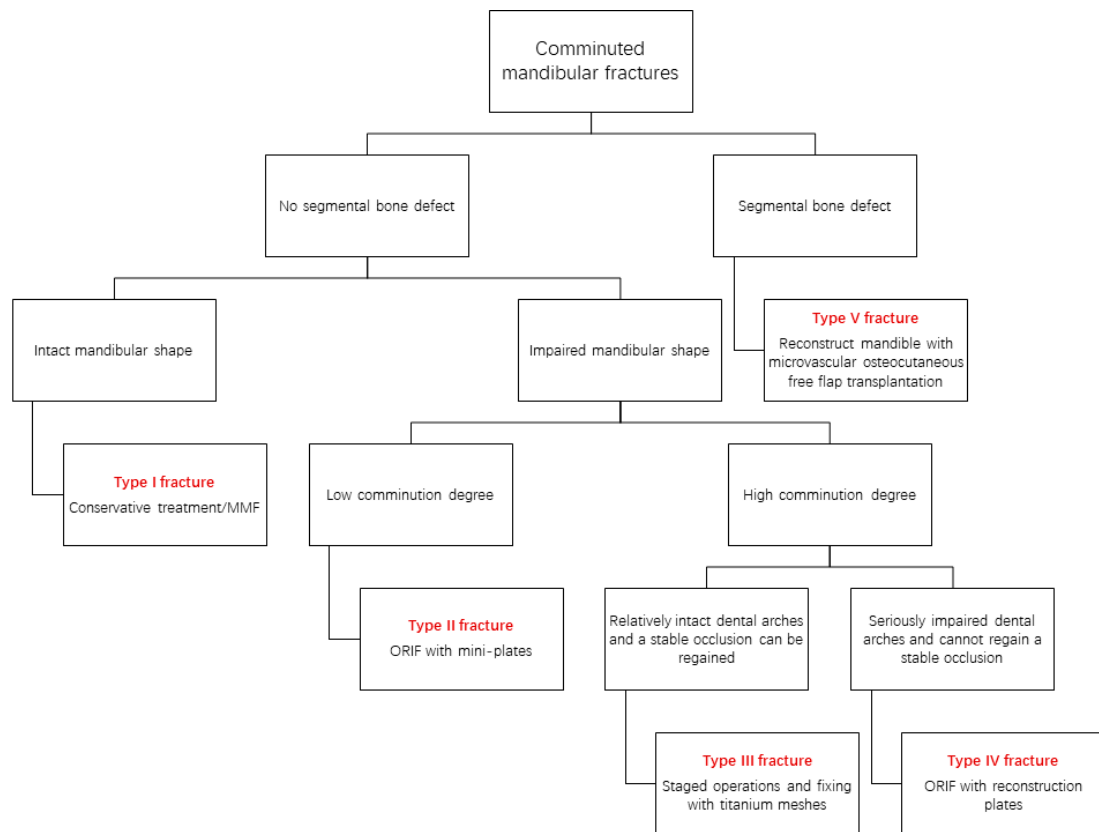


Figure S1. mind map of the OCCS classification for comminuted mandibular fractures.

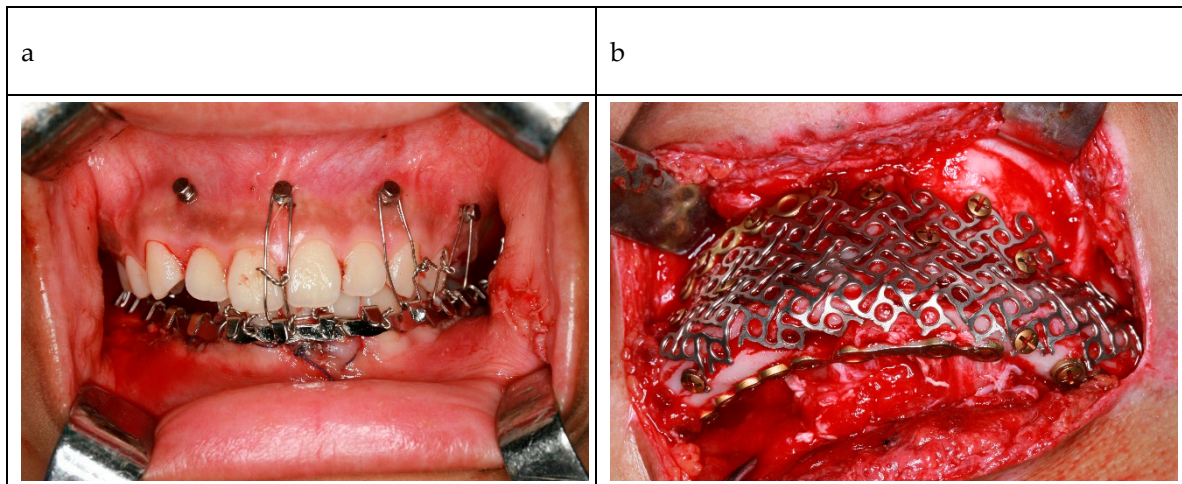


Figure S2. photographs of the type III fracture. (a) after stage one surgery, wound was sutured and the occlusal relationship was restored and fixed with MMF; (b) the intraoperative photograph, titanium mesh and mini-plates were used to fix the fracture site. MMF: maxillomandibular fixation.