
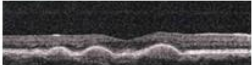

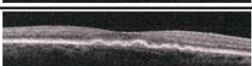
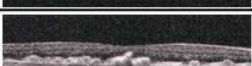





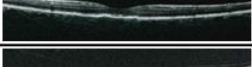
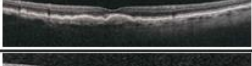

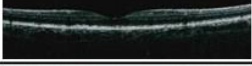






Supplementary Figure Legend

Patient	Optical Coherence Tomography (OCT)
1	
2	
3	
4	
5	
6	
7	
8	
9	
10	
11	
12	
13	
14	
15	
16	
17	
18	

Supplementary Figure S1. Optical Coherence Tomography (OCT) from AMD patients. OCT were obtained from the very same patients (identified by the same progressive number) reported in Table 1, concerning the measurement of visual acuity and the drusenoid area. These representative OCT confirm the potential dissociation between the loss of visual acuity and the amount of drusenoid area, which was measured in Table 1. All patients signed an informed consent.