

Case Report

Clinical Case Employing Two Different Biomaterials in Bone Regeneration

Roberto Ghiretti ^{1,*}, Carlo F. Grottoli ², Alberto Cingolani ² and Giuseppe Perale ^{2,3,4}¹ Private Practice, 46047 Porto Mantovano, Italy² Industrie Biomediche Insubri SA, Via Cantonale 67, 6805 Mezzovico-Vira, Switzerland; carlo.grottoli@ibi-sa.com (C.F.G.); alberto.cingolani@ibi-sa.com (A.C.); giuseppe@ibi-sa.com (G.P.)³ Faculty of Biomedical Sciences, University of Southern Switzerland (USI), Via G. Buffi 13, 6900 Lugano, Switzerland⁴ Ludwig Boltzmann Institute for Experimental and Clinical Traumatology, Donaueschingenstrasse 13, 1200 Vienna, Austria

* Correspondence: roberto.ghiretti@libero.it

Received: 26 May 2020; Accepted: 24 June 2020; Published: 29 June 2020



Abstract: The case of a 59-year-old woman lacking bone in the lower left side of her mandible, and treated with two different biomaterials for bone regeneration, is reported here. Specifically, two different anatomical sites damaged by two different pathologies were studied: a radicular fracture and peri-implantitis. The sites were treated via xenograft bone substitute and calcium phosphosilicate, respectively. Follow-up evaluations showed that the two different methodologies employing different materials in the same organism undergoing the same metabolic processes achieved the same good results. This represents a significant change in current surgical strategies for the dental region: instead of focusing on a single gold-standard technique, it is possible to follow a hybrid approach by adapting the biomaterial and the protocol used to the specificities of the defect.

Keywords: bone grafts; xenograft; calcium phosphosilicate; CGF

1. Introduction

Mandibular augmentations are surgical procedures that often require the use of bone grafts. This way, after a period of recovery to enable osteointegration, correct implant positioning is possible. In general, they are more complicated than maxillary-bone augmentations because of the thicker cortical layer of the patient's residual bone, which limits blood supply and overall graft integration.

The gold-standard approach involves autologous (cortical and medullar) bone harvested from the patient [1,2]. This ensures limited probability of rejection [3], but still carries inherent risks, particularly with regard to the comorbidity of the harvest site. In general, this grafting technique relies on two major concepts: the “diamond” (or regenerative pentagon) and the “organic room” [4]. The resulting protocol, which is very common and effective in orthopedic practice, entails that all biological activities occurring during osteointegration are confined to a vital, aseptic, mechanically stable, sealed environment (the “room”) [4]. Of course, such an environment is difficult to prepare in a more *hostile* region like the oral. Indeed, surgeons usually have to operate under local anesthesia in a much more contaminated environment. Moreover, application sites are often less surgically accessible, are in contact with moving structures (e.g., the jaw, tongue, and cheeks), and the soft tissue at the sites can be fragile and difficult to utilize for the proper coverage and final sealing of the hypothetical organic room (tissue expanders are, in fact, seldom used in this kind of surgery). This leads to a long postoperative period and subsequent reconstruction of bone-regeneration materials that have been under strain from the patient's unavoidable chewing activity. As a matter of fact, an appropriate

organic room, comparable to the ones used in orthopedic surgery, is very hard to obtain in dental applications. Moreover, the use of autologous bone inevitably entails that a second active operative site is necessary for the harvest, which might increase the possibility of clinical complications.

Alternatively, the use of nonautologous bone substitutes (e.g., allografts, xenografts, or synthetic grafts) is highly consolidated through routine practice and clinical results from the literature [5–8]. Although gaining full control over these materials' characteristics is not trivial, and complex strategies have to be developed [9–13]. Nonetheless, they are able to provide mechanical properties, microstructures (e.g., porosity [14]), and compositions that are comparable to those of autologous bone [15–18].

The application protocol might also depend on the chosen biomaterial, and it may be different from the one described above. Nevertheless, the efficacy of these materials for treating any kind of defect is highly documented in the literature [6,19]. In general, xenografts have applications in defects where mechanical stability is a major requirement. On the other hand, bioactive glasses have a long track record of clinical success in four-wall defects (e.g., socket preservation, sinus lifts), where appropriate filling for a cavity is the main necessity [20].

Although many cases are performed each year, there is still little focus on studying an effective comparison of different biomaterials [21,22]. Indeed, not all biomaterials exhibit the same behavior in equivalent clinical situations. Moreover, they often have a specific application protocol that might be more or less invasive depending on the application site. Each rehabilitation case might be better treated with a specific biomaterial that best suits the conditions of the defect. Of course, this approach requires a detailed understanding of the features and performance of each graft, and a fair and effective comparison. In this respect, it is clear that the application site's characteristics and a patient's clinical conditions are two major sources of variability in evaluating a material's performance. This explains why few data are available on this topic [21,22].

In this work, we investigated the performance of two different biomaterials when applied to the same region at the same time on a single patient. This represents a major change of perspective on surgical strategies for dental region: instead of focusing on a single gold-standard technique, we suggest adapting the choice of biomaterial and protocol to the specificity of the defect. Specifically, two different anatomical sites damaged by two different pathologies were evaluated, a radicular fracture and peri-implantitis. The sites were treated via xenograft bone substitute (SmartBone®, Industrie Biomediche Insubri SA, Mezzovico-Vira, Switzerland) and calcium phosphosilicate (NovaBone Dental Putty, NovaBone, Jacksonville, USA), respectively. The first region presented a considerable loss of vestibular cortical bone, and a xenograft was used to provide mechanical and volumetric stability during the osteointegration process. The second region was comparable to a postextraction site, with the four walls preserved. Thus, this region was optimal for the application of a synthetic putty. Clinical and radiological follow-ups showed that the use of different materials in the same organism achieved the same good results, validating the presented strategy.

2. Clinical Report

2.1. Case Description

Our patient was a 59-year-old Caucasian woman, who was a nonsmoker and a nondrinker. Her medical history reported recurring abscessual episodes in regions 34–36, where a fixed prosthesis was present. Its pillars had exhibited several issues since 2010, as is visible in Figures 1 and 2. Indeed, it was possible to see a periapical lesion in Region 34, and peri-implantitis around the implant in Region 36. At the same time, there was also a radiolucent lesion at the apexes of regions 45 and 46.

Over time, all lesions in the oral cavity were treated. Lastly, with the patient's agreement, the rehabilitation of Regions 34–36 was initiated, ending with prosthetic restoration. Initially, retreatment of Region 34 was performed since it presented a periapical lesion (which was already present in 2010). In May 2017, as the lesion was already significantly regressing, we proceeded to extract Region 35 and remove the implant at Region 36, since it had begun exhibiting pericoronitis in a large area.

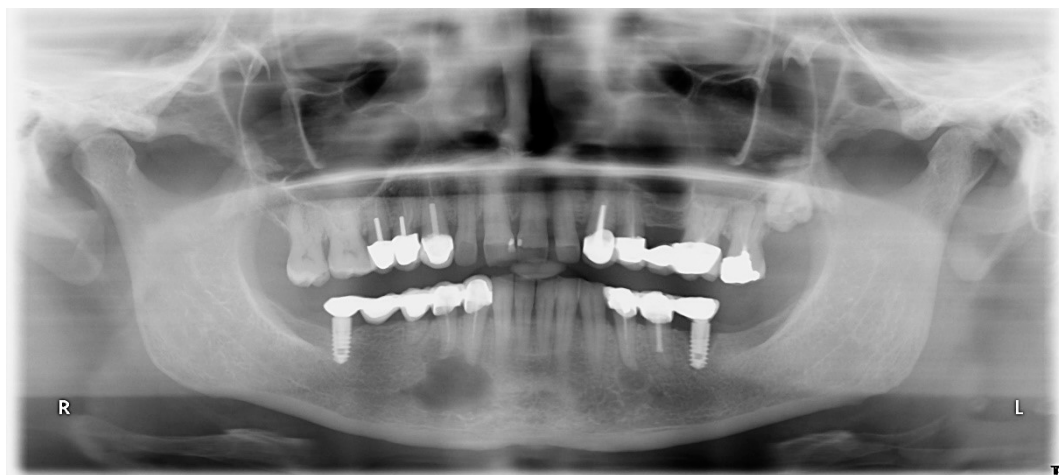


Figure 1. Rx Opt from 2010, taken when treating the patient.

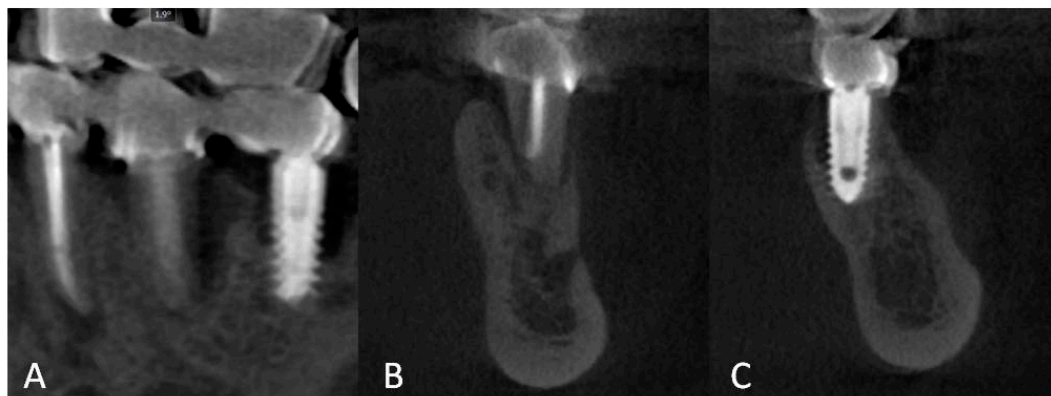


Figure 2. Cone-beam computed tomography (CBCT) analysis (Acteon X-Mind Trium) before surgical treatment showed severe impairment of Region 35 caused by radicular fracture and accentuated peri-implantitis around fixture in Region 36. (A) Curved planar reformation, and cross-sections of Regions (B) 35 and (C) 36.

At the site where we extracted Region 35, we proceeded to implant xenohybrid graft SmartBone (SB), developed and manufactured by Industrie Biomediche Insubri SA (IBI-SA) via a proprietary process that improves the properties of naturally derived biomaterials [23]. SB was specifically developed for regenerative-medicine applications, and has a long track record of clinical applications [24–28]. SB is composed of a decellularized-bovine-bone matrix reinforced with bioresorbable aliphatic polyesters and RGD-containing collagen fragments [23,29], where RGD is the tripeptide sequence ArginylGlycylAspartic acid that is the most common peptide motif responsible for cell adhesion to the extracellular matrix. SB was mixed with concentrated growth factors (CGFs; Medifuge MF200, Silfradent S.R.C., 47018 Santa Sofia FC, Italy) using a special technique that ensured a product richer in regeneration factors and easy to manipulate [30,31]. In this region, recurring inflammatory episodes due to the longitudinal radicular fracture had caused considerable vestibular-cortical-bone loss, which was the reason for using a xenograft in this area.

In Region 36, peri-implantitis had created a substantial bone-erosion cone, but had not caused much vestibular-cortical-bone loss, hence the decision to graft a calcium-phosphosilicate-based alloplastic material (NovaBone Dental Putty, Novabone, Jacksonville, FL USA). This was placed inside the remaining residual site after implant removal. Calcium phosphate derivatives provide less mechanical support than SB xenografts, as they have low resistance to tension, and during their degradation, their mechanical resistance is quickly reduced [20]. We knew from the scientific literature that, in septic cases, the best course of action is to operate on two different occasions separated by at least

40–60 days. However, we chose a more aggressive procedure, treating the bone sites with an antibiotic wash (RIFOCIN® rifamycin, Sanofi Aventis, Paris, France), and applying laser decontamination (Deka SmartFile Nd:YAG, DEKA, Calenzano, FI, Italy). We proceeded to apply the materials as previously described using a CGF membrane (Silfradent Medifuge MF200), and then sutured the trapezoidal flap with silk along its width, having previously sculpted the area through full-thickness skeletonization of the external mandibular cortex with respect to the neurovascular bundle emerging from the mental hole. This design allowed us to obtain a tissue cover for the graft from the periosteum in order to achieve the best revascularization possible. Indeed, after extraction and the careful removal of residual inflammatory tissue, antibiotic treatment was applied by washing the area, and laser decontamination was performed on the region before applying the bone-regeneration materials. The mucoperiosteal flap was passivated with a low incision in the periosteum using a scalpel, and the tissue was detached using blunt scissors.

2.2. Discussion

Three-dimensional radiographic analysis during postoperative check-up showed both materials compacting correctly but behaving very differently under radiolucency.

As can be seen in Figure 3, SB particulate mixed with CGF was quite highly radiotransparent, maintaining fair homogeneity with scarce vacuolar-compacting flaws. The zone to be reconstructed, where the vestibular cortical bone had been eroded by inflammatory episodes, seemed well-supported. The calcium phosphosilicate material seemed compact and homogeneous, almost simulating a cortical than a cancellous bone.

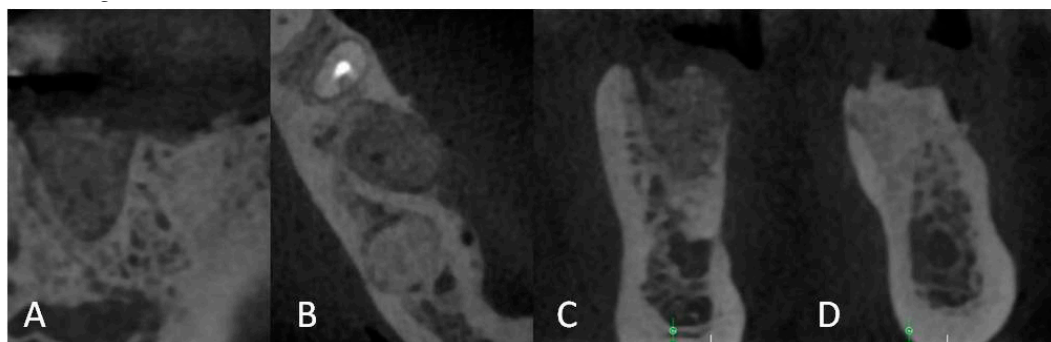


Figure 3. Postoperative 3D radiographic analysis (Acteon X-Mind Trium) in (A) sagittal and (B) axial projection, and cross-sections of Regions (C) 35 and (D) 36.

Four months later, after a clinically asymptomatic period, we radiographically examined the evolution of the grafts (see Figure 4).

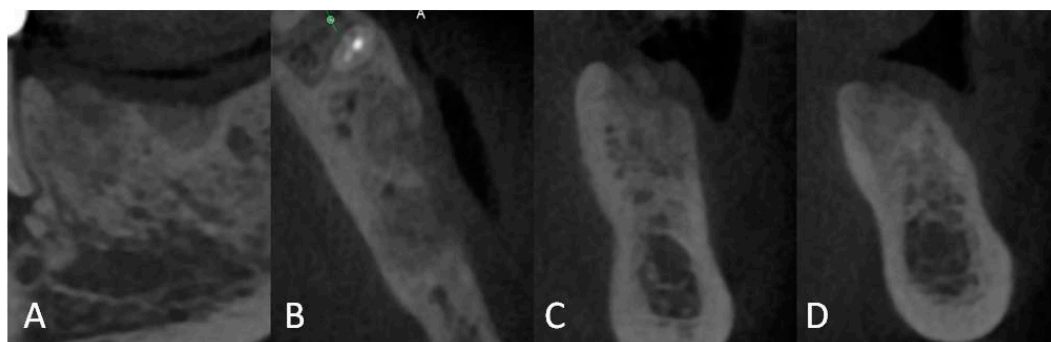


Figure 4. Three-dimensional radiographic analysis (Acteon X-Mind Trium) done four months later, in (A) sagittal and (B) axial projection, and cross-sections of Regions (C) 35 and (D) 36.

In both surgical sites, we could see similar radiographic appearance, and both appeared morphologically suitable for implant surgery, as both materials seemed to have offered an effective structural support for bone regeneration on both lesions. No radiological evaluation was performed on the quality of bone density or on the level of bone growth during the healing process. The impossibility of performing reliable measurements was caused by difficulties in generating constant reference points though images captured during the different follow-ups. The only possible evaluations were conducted by comparing three-dimensional renderings with operative surgical feedback, and by evaluating what we saw in the implant-planning phase and the immediate postoperative period following the regenerative surgery compared to what was seen four months after the regenerative treatment.

The three-dimensional rendering shown in Figure 5 demonstrates, beyond any objective measure, definite vestibular-cortical-bone loss at Region 35, while Region 36, where the peri-implantitis was, did not show the same morphology. Rendering in axial projection showed a regenerative material chromatically similar to the mandibular cortical bone already noticed in two-dimensional analysis. Four months later (right side of the image), good regeneration could be seen in the vestibular cortical bone, aided by the xenohybrid-bone particulate of SB mixed with CGF. Furthermore, the chromatic appearance of both regeneration materials was very similar, as if their morphogenetic structures were comparable to those of equal regenerative development.

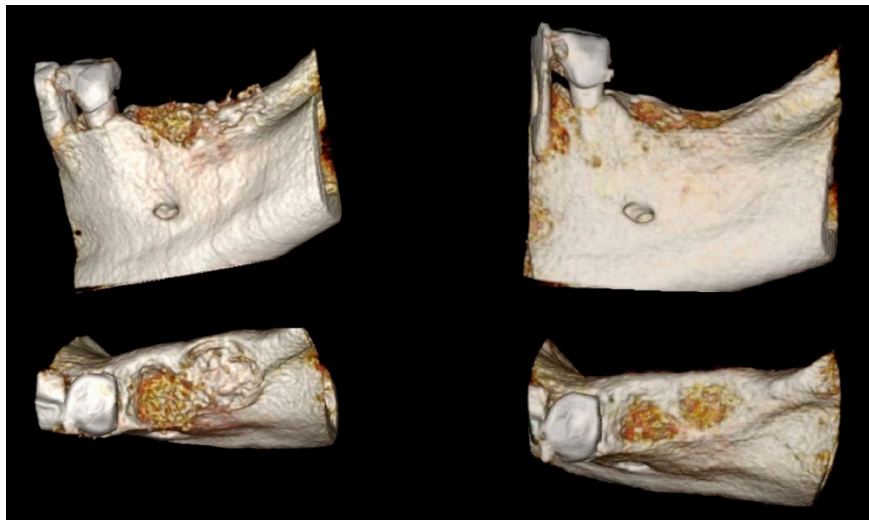


Figure 5. Three-dimensional rendering (OsiriX) in sagittal and axial views taken from CBCT (**left**) during postoperative period and (**right**) four months after the regenerative surgery.

From a surgical point of view, bone quality surgically detected while working with bone drills proved excellent in both implant sites; despite that, the maxillary alveolar cortical bone was not yet well-consolidated, as seen in the three-dimensional rendering.

Although we could not perform reliable measurements of loss or gain achieved through regenerative surgery, we could evaluate what we achieved by estimating what was seen during the postoperative check-up, what we expected, and what was achieved four months later. Figure 6A,B shows an implant simulation with two Immediateload Universe 4 × 11.5 mm (IML SA, via Moree 16, 6850 Mendrisio, Switzerland) implants just after surgery. Figure 6C,D present a simulation of what could be seen four months later, while Figure 6E,F is the real outcome after implant insertion. All things considered, all images were similar, proving that regeneration was successful. Moreover, as presented in Figure 7A–D, the long-term follow-up after 37 months clearly demonstrated the results of regeneration for both biomaterials. Considering the two different sites, and hence the different anatomical needs to address, SB allowed for the regeneration of the cortical wall. SB was basically a cancellous graft that was also proven to sustain anatomically selective remodeling in the dental region,

that is, it also allowed for the formation of new cortical bone where needed, as already seen in different orthopedic specialty areas [32,33].

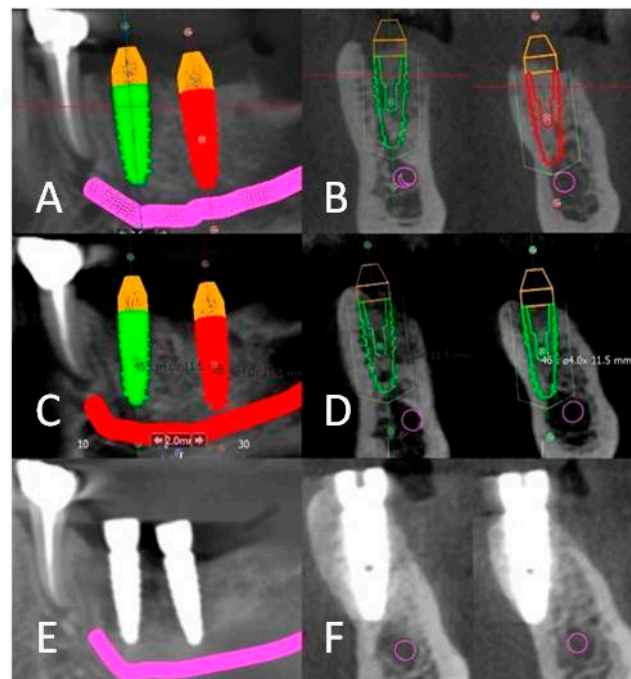


Figure 6. Surgical implant simulation with Immediateload Universe 4 × 11.5 mm implants (A,B) immediately after bone augmentation and (C,D) after four months of bone augmentation; (E,F) implant placement after eight months of bone augmentation.

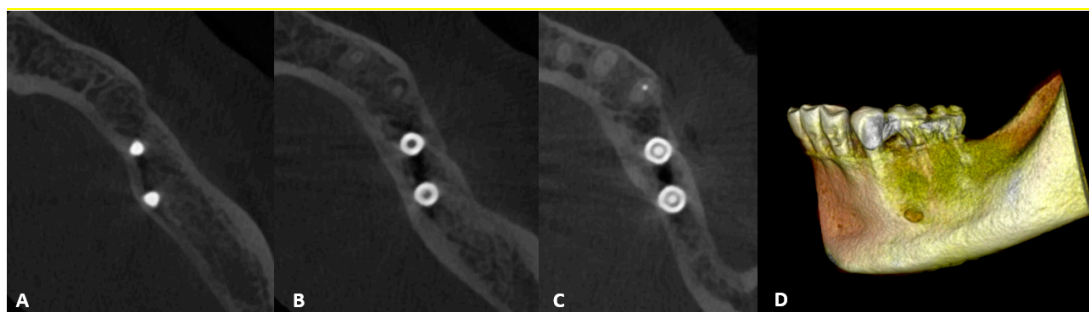


Figure 7. CBCT follow-up at 37 months. (A–C) Axial view from bottom upwards. (D) Three-dimensional rendering (OsiriX) based on CBCT from postoperative check-up at 37 months after regenerative surgery.

3. Conclusions

Regenerative surgery for bone defects offers us different solutions according to the lesions that patients present. It is up to us to decide the best method to recreate an adequate morphology for an implant approach. In the presented case, two different etiological defects were addressed with different methods and different biomaterials. The most serious defect, which caused serious vestibular bone loss, was treated with a scaffold that had structurally better mechanical characteristics for the nature of the bone defect itself. The xenohybrid biomaterial, combined with CGF, created a kind of biological reactor or organic room, which is often used in this kind of surgery. Conditions required different treatment for the second site. The calcium phosphosilicate did not possess the same mechanical characteristics as those of a xenogenic bone graft, but it was very suitable for socket preservation [25] provided that the treated region received good coverage in order to achieve the proper revascularization of grafts from periosteal vessels. Having a patient with different lesions allowed us to validate the strategy of

adapting our choice of biomaterial to the characteristics of the defect. The positive evaluation of the response to these two regenerative methods when subjected to the same metabolic processes strongly indicated that our strategy was successful, and it provides meaningful data for the scientific community to explore novel applications.

Lastly, a complementary consideration of soft-tissue management had to be considered, given the key role that it played during the initial healing and regeneration phases. Thanks to the applied techniques, passive closure of the flap allowed for the periosteum to be positioned in direct contact with the grafting material to promote proper neoangiogenesis from the periosteum itself. This provided an inflow of oxygen, active cells during the bone-transformation process, and growth factors. The early postoperative course was excellent, and this allowed for regeneration to proceed under ideal conditions, where different biomaterials could perform at their best and in unbiased conditions.

Consent to Participate: The patient signed an informed-consent form to document that she understood the aims of the study, and authorized the use of her data for research purposes. All procedures were performed in strict accordance with the recommendations of the Declaration of Helsinki, as revised in Fortaleza (2013), for investigations with human subjects, and followed good clinical practices and ISO14155 prescriptions.

Author Contributions: R.G. conceptualized the study, performed the surgery, performed clinical evaluations during follow-ups, supervised the project, and wrote the paper. C.F.G. supervised the project. C.F.G., A.C., and G.P. reviewed and wrote the paper. All authors have read and agreed to the published version of the manuscript.

Funding: This research received no external funding.

Conflicts of Interest: G.P. is a shareholder of Industrie Biomediche Insubri SA, the Swiss company that owns intellectual property rights to, manufactures, and commercialized SmartBone. C.F.G. and A.C. work for the same company. R.G. declares no conflict of interest.

References

1. Haugen, H.J.; Lyngstadaas, S.P.; Rossi, F.; Perale, G. Bone grafts: Which is the ideal biomaterial? *J. Clin. Periodontol.* **2019**, *46*, 92–102. [\[CrossRef\]](#) [\[PubMed\]](#)
2. Blokhuis, T.J.; Arts, J.J.C. Bioactive and osteoinductive bone graft substitutes: Definitions, facts and myths. *Injury* **2011**, *42*, S26. [\[CrossRef\]](#)
3. Sakkas, A.; Wilde, F.; Heufelder, M.; Winter, K.; Schramm, A. Autogenous bone grafts in oral implantology—is it still a “gold standard”? A consecutive review of 279 patients with 456 clinical procedures. *Int. J. Implant Dent.* **2017**, *3*, 23. [\[CrossRef\]](#) [\[PubMed\]](#)
4. Calori, G.M.; Colombo, M.; Mazza, E.; Mazzola, S.; Malagoli, E. Il principio della camera biologica nel trattamento delle pseudoartrosi complesse e delle perdite di sostanza ossee: Quali materiali e perché? *Arch. Ortop. Reumatol.* **2013**, *124*, 22. [\[CrossRef\]](#)
5. Colaço, H.B.; Shah, Z.; Back, D.; Davies, A.; Ajuied, A. (iv) Xenograft in orthopaedics. *Orthop. Trauma* **2015**, *29*, 253. [\[CrossRef\]](#)
6. Traini, T.; Piattelli, A.; Caputi, S.; Degidi, M.; Mangano, C.; Scarano, A.; Perrotti, V.; Iezzi, G. Regeneration of human bone using different bone substitute biomaterials. *Clin. Implant Dent. Relat. Res.* **2015**, *17*, 150–162. [\[CrossRef\]](#)
7. De Grado, G.F.; Keller, L.; Idoux-Gillet, Y.; Wagner, Q.; Musset, A.-M.; Benkirane-Jessel, N.; Bornert, F.; Offner, D. Bone substitutes: A review of their characteristics, clinical use, and perspectives for large bone defects management. *J. Tissue Eng.* **2018**, *9*, 204173141877681. [\[CrossRef\]](#)
8. Kokubo, T.; Kim, H.M.; Kawashita, M. Novel bioactive materials with different mechanical properties. *Biomaterials* **2003**, *24*, 2161. [\[CrossRef\]](#)
9. Khan, F.; Tanaka, M.; Ahmad, S.R. Fabrication of polymeric biomaterials: A strategy for tissue engineering and medical devices. *J. Mater. Chem. B* **2015**, *3*, 8224. [\[CrossRef\]](#)
10. Winkler, T.; Sass, F.A.; Duda, G.N.; Schmidt-Bleek, K. A review of biomaterials in bone defect healing, remaining shortcomings and future opportunities for bone tissue engineering: The unsolved challenge. *Bone Joint Res.* **2018**, *7*, 232. [\[CrossRef\]](#)
11. Cingolani, A.; Cuccato, D.; Storti, G.; Morbidelli, M. Control of Pore Structure in Polymeric Monoliths Prepared from Colloidal Dispersions. *Macromol. Mater. Eng.* **2018**, *303*, 1700417.

12. Babaie, E.; Bhaduri, S.B. Fabrication aspects of porous biomaterials in orthopedic applications: A review. *ACS Biomater. Sci. Eng.* **2018**, *4*, 1–39. [[CrossRef](#)]
13. Wers, E.; Lefeuve, B.; Pellen-mussi, P.; Novella, A.; Oudadesse, H. New method of synthesis and in vitro studies of a porous biomaterial. *Mater. Sci. Eng. C* **2016**, *61*, 133. [[CrossRef](#)] [[PubMed](#)]
14. Ahumada, M.; Jacques, E.; Calderon, C.; Martínez-gómez, F. *Handbook of Ecomaterials*; Springer International: Cham, Switzerland, 2018; pp. 1–20.
15. Roseti, L.; Parisi, V.; Petretta, M.; Cavallo, C.; Desando, G.; Bartolotti, I.; Grigolo, B. Scaffolds for bone tissue engineering: State of the art and new perspectives. *Mater. Sci. Eng. C* **2017**, *78*, 1246. [[CrossRef](#)]
16. Sheikh, Z.; Sima, C.; Glogauer, M. Bone replacement materials and techniques used for achieving vertical alveolar bone augmentation. *Materials* **2015**, *8*, 2953–2993. [[CrossRef](#)]
17. Lee, J.H.; Yi, G.S.; Lee, J.W.; Kim, D.J. Physicochemical characterization of porcine bone-derived grafting material and comparison with bovine xenografts for dental applications. *J. Periodontal Implant Sci.* **2017**, *47*, 388–401. [[CrossRef](#)]
18. Yuan, N.; Rezzadeh, K.S.; Lee, J.C. Biomimetic scaffolds for osteogenesis. *Recept. Clin. Investig.* **2015**, *2*, PMC4581954.
19. Jo, S.H.; Kim, Y.K.; Choi, Y.H. Histological evaluation of the healing process of various bone graft materials after engraftment into the human body. *Materials* **2018**, *11*, 714. [[CrossRef](#)]
20. Wang, W.; Yeung, K.W.K. Bone grafts and biomaterials substitutes for bone defect repair: A review. *Bioact. Mater.* **2017**, *2*, 224–247. [[CrossRef](#)]
21. Athanasiou, V.T.; Papachristou, D.J.; Panagopoulos, A.; Saridis, A.; Scopa, C.D.; Megas, P. Histological comparison of autograft, allograft-DBM, xenograft, and synthetic grafts in a trabecular bone defect: An experimental study in rabbits. *Med. Sci. Monit.* **2009**, *16*, BR24–BR31.
22. Fernández, M.P.R.; Mazón, P.; Gehrke, S.A.; Calvo-Guirado, J.L.; de Aza, P.N. Comparison of two xenograft materials used in sinus lift procedures: Material characterization and in vivo behavior. *Materials* **2017**, *10*, 623. [[CrossRef](#)] [[PubMed](#)]
23. Cingolani, A.; Grottoli, C.F.; Esposito, R.; Villa, T.; Rossi, F.; Perale, G. Improving bovine bone mechanical characteristics for the development of xenohybrid bone grafts. *Curr. Pharm. Biotechnol.* **2018**, *19*, 1005–1013. [[CrossRef](#)]
24. Grottoli, C.; Ferracini, R.; Compagno, M.; Tombolesi, A.; Rampado, O.; Pilone, L.; Bistolfi, A.; Borrè, A.; Cingolani, A.; Perale, G. A radiological approach to evaluate bone graft integration in reconstructive surgeries. *Appl. Sci.* **2019**, *9*, 1469. [[CrossRef](#)]
25. Facciuto, E.; Grottoli, C.F.; Mattarocci, M.; Illiano, F.; Compagno, M.; Ferrari, R.; Perale, G. Three-Dimensional Craniofacial Bone Reconstruction With SmartBone on Demand. *J. Craniofac. Surg.* **2019**, *30*, 739–741. [[CrossRef](#)] [[PubMed](#)]
26. Secondo, F.; Grottoli, C.F.; Zollino, I.; Perale, G.; Lauritano, D. Positioning of a contextual implant along with a sinus lift anchored with a block of heterologous bone. *Oral Implantol.* **2017**, *10*, 457. [[CrossRef](#)]
27. Stacchi, C.; Lombardi, T.; Ottonelli, R.; Berton, F.; Perinetti, G.; Traini, T. New bone formation after transcrestal sinus floor elevation was influenced by sinus cavity dimensions: A prospective histologic and histomorphometric study. *Clin. Oral Implants Res.* **2018**, *29*, 465–479. [[CrossRef](#)] [[PubMed](#)]
28. Mandelli, F.; Perale, G.; Danti, S.; D'Alessandro, D.; Ghensi, P. Clinical and histological evaluation of socket preservation using smartbone®, a novel heterologous bone substitute: A case series study. *Oral Implantol.* **2018**, *11*, 87.
29. Cingolani, A.; Casalini, T.; Caimi, S.; Klaue, A.; Sponchioni, M.; Rossi, F.; Perale, G. A Methodologic Approach for the Selection of Bio-Resorbable Polymers in the Development of Medical Devices: The Case of Poly (l-lactide-co-ε-caprolactone). *Polymers* **2018**, *10*, 851. [[CrossRef](#)]
30. Slater, M.; Patava, J.; Kingham, K.; Mason, R.S. Involvement of platelets in stimulating osteogenic activity. *J. Orthop. Res.* **1995**, *13*, 655–663. [[CrossRef](#)]
31. Simonpieri, A.; del Corso, M.; Vervelle, A.; Jimbo, R.; Inchingolo, F.; Sammartino, G.; M Dohan Ehrenfest, D. Current knowledge and perspectives for the use of platelet-rich plasma (PRP) and platelet-rich fibrin (PRF) in oral and maxillofacial surgery part 2: Bone graft, implant and reconstructive surgery. *Curr. Pharm. Biotechnol.* **2012**, *13*, 1231–1256. [[CrossRef](#)]

32. Ferracini, R.; Bistolfi, A.; Garibaldi, R.; Furfaro, V.; Battista, A.; Perale, G. Composite xenohybrid bovine bone-derived scaffold as bone substitute for the treatment of tibia plateau fractures. *Appl. Sci.* **2019**, *9*, 2675. [[CrossRef](#)]
33. Boffano, M.; Ratto, N.; Conti, A.; Pellegrino, P.; Rossi, L.; Perale, G.; Piana, R. Can an artificial bone graft give support without osteosynthesis? A preliminary study on mechanical reliability and bone regeneration? *J. Clin. Med.* **2020**, *9*, 1388. [[CrossRef](#)] [[PubMed](#)]



© 2020 by the authors. Licensee MDPI, Basel, Switzerland. This article is an open access article distributed under the terms and conditions of the Creative Commons Attribution (CC BY) license (<http://creativecommons.org/licenses/by/4.0/>).