

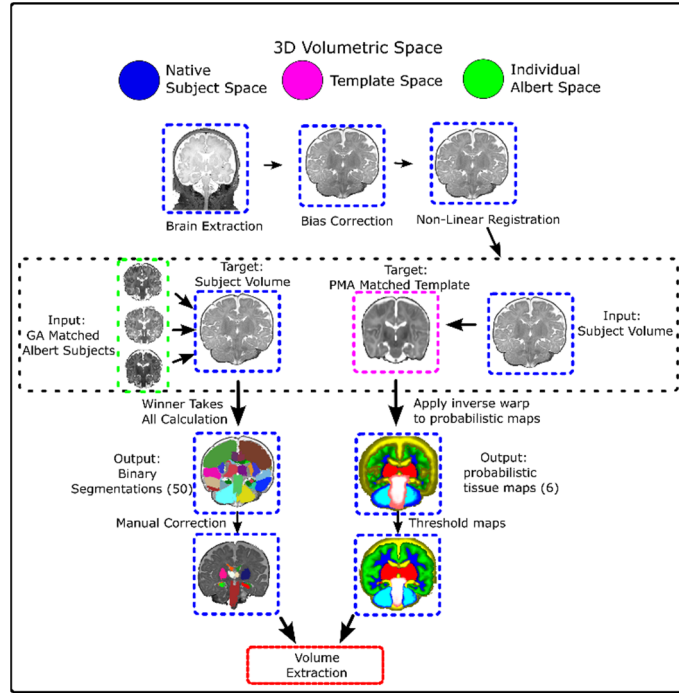Figure S1. Semi-automated structural segmentation. We developed an automated structure segmentation pipeline (with a final manual correction step) that efficiently delineates 50 structures in native subject space. The only input required is a T2 weighted structural MRI.

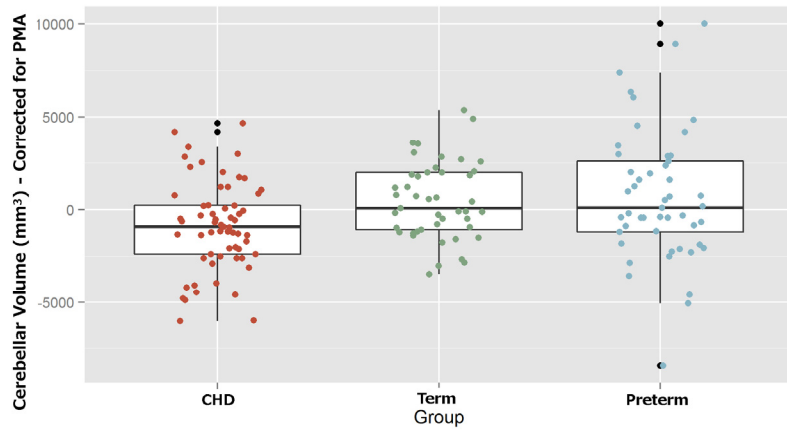


Figure S2. Cerebellar volumes (corrected for PMA) at the time of MRI. Volumes were corrected for post-menstrual age (PMA). CHD neonates showed a significantly lower volume when compared with both preterm born neonates and term born controls. No significant difference between the preterm and control groups was noted. ANOVA p-value < 0.002, with pairwise Tukey's HSD: control-preterm: $p < 0.936$; control-CHD: $p < 0.015$; preterm-CHD: $p < 0.004$.