

Supplementary material

MPO–ANCA-Positive Granulomatosis with Polyangiitis with Rapidly Progressive Glomerulonephritis and Saddle-Nose Deformity: A Case Report

Dimitra Petrou ¹, Minas Karagiannis ¹, Petros Nikolopoulos ¹, George Liapis ² and Sophia Lionaki ^{1,*}

¹ Department of Nephrology, National and Kapodistrian University of Athens, Attikon Hospital, 12462 Athens, Greece; dimitra.petrou90@gmail.com (D.P.); minaskar64@gmail.com (M.K.); nikolopoulospetros@gmail.com (P.N.)

² Department of Pathology, National and Kapodistrian University of Athens, Laiko Hospital, 11527 Athens, Greece; gliapis@gmail.com

* Correspondence: sophial@med.uoa.gr

Citation: Petrou, D.; Karagiannis, M.; Nikolopoulos, P.; Liapis, G.; Lionaki, S. MPO–ANCA-Positive Granulomatosis with Polyangiitis with Rapidly Progressive Glomerulonephritis and Saddle-Nose Deformity: A Case Report. *Antibodies* **2022**, *11*, 33. <https://doi.org/10.3390/antib11020033>

Academic Editor: Loredana Frasca

Received: 27 February 2022

Accepted: 1 May 2022

Published: 9 May 2022

Publisher's Note: MDPI stays neutral with regard to jurisdictional claims in published maps and institutional affiliations.



Copyright: © 2022 by the authors. Licensee MDPI, Basel, Switzerland. This article is an open access article distributed under the terms and conditions of the Creative Commons Attribution (CC BY) license (<https://creativecommons.org/licenses/by/4.0/>).

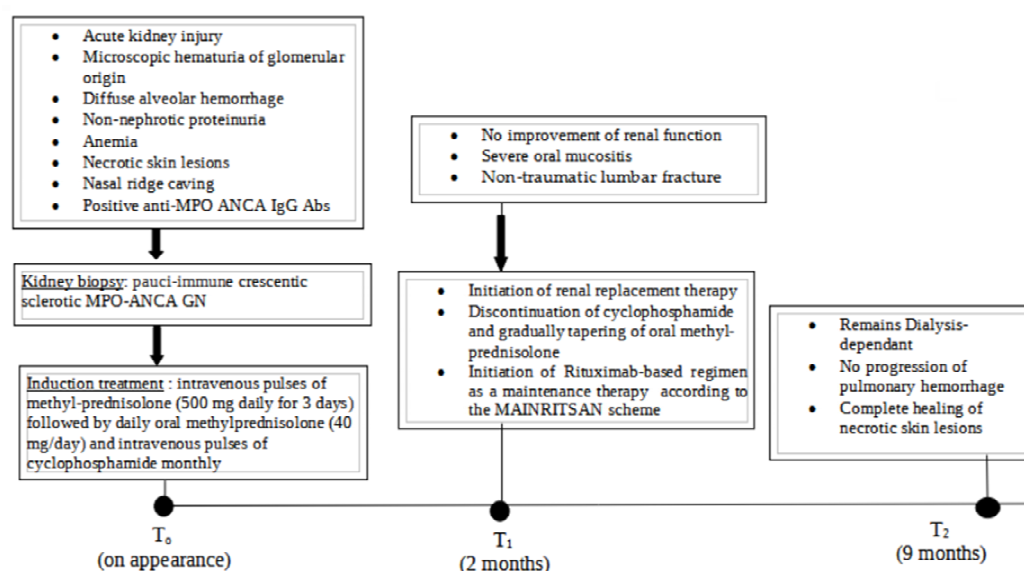


Figure S1. Timeline.