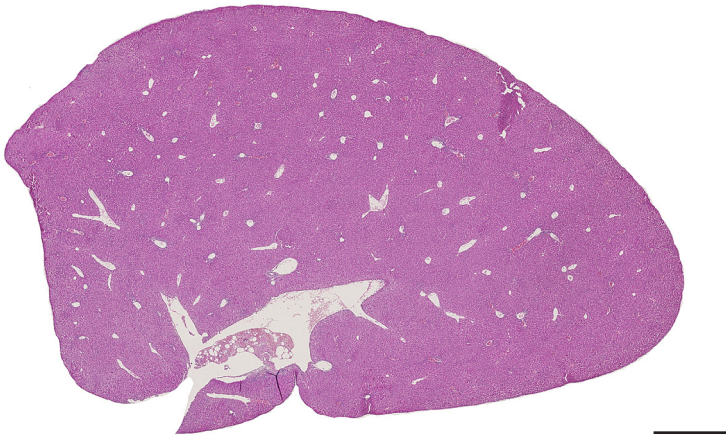
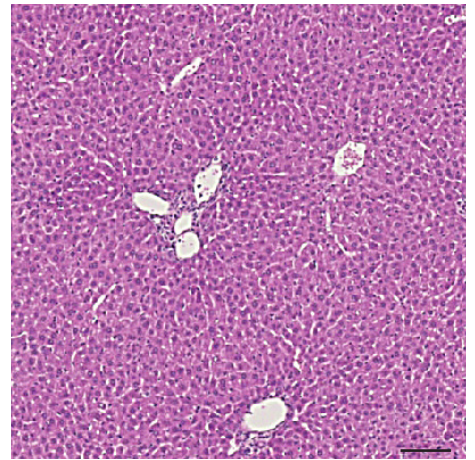


untreated

a

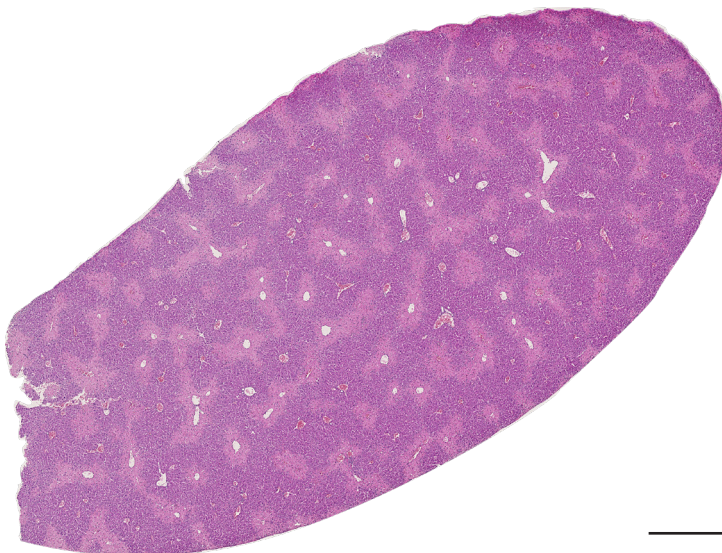


b



CCl₄ treated

c



d

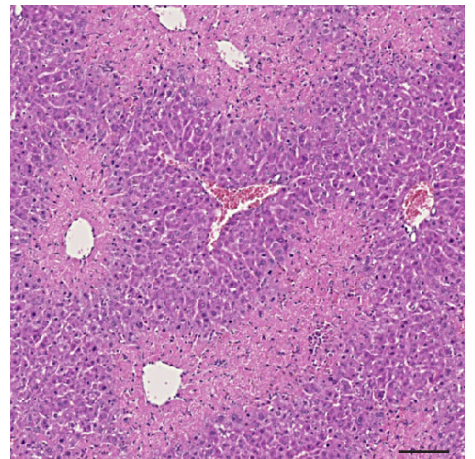


Figure S4. CCl₄ injection causes necrosis of centrilobular hepatocytes.

H&E staining on a section of a wildtype untreated liver (a,b) and 48h after CCl₄ injection (c,d). Scale bars (left): 1 mm, scale bars (right): 100 μ m.