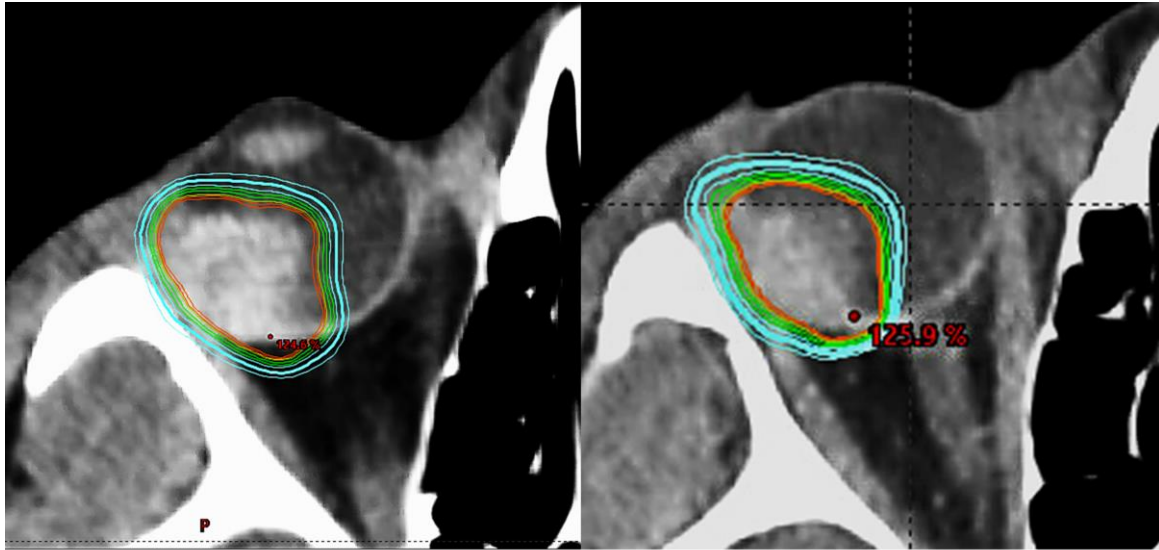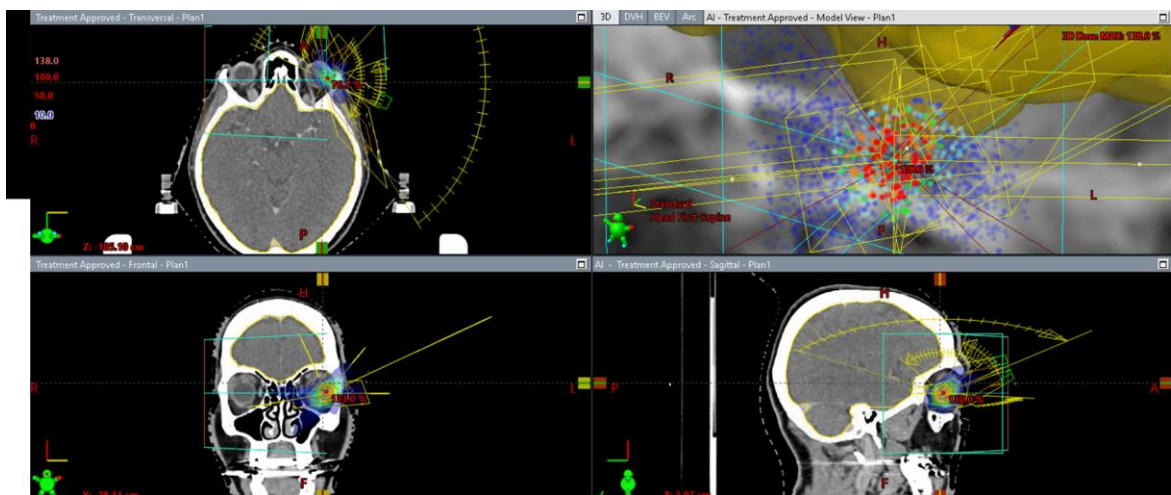


**Figure S1.** LINAC cone-beam computed tomography (CBCT), control CBCT scan onboard with intravenous contrast agent after retrobulbar anaesthesia before SRS; visualization of isodose lines.



**Figure S2.** Treatment plan showing the field alignment and the low dose distribution. The brain is completely blocked to irradiation entrance or exit beams.