

Tumor area in the prediction of baseline symptomatic epilepsy of non-skull base meningiomas

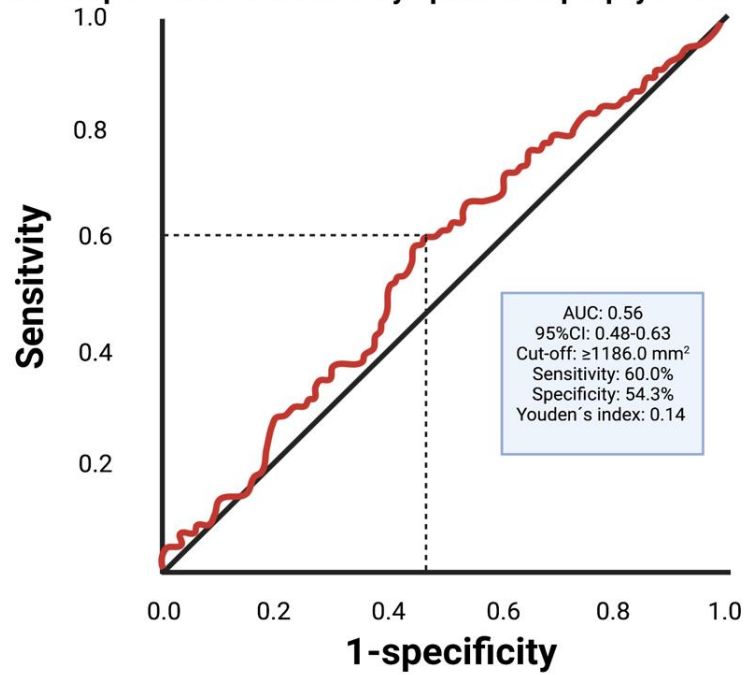


Figure S1. Receiver operating characteristic curve illustrating tumor area in the prediction of preoperative symptomatic epilepsy.

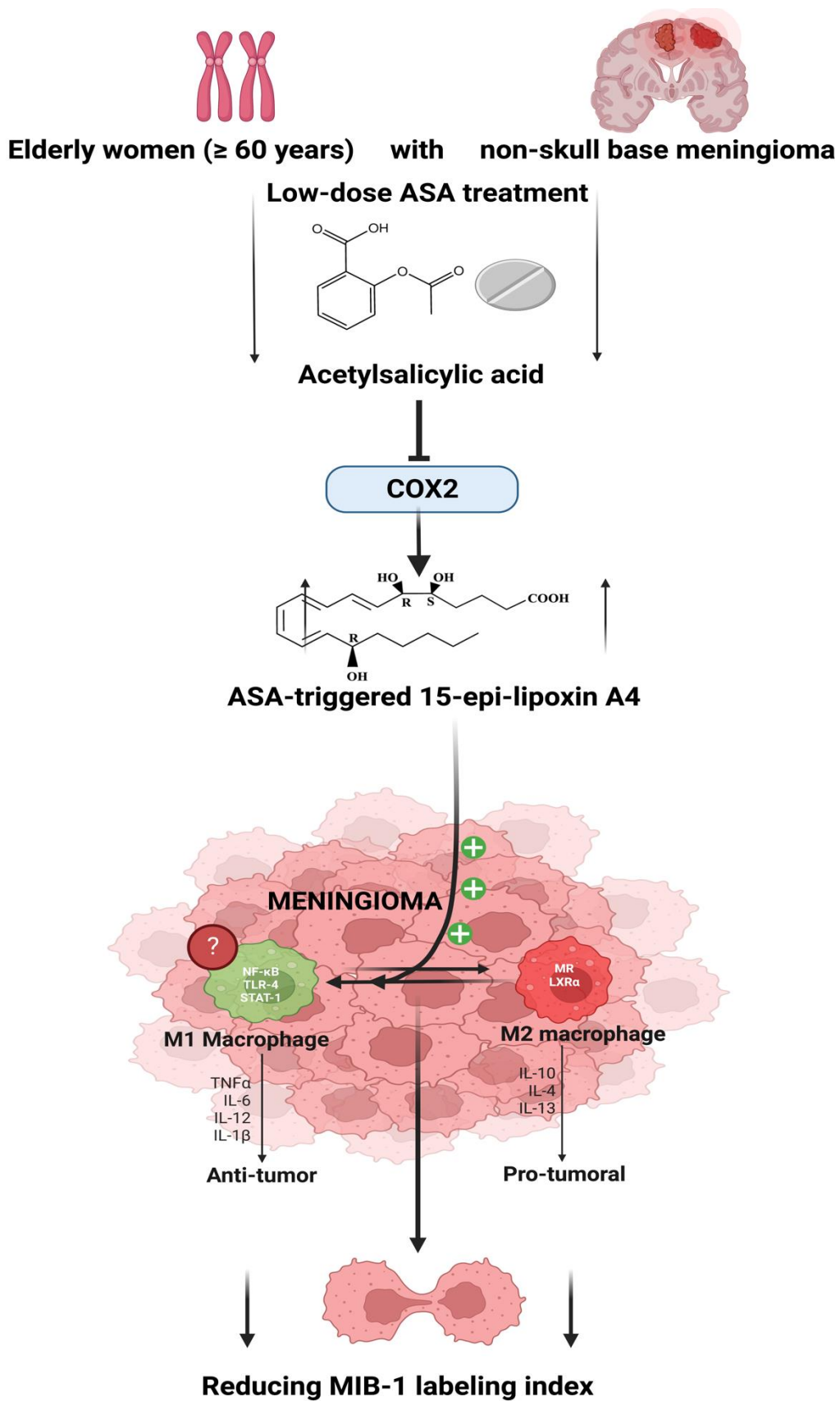


Figure S2. Reduction in MIB-1 labeling index in elderly female non-skull-base meningioma patients by low-dose ASA intake: Hypothesis of a potential pharmacological modulation inducing the formation of M1-phenotype macrophages by ASA-triggered 15-epi-lipoxin A4.