

# Clinical and functional outcome of modified Quad surgery in adult obstetric brachial plexus injury patients: Case reports

Rahul K. Nath, Divya Goel, Chandra Somasundaram

Texas Nerve and Paralysis Institute,  
Houston, TX, USA

## Abstract

Untreated adult obstetric brachial plexus injury (OBPI) patients, in general, use compensatory strategies to achieve their lost upper extremity functions; they cause some adverse effects. Our present study is a case series of 3 female adult OBPI patients, aged 46, 23 and 21 years old. They all had a modified Quad surgical procedure. All patients were assessed preoperatively and postoperatively by evaluating video recordings of standardized upper extremity movements using the modified Mallet scale. The average postoperative follow-up was 4.3 months (1 to 9 months). Total Mallet score significantly improved from 15 and 18 to 21 in two patients. Supination angle measured from active movement of these 3 patients improved from 40°, 0° and -60° to 80°, 40° and -40°, respectively. The modified Quad surgical procedure significantly improves active abduction and other shoulder functions not only in young pediatric and adolescent patients, as we have previously reported, but also in adult patients with muscle imbalance secondary to brachial plexus injury sustained at birth.

## Introduction

Obstetric brachial plexus injury (OBPI) is the result of damage to the nerves during childbirth,<sup>1,2</sup> in some cases causing various hindrances to the correlating shoulder muscles.<sup>2-5</sup> The occurrence of OBPI varies from 0.9 to 5.8 per 1000 live births.<sup>6-10</sup> Due to the muscle imbalances created, sequential bony deformities occur in the joint.<sup>2,11-15</sup> Most frequently, the brachial plexus nerve roots, C5-6,<sup>16</sup> in an infant with OBPI are stretched, and function will be restored naturally.<sup>17</sup> However, some injured patients can have medial nerve damage and continue to demonstrate loss of shoulder function, or alternatively, have damage to many, if not all nerve roots (C5-T1), ranging from neuropraxia to severe cases such as rupture or avulsion.<sup>18</sup> It is seen that OBPI effected

individuals, whose nerve damage has not been repaired spontaneously, demonstrate an asymmetry that includes glenohumeral dysplasia, posterior dislocation or subluxation of the humeral head and contracture of internal rotators, which precedes substantial upper extremity motion loss and the function of the shoulder and abnormalities in elbow flexure.<sup>2,15,19-24</sup>

We and other investigators<sup>25-31</sup> have published extensively on the successful outcomes of various surgical procedures in infants and children with OBPI. However, there is only a limited literature report on adults with untreated OBPI. OBPI in adults causes difficulties in completing daily tasks and therefore the quality of their life.<sup>32</sup> The long-term effects of OBPI include a high propensity for pain exacerbation and worsening ability to move the shoulder with advancing age.<sup>33</sup> These investigators also reported that many of these patients had developed arthritis in the joints and spine.

Another study<sup>34</sup> found that, while the neurological function of patients remained within the normal range of those within the same age group, their patients displayed high rates of comorbid obesity and continued restriction of movement. Long term symptoms of injury are concerning an investigation relating to the treatment of these adults is pertinent. In one of the few publications relating to surgical treatments for adults with OBPI, Werthel *et al.*<sup>35</sup> reported that shoulder arthroplasty diminished pain; however, it did not improve range of motion in adult patients with OBPI that had developed shoulder arthritis as a consequence.

The purpose of this report was to generate an evaluation of three adults with severe OBPI, who did not have surgery as children underwent modified Quad (mod Quad) procedure. The mod Quad surgery is a modification of the combination of muscles released and their insert positions to improve upon a previously described operation.<sup>36</sup>

## Case Reports

### Case #1

A 46-year-old female with left OBPI, who had C5-C7 nerve injury (Table 1). She has no birth history and no Horner's Syndrome. She had contractures at axilla and chest. Therefore, mod Quad surgery was indicated, and she had the surgery at age 46. She also had medial rotation contracture of left shoulder with shortening and loss of external rotation capability.

Correspondence: Rahul K. Nath, Texas Nerve and Paralysis Institute, 6400 Fannin Street, Houston, TX-77030, USA.  
E-mail: drnath@drnathmedical.com

Acknowledgments: the authors thank the patients and families who participated in this study.

Key words: Brachial plexus; Obstetric; Adult; Modified Quad; Shoulder functions.

Contributions: RKN conceived the study, performed the surgery and revised the manuscript. CS and DG participated in the design of the study, gathered data, performed the statistical analysis and drafted the manuscript. All authors read and approved the final manuscript.

Conflict of interest: the authors declare no potential conflict of interest.

Funding: none.

Ethical statement: written informed consent was obtained from all patients for publication and accompanying images. A copy of the written consent is available for review on request.

Institutional Review Board Statement: this was a retrospective study of patient charts, which exempted it from the need for IRB approval in the United States. Patients were treated ethically in compliance with the Helsinki declaration.

Received for publication: 13 February 2019.

Revision received: 30 August 2019.

Accepted for publication: 30 August 2019.

This work is licensed under a Creative Commons Attribution NonCommercial 4.0 License (CC BY-NC 4.0).

©Copyright: the Author(s), 2019  
Licensee PAGEPress, Italy  
Clinics and Practice 2019; 9:1140  
doi:10.4081/cp.2019.1140

### Case #2

A 23-year-old female with left OBPI, who also had C5-C7 nerve injury (Table 1). She had shoulder dystocia. Her birth weight was 8.6 LB. She had no movement on the affected arm at birth, and no instruments were used. She had severe contractures at axilla and chest. Therefore, mod Quad surgery was indicated, and she had the surgery at age 23. She also had elbow flexion contractures. Serial casting/Illizarov stretching was indicated, and the patient had biceps tendon lengthening (BTL) procedure<sup>37</sup> at age 28.

### Case #3

A 21-year-old female patient also with left OBPI, who had a total (C7-C8-T1) brachial plexus nerve injury (Table 1). She had shoulder dystocia and had finger movement at birth; no Horner's Syndrome. Instruments were not used during delivery. Her birth weight was 11.6 LB. She had contractures at axilla and chest. Therefore, mod Quad surgery was indicated, and she had mod Quad surgery at age 21. She also had medial rotation contracture of left shoulder with shortening and loss of external rotation capability.

### Modified Quad procedure

All 3 OBPI adult patients in this study underwent mod Quad procedure.<sup>38</sup> The mod Quad surgery is a modification of the combination of muscles released and their insert positions to improve upon a previously described operation.<sup>36</sup> In the mod Quad operation, the latissimus dorsi, teres major, subscapularis, and pectoralis muscle contractures are released. Additionally, the axillary nerve is neurolysed. We described the detailed mod Quad procedure in our previous publication. In addition, one patient had a BTL procedure<sup>37</sup> to improve her affected arm length.

### Mallet grading

All patients were assessed preoperatively and postoperatively by evaluating video recordings of the following standardized movements using the modified Mallet scale: external rotation, hands to mouth, hands to neck, hands to spine, and supination measured from active movement of these patients.<sup>38</sup> For each functional Mallet parameter, patients were scored on a scale of 1-5 with 5 as normal function and 1 denoting lack of any movement.

### Follow-up

The average postoperative follow-up was 4.3 months (1 to 9 months) (Figures 1-3). Two patients had significant improvement in their shoulder abduction. Preoperative Mallet score improved from 4 to 5 postoperatively in these 2 patients. The third patient in Figure 2 reported that the tightness under the affected area of her arm (contracture at axilla) was better and she had noticeable improvement after the surgery (Table 2 and Figures 1-3). All other shoulder functional movements were improved as well (Table 2 and Figures 1-3). Total Mallet score significantly improved from 15 and 18 to 21 in two patients after modified Quad surgery. Supination angle measured from active movement of these 3 patients improved from 40°, 0° and -60° to 80°, 40° and -40°, respectively.

### Case #1

A series of pre- and postoperative upper extremity movement images of this 46-year-old female patient is given in Figure 1. Preoperatively, she had limited hand to spine movement and limited ability to raise arms above head. She found difficulty in hand to mouth movement and was unable to place her affected hand to neck. Her total Mallet score significantly improved from 15 to 21 after 4 months of mod Quad surgery (Table 2 and Figure 1). Mallet score for hand to neck movement was significantly improved from 2 to 4 (Figure 1D, I).

### Case #2

A series of pre- and postoperative (9 months after mod Quad surgery) upper extremity movement images of a 23-year-old female patient are given in figure 2 (exception: 3 months apart for the 1st column). Preoperatively, the patient found difficulty moving the hand to spine and limited ability to raise arms above the head and placing hands to neck symmetrically.

Supination from active movement; angled hand preoperatively. Postoperative images showing improvements of the patient, 9 months after mod Quad surgery is given in Figure 2. Total mallet score increased from 18 to 21 after the surgery. The patient stated that the tightness under

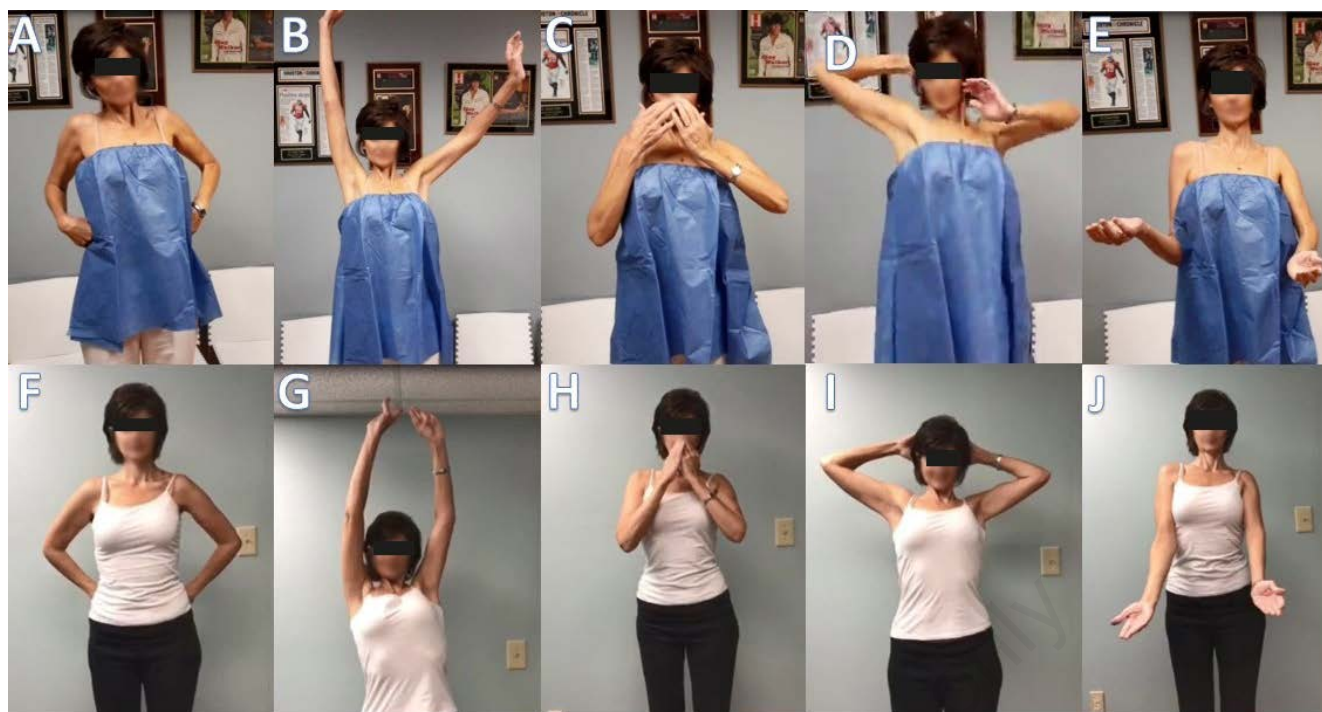**Table 1. Patients' demographics.**

Patient	Age at the time of surgery (years)	Gender	Side of Injury	Nerves involved	Birth history	List of surgeries
1	46	F	L	C5-C7	No birth history; Horner's Syndrome: No	Mod Quad
2	23	F	L	C5-C7	Dystocia: Yes Birth weight: 8.6 LB Horner's Syndrome: No Instruments: None Movement: None	Mod Quad; BTL
3	21	F	L	C5-C8, T1	Dystocia: Yes Birth weight: 11.6 LB Horner's Syndrome: No Instruments: Unknown Movement: Fingers	Mod Quad

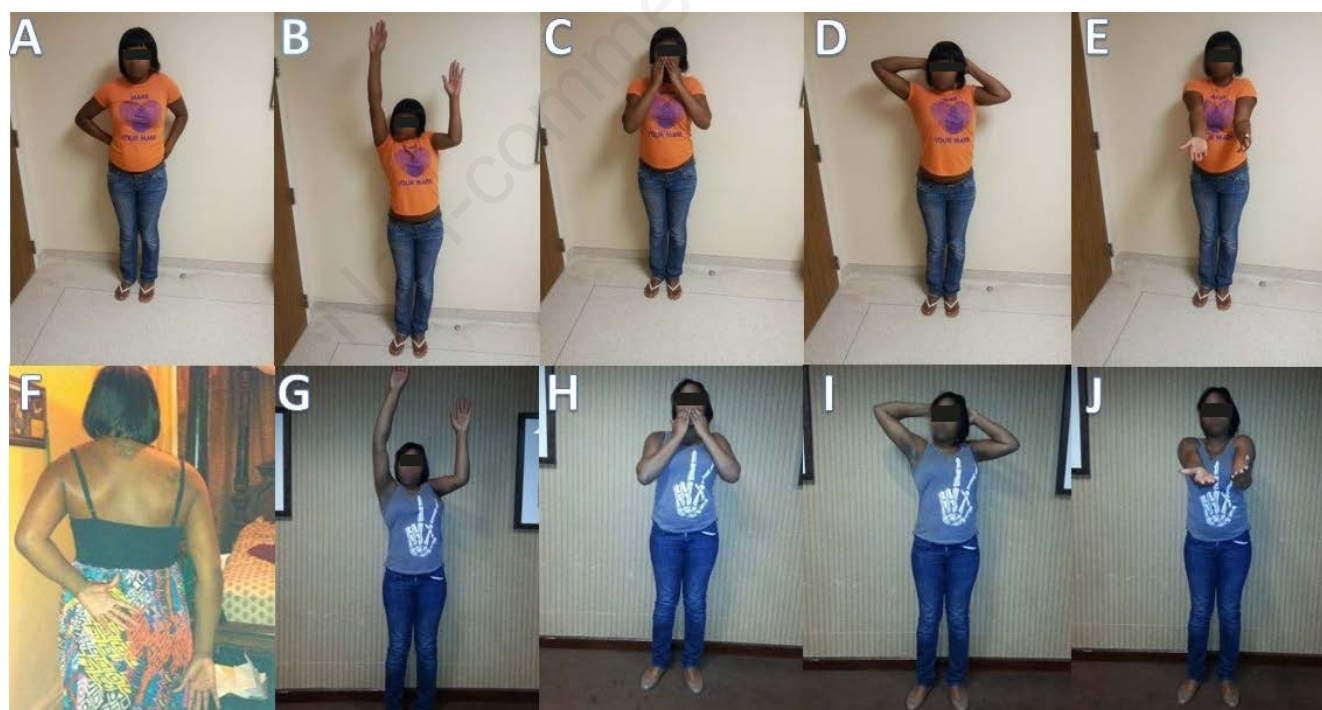
F, female; L, left; BTL, biceps tendon lengthening.

**Table 2. Pre- and post-operative modified Mallet scores after mod Quad surgery.**

Patient	Abduction	Hand to neck	Hand to spine	Hand to mouth	Hand to mouth angle (°)	External rotation	Total Mallet	Supination	Supination Angle (°) from active movement	Follow-up months
1 Pre-op	4	2	3	3	55	3	15	4	40	4
1 Post-op	5	4	4	4	35	4	21	5	80	
2 Pre-op	3	4	2	5	15	4	18	3	0	9
2 Post-op	4	5	3	5	15	4	21	4	40	
3 Pre-op	4	2	2	2	90	3	13	2	-60	1
3 Post-op	5	2		2	90			2	-40	



**Figure 1.** A series of images of a 46-year-old woman with obstetric brachial plexus injury. Follows pre- (upper panel) and postoperative movement (lower panel), 4 months after mod Quad surgery. Upper panel: (A) limited hand to spine movement; (B) limited ability to raise arms above head; (C) difficulty in hand to mouth movement; (D) difficulty in placing hands to the neck; (E) supination with an angled forearm. Lower panel: (F, G, H, I, J) Postoperative images of same patient 4 months after mod Quad surgery relating to same movement as that directly above it. Total Mallet score increased significantly from 15 to 21. Her hand to neck movement increased significantly, from Mallet score 2 to 4.



**Figure 2.** A series of images of a 23-year-old woman with obstetric brachial plexus injury. Follows pre- (upper panel) and postoperative movement (lower panel) - 9 months apart (exception: 3 months apart for first column). Upper panel: (A) difficulty in moving hands to spine; (B) limited ability to raise arms above head; (C) easy and relatively symmetrical hand to mouth movement; (D) difficulty in placing hands to neck symmetrically; (E) supination, angled hand. Lower panel: (F, G, H, I, J) Postoperative images of the same patient after mod Quad procedure relating to same motion as that directly above it. Total Mallet score increased from 18 to 21.



her arm was better in the affected area of the arm, any longer. Her supination angle improved from 0° to 40° after the surgery (Figure 2E, J).

### Case #3

A series of pre- and postoperative upper extremity movement images of 21-year-old female patient is given in Figure 3. Preoperatively, this patient had limited abduction movement and had difficulty in hand to mouth movement, 90° angle. She was unable to place affected hand to neck. Supination; was unable to place her hand face up. There were noticeable improvements in the patient's range of motion; especially her shoulder abduction improved after mod Quad surgery (Figure 3A, E).

## Discussion

The effects of birth trauma can result in life-long morbidity.<sup>39</sup> O'Berry *et al.*<sup>40</sup> found

in their study patients that up to 35% of children with birth palsy had some degree of permanent functional impairment of the affected limb. Soucacos *et al.*<sup>41</sup> reported that severe residual deformities, in general, appear in the affected upper extremity in untreated OBPI adults when compared to treated patients. Shoulder and elbow deformities are often overlooked that cause painful arthrosis in adults.<sup>38</sup>

Gilbert<sup>42</sup> recommended early contracture release in severe cases. He also found that for example, the L'Episcopo technique was less effective if performed after 2 years of age. Butler *et al.*<sup>34</sup> recently reported that long term psychological health and quality of life in young adults with birth related plexus injury. Although these patients could adapt and participate in most activities, they showed persistent functional limitations and a higher rate of comorbid obesity. These authors also found that limitations of the birth injury persisted in both the adolescent and young adult groups as seen by the scoring of the modified Mallet Score and the

Disabilities of the Arm, Shoulder and Hand score.

Further, in their study,<sup>34</sup> 44% of adolescent and 68% of the young adult group were overweight or obese. There was a positive correlation between increased weight, depression, and anxiety. These may be a greater indicator of poor self-concept and increased psychological symptoms in adolescence and young adulthood rather than the injury or impairment due to OBPI. Therefore, weight management has also been suggested as medical intervention in adult OBPI. However, the three adult OBPI patients in our study were not obese.

## Conclusions

The mod Quad procedure greatly improves active abduction and other shoulder functions not only in young pediatric and teen patients (adolescents), as we have previously reported, but also in adult

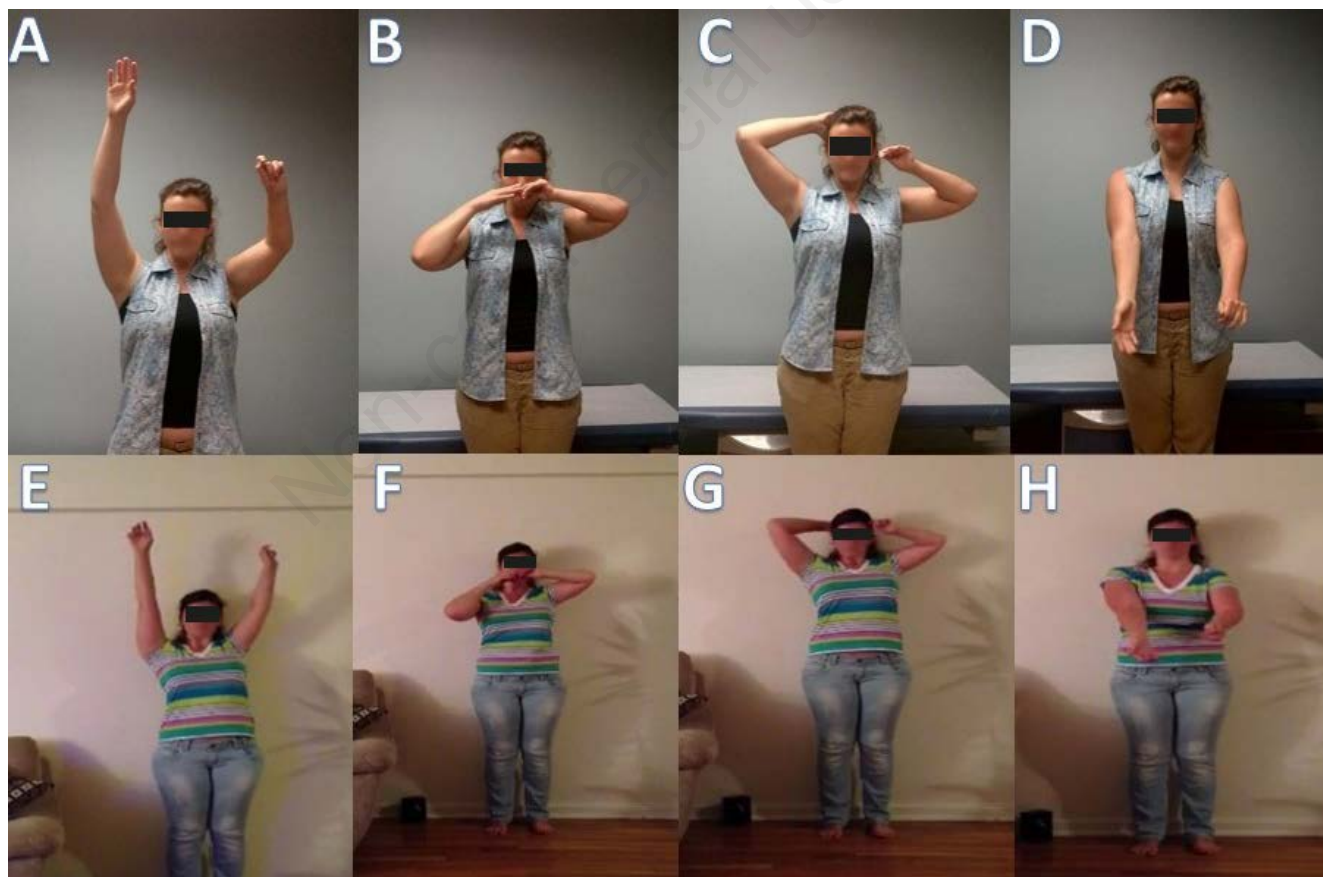


Figure 3. A series of images of a 21-year-old woman with obstetric brachial plexus injury. Follows pre- (upper panel) and postoperative movement (lower panel) -1 month apart. Upper panel: (A) limited abduction movement; (B) difficulty in hand to mouth movement, 90° angle; (C) inability to place hands to the neck; (D) supination, unable to place hand face up. Lower panel: (E, F, G, H) Postoperative images of the same patient following mod Quad surgery relating to same motion as that directly above. There were noticeable improvements in the patient's range of motion; apparent improvement in her shoulder abduction.

patients with muscle imbalance secondary to brachial plexus injury sustained at birth.

## References

- Narakas AO. Injuries to the brachial plexus. In: Bora FW, ed. *The pediatric upper extremity: diagnosis and management*. Philadelphia: W. B. Saunders Company; 1986. pp 247-258.
- Rogers MH. An operation for the correction of the deformity due to "obstetrical paralysis". *Boston Med Surg J* 1916;174:163-4.
- Narakas AO. Obstetrical brachial plexus injuries. In: Lamb DW, ed. *The paralysed hand*. Edinburgh: Churchill-Livingstone; 1987. pp 116-135.
- Birch R, Bonney G, Wynn Parry CB. Birth lesions of the brachial plexus. In: Birch R, Bonney G, Wynn Parry CB, eds. *Surgical disorders of the peripheral nerves*. New York, NY: Churchill Livingstone; 1998. pp 209-233.
- Waters PM, Peljovich AE. Shoulder reconstruction in patients with chronic brachial plexus birth palsy. A case control study. *Clin Orthop Relat Res* 1999;364:144-52.
- Foad SL, Mehlman CT, Ying J. The epidemiology of neonatal brachial plexus palsy in the United States. *J Bone Joint Surg (Am)* 2008;90:1258-64.
- Dahlin LB, Erichs K, Andersson C, et al. Incidence of early posterior shoulder dislocation in brachial plexus birth palsy. *J Brachial Plex Peripher Nerve Inj* 2007;2:24.
- Mollberg M, Wennergren M, Bager B, et al. Obstetric brachial plexus palsy: a prospective study on risk factors related to manual assistance during the second stage of labor. *Acta Obstet Gynecol Scand* 2007;86:198-204.
- Hoeksma AF, Wolf H, Oei SL. Obstetrical brachial plexus injuries: incidence, natural course and shoulder contracture. *Clin Rehabil* 2000;14:523-6.
- Gurewitsch ED, Johnson E, Hamzehzadeh S, Allen RH. Risk factors for brachial plexus injury with and without shoulder dystocia. *Am J Obstet Gynecol* 2006;194:486-92.
- Waters PM, Smith GR, Jaramillo D. Glenohumeral deformity secondary to brachial plexus birth palsy. *J Bone Joint Surg (Am)* 1998;80:668-77.
- Jackson ST, Hoffer MM, Parrish N. Brachial-plexus palsy in the newborn. *J Bone Joint Surg Am* 1988;70:1217-20.
- Liebolt FL, Furey JG. Obstetrical paralysis with dislocation of the shoulder. *J Bone Joint Surg Am* 1953;35-A:227-30.
- Wickstrom J, Haslam ET, Hutchinson RH. The surgical management of residual deformities of the shoulder following birth injuries of the brachial plexus. *J Bone Joint Surg Am* 1955;37-A:27-36.
- Troum S, Floyd WE 3rd, Waters PM. Posterior dislocation of the humeral head in infancy associated with obstetrical paralysis. A case report. *J Bone Joint Surg Am* 1993;75:1370-5.
- Adler JB, Patterson RL, Jr. Erb's palsy. Long-term results of treatment in eighty-eight cases. *J Bone Joint Surg (Am)* 1967;49:1052-64.
- Sever JW. Obstetrical paralysis. Report of eleven hundred cases. *JAMA* 1925;85:1862-5.
- Sunderland S. A classification of peripheral nerve injuries producing loss of function. *Brain* 1951;74:491-516.
- Beischer AD, Simmons TD, Torode IP. Glenoid version in children with obstetric brachial plexus palsy. *J Pediatr Orthop* 1999;19:359-61.
- Birch R, Ahad N, Kono H, Smith S. Repair of obstetric brachial plexus palsy: results in 100 children. *J Bone Joint Surg Br* 2005;87:1089-95.
- Dunkerton MC. Posterior dislocation of the shoulder associated with obstetric brachial plexus palsy. *J Bone Joint Surg Br* 1989;71:764-6.
- Kambhampati SB, Birch R, Cobiella C, Chen L. Posterior subluxation and dislocation of the shoulder in obstetric brachial plexus palsy. *J Bone Joint Surg Br* 2006;88:213-9.
- Kirkos JM, Papadopoulos IA. Late treatment of brachial plexus palsy secondary to birth injuries: rotational osteotomy of the proximal part of the humerus. *J Bone Joint Surg Am* 1998;80:1477-83.
- Moukoko D, Ezaki M, Wilkes D, Carter P. Posterior shoulder dislocation in infants with neonatal brachial plexus palsy. *J Bone Joint Surg Am* 2004;86:787-93.
- Nath RK, Paizi M. Improvement in abduction of the shoulder after reconstructive soft-tissue procedures in obstetric brachial plexus palsy. *J Bone Joint Surg (Br)* 2007;89:620-6.
- Nath RK, Kumar N, Somasundaram C. Modified Quad surgery significantly improves the median nerve conduction and functional outcomes in obstetric brachial plexus nerve injury. *Ann Surg Innov Res* 2013;7:5.
- Waters PM, Bae DS. Effect of tendon transfers and extra-articular soft-tissue balancing on glenohumeral development in brachial plexus birth palsy. *J Bone Joint Surg (Am)* 2005;87:320-5.
- Al-Qattan MM. Total obstetric brachial plexus palsy in children with internal rotation contracture of the shoulder, flexion contracture of the elbow, and poor hand function: improving the cosmetic appearance of the limb with rotation osteotomy of the humerus. *Ann Plast Surg* 2010;65:38-42.
- Kozin SH, Boardman MJ, Chafetz RS, et al. Arthroscopic treatment of internal rotation contracture and glenohumeral dysplasia in children with brachial plexus birth palsy. *J Shoulder Elbow Surg* 2010;19:102-10.
- Gilbert A, Pivato G, Kheiralla T. Long-term results of primary repair of brachial plexus lesions in children. *Microsurgery* 2006;26:334-42.
- Sabapathy SR, Bhardwaj P, Venkatramani H. Value of soft tissue release procedure around the shoulder to improve shoulder abduction in birth brachial plexus palsy and analysis of the factors affecting outcome. *J Hand Surg Asian Pac Vol* 2017;22:174-83.
- Yau CWH, Pizzo E, Prajapati C, et al. Obstetric brachial plexus injuries (OBPIs): health-related quality of life in affected adults and parents. *Health Qual Life Outcomes* 2018;16:212.
- Partridge C, Edwards S. Obstetric brachial plexus palsy: increasing disability and exacerbation of symptoms with age. *Physiother Res Int* 2004;9:157-63.
- Butler L, Mills J, Richard HM, et al. Long-term follow-up of neonatal brachial plexopathy: psychological and physical function in adolescents and young adults. *J Pediatr Orthop* 2017;37:e364-8.
- Werthel JD, Schoch B, Frankle M, et al. Shoulder arthroplasty for sequelae of obstetrical brachial plexus injury. *J Hand Surg Am* 2018;43:871.e1-7.
- Narakas AO. Muscle transpositions in the shoulder and upper arm for sequelae of brachial plexus palsy. *Clin Neurol Neurosurg* 1993;95:S89-91.
- Nath RK, Somasundaram C. Significant improvement in nerve conduction, arm length, and upper extremity function after intraoperative electrical stimulation, neurolysis, and biceps tendon lengthening in obstetric brachial plexus patients. *J Orthop Surg Res* 2015;10:51.
- Birch R. Late sequelae at the shoulder in obstetrical palsy in children. In: Randelli M, Karlsson J, eds. *Surgical techniques in orthopaedics and traumatology: shoulder*. Paris: Elsevier; 2001. pp 55-200.

39. Gottlieb MS. Neglected spinal cord, brain stem and musculoskeletal injuries stemming from birth trauma. *J Manipulative Physiol Ther* 1993;16:537-43.
40. O'Berry P, Brown M, Phillips L, Evans SH. Obstetrical brachial plexus palsy. *Curr Probl Pediatr Adolesc Health Care* 2017;47:151-5.
41. Soucacos PN, Vekris MD, Zoubos AB, Johnson EO. Secondary reanimation procedures in late obstetrical brachial plexus palsy patients. *Microsurgery* 2006;26:343-51.
42. Gilbert A. Long-term evaluation of brachial plexus surgery in obstetrical palsy. *Hand Clin* 1995;11:583-95.

Non-commercial use only