

Simple partial status epilepticus manifested as homonymous hemianopsia: a rare intracranial recording

Anna Siatouni,¹ Stylianos Gatzonis,¹
 Andreas Alexopoulos,²
 Nikos Georgakoulas,¹
 Mathildi Papathanassiou,³
 Stefanos Korfiatis,¹ Vaso Zisimopoulou,⁴
 Damianos Sakas¹

¹Epilepsy Surgery Unit, Department of Neurosurgery, University of Athens, School of Medicine, "Evangelismos" Hospital, Athens, Greece; ²Cleveland Clinic Epilepsy Center Neurological Institute, Cleveland, OH, USA; ³Second Radiology Laboratory, University of Athens, "Attikon" Hospital, Athens, Greece; ⁴Department of Neurology, "Evangelismos" Hospital, Athens, Greece

Abstract

A 30-year-old woman with intractable seizures evaluated as surgical candidate. During presurgical evaluation an invasive electroencephalogram was recommended to define the location and extent of epileptogenic zone and relationship to epileptogenic lesion. On third monitoring night the patient complained of persistent homonymous hemianopsia following a habitual seizure. Concurrently, persistent epileptic activity was evident in a small, restricted area around the right calcarine fissure. The ictal discharges persisted for the next 30 h despite high-dose administration of intravenous antiepileptic drugs, until patient was taken to operating room. Simple partial status epilepticus presenting with pure visual symptoms is rare and difficult to diagnose, even more so when presenting with negative visual phenomena. Epileptic etiology of unexplained, paroxysmal negative visual symptoms should be considered in the differential diagnosis in patients with pre-existing epilepsy, as well as patients with no prior history of epilepsy.

Introduction

Visual symptoms as ictal phenomena - auras or seizures arising from the occipital lobe - are well known and may manifest as positive, *i.e.*, elementary or complex visual hallucinations,¹ or less frequently as negative symptoms, *i.e.*, visual loss and cortical blindness.² Simple par-

tial status epilepticus with pure visual symptoms is quite rare partly due to the inherent difficulties in documenting the epileptic nature of the symptoms. Furthermore, routine scalp electroencephalography (EEG) may be normal or non-specific, as only a small area of cortex may be involved.³ We report a patient with complex partial seizures, who developed homonymous hemianopsia as a solid clinical symptom during her invasive video-EEG evaluation.

Case Report

A 30-year-old ambidextrous female with intractable seizures was evaluated in Epilepsy Department as a surgical candidate. Seizure onset was at the age of 17 years, when the patient presented with a prolonged episode of darkening of vision described as *blackening associated with a ventilator-like movement*. She was discharged on carbamazepine monotherapy and remained free of auras and seizures for eight years. At the age of 25 years, the patient started having recurrent complex partial seizures occurring on a weekly basis. At the time of presurgical evaluation, and despite previous adequate trials of six other antiepileptic medications, she had almost daily seizures. These seizures were heralded by a feeling of *jamaïs vu* followed by arrest of activity, wide-eye stare, tremor of the left arm and simple oral automatisms. These episodes usually lasted one minute and were followed by short postictal confusion. The rest of her medical history was unremarkable, and neurological exam was normal. Brain magnetic resonance imaging showed a lesion involving the right mesial temporo-occipital region. Ictal EEG revealed ictal activity consisted of rhythmic delta and low-theta activity over the right temporal region with a maximum at T8/F8, but not at the sphenoidal electrode.

An electrocorticography was recommended in order to define the location and extent of epileptogenic zone and its relationship to the epileptogenic lesion. Subdural grids were implanted covering the right lateral temporal and occipital cortex as well as the basal temporal and mesial occipital regions. One depth electrode was inserted from the right occipital lobe vertical to the longitudinal axis of the hippocampus targeting the ipsilateral mesial temporal structures (Figure 1A). Habitual seizures were recorded allowing us to map the ictal onset zone within the right temporal-occipital region.

On the night of the 3rd monitoring day the patient had two of her typical seizures. Following a brief period of postictal confusion the patient complained of inability to see on her left side. Initial neurological evaluation

Correspondence: Vaso Zisimopoulou, Department of Neurology, "Evangelismos" Hospital, 45-47 Ipsilantou Str, GR 10676, Athens, Greece.
 Tel.: +30-2132041401 - Fax: +30.2132041403.
 E-mail: vzisimopoulou@gmail.com

Key words: Electrocorticography; simple partial status epilepticus; homonymous hemianopsia.

Contributions: all authors reviewed and contributed to the text. AS and SG gathered data on the case, reviewed of literature and wrote the manuscript. NG, SF, VZ, AA, and DS drafting of the text and editing. AS, NG, MP, SF and SG provided background information. NG, MP, SF, AA, VZ and DS revised the manuscript, made substantial amendments and helped for images selection.

Conflict of interest: the authors declare no potential conflict of interest.

Received for publication: 21 January 2016.
 Revision received: 18 February 2016.
 Accepted for publication: 19 February 2016.

This work is licensed under a Creative Commons Attribution NonCommercial 4.0 License (CC BY-NC 4.0).

©Copyright A. Siatouni et al., 2016
 Licensee PAGEPress, Italy
 Clinics and Practice 2016; 6:840
 doi:10.4081/cp.2016.840

showed that consciousness, language and memory were intact and the remainder of the neurological examination thirty minutes after the last complex partial seizure was normal, except for a dense left homonymous hemianopsia. During this time persistent epileptic activity was evident in the right mesial temporo-occipital electrode contacts. Within minutes this activity was well circumscribed to a restricted, relatively small area around the right calcarine fissure (Figure 1B). The ictal discharges persisted for the next 30 hours despite high-dose administration of intravenous phenytoin and levetiracetam (Figure 2). An emergent brain computed tomography was negative for intracranial hemorrhage or other acute changes. The patient's symptoms remained unchanged during this period, until she was taken to the operating room for surgical resection. Pathology was consistent with an oligodendroglioma. Postoperatively, the patient remained free of auras and seizures on antiepileptic medication at stable doses.

Discussion and Conclusions

The abrupt development of a left hemianopsia in our patient accompanied by paroxysmal

activity arising from the right occipital visual cortex underscores the epileptic origin of the patient's visual field deficit. Left homonymous hemianopsia persisted for a period of thirty hours despite treatment with high dose anti-convulsants. Concomitant epileptic activity was recorded only from a small area of the calcarine cortex, corresponding to approximately 8 electrodes, which covered an estimated area of 8 cm² (2×4 cm, given a center-to-center interelectrode distance of 1 cm). Given the deep-seated location of the ictal activity in this patient, and the vertical orientation of the visual cortex with respect to the convexity, it is unlikely that the intracranially recorded discharges would have been evident on scalp EEG recordings. According to Tao *et al.* cortical spikes from a brain area less than 10 cm² may not be distinguishable from the scalp EEG background.⁴ Invasive recordings along with the patient's unilateral symptomatology in this case demonstrate that the epileptic activity remained restricted to the mesial occipital region without evidence of spread to involve other brain regions.

Complete ictal amaurosis has been attributed to seizures of occipital lobe origin, which spread rapidly to involve the contralateral occipital structures.⁵ Ipsilateral spread to the temporal lobe (often times associated with subsequent spread to the contralateral temporal region) gives rise to complex partial seizures that resemble in their manifestations seizures originating from the temporal lobes.⁶ A seizure that begins in the visual cortex and spreads to the temporal limbic structures may present with initial visual symptoms, followed by other sensations referable to the temporal lobe.^{4,7} Unlike the patient's habitual seizures, ictal symptomatology in this instance did not indicate any evolution or subsequent involvement of the temporal lobe. Similar to our patient prolonged ictal visual loss has been reported in the few published cases lasting from hours to days.^{8,9} The underlying mechanisms of simple partial status epilepticus are poorly understood but may be related to the presence of focal well-defined lesions with sufficiently preserved surrounding neuronal inhibition capable to restrict the epileptogenic process.^{3,9} Simple partial status epilepticus presenting with pure visual symptoms is rare and difficult to diagnose, even more so when presenting with negative visual phenomena. As illustrated by this case an epileptic etiology of unexplained, paroxysmal negative visual symptoms should be considered in the differential diagnosis in patients with pre-existing epilepsy, as well as patients with no prior history of epilepsy. Implantation of subdural electrodes to detect seizures not picked up by scalp electrodes can be a diagnostic option if no cause of negative neurological phenomena is revealed.

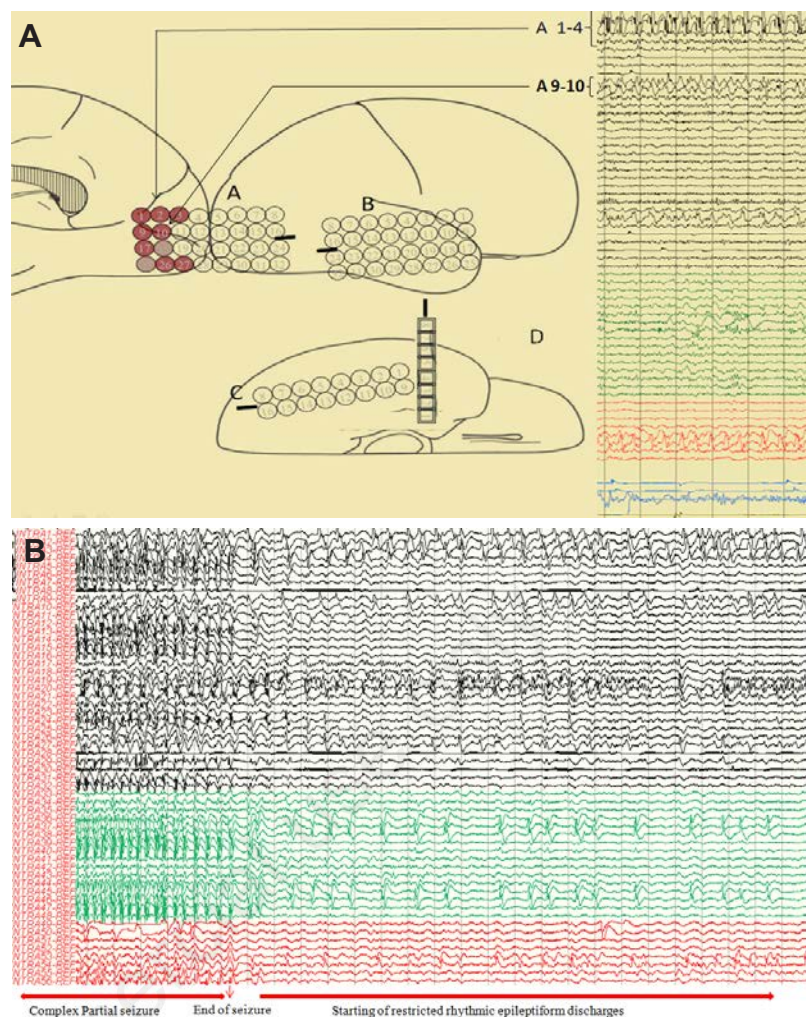


Figure 1. A) Schematic illustration of invasive electrode positions targeting the right temporo-occipital region. Subdural electrode arrays: A: 4×8, B: 4×8, and C: 2×8, and single depth electrode D: 1×8. (B) Epileptiform activity restricted to a small area around the right calcarine fissure (electrodes A1-3, A9-10, A17-18) just after the end of the last habitual seizure.

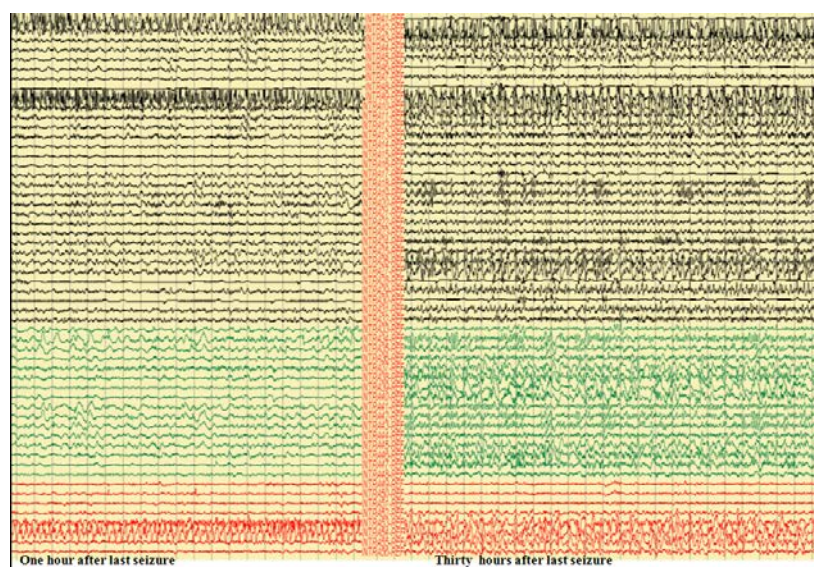


Figure 2. Persistent epileptiform activity to the area around the calcarine fissure 30 h after the end of the last seizure.

References

1. Bien CG, Benninger FO, Urbach H, et al. Localizing value of epileptic visual auras. *Brain* 2000;123:244-53.
2. Hui AC, Tong PY, Wong A, et al. Simple partial status epilepticus in Chinese adults. *J Clin Neurosci* 2005;12:902-4.
3. Meierkord H, Holtkamp M. Non-convulsive status epilepticus in adults: clinical forms and treatment. *Lancet Neurol* 2007;6:329-39.
4. Tao JX, Baldwin M, Hawes-Ebersole S, Ebersole JS. Cortical substrates of scalp EEG epileptiform discharges. *J Clin Neurophysiol* 2007;24:96-100.
5. Barry E, Sussman NM, Bosley TM, Harner RN. Ictal blindness and status epilepticus amauroticus. *Epilepsia* 1985;26:577-84.
6. Tandon N, Alexopoulos AV, Warbel A, et al. Occipital epilepsy: spatial categorization and surgical management. *J Neurosurg* 2009;110:306-18.
7. Salanova V, Andermann F, Olivier A, et al. Occipital lobe epilepsy: electroclinical manifestations, electrocorticography, cortical stimulation and outcome in 42 patients treated between 1930 and 1991. *Surgery of occipital lobe epilepsy. Brain* 1992;115:1655-80.
8. Sowa MV, Pituck S. Prolonged spontaneous complex visual hallucinations and illusions as ictal phenomena. *Epilepsia* 1989;30:524-6.
9. Sawaya R, Radwan W, Alameddine R, Hammoud S. Reversible homonymous hemianopia secondary to occipital lobe seizures. *Seizure* 2014;23:915-7.
10. Williamson PD, Thadani VM, Darcey TM, et al. Occipital lobe epilepsy: clinical characteristics, seizure spread patterns, and results of surgery. *Ann Neurol* 1992;31:3-13.

Non commercial use only