

Comparison of diagnostic ability of storage phosphor plate in detecting proximal caries with direct measurement by stereomicroscope: a pilot study

Velayudhannair Vivek, Sunila Thomas, Bindu J. Nair, Alex Daniel Vineet, Jincy Thomas, Prasanna Ranimol, Aswathy K. Vijayan

Department of Oral Medicine & Radiology, PMS College of Dental Science & Research, Kerala, India

Abstract

Radiography plays an important role in detection of interproximal caries. The aim of study is to compare diagnostic ability of photo stimulable phosphor (PSP) with direct measurement using stereomicroscope in detecting proximal caries. Hundred proximal surfaces of 50 extracted human posterior teeth were radiographed with dental X-ray unit. The image receptors used was storage phosphor plate Vista scan (size 2), (time of exposure 0.4 s). Radiographs were interpreted and caries lesions were classified on a 4-point scale suggested by Abesi *et al.* The teeth were sectioned with diamond disc and were examined under a stereomicroscope with 20x magnification. Diagnostic accuracy of digital image is similar to that observed with stereomicroscope. The PSP plate digital X ray system can effectively be employed for detecting proximal caries as compared to direct observation by stereomicroscope. Further study with more number of observer/evaluator and large sample size is recommended.

Introduction

Diagnosis of caries is mostly based on direct visual examination and intra oral radiography.^{1,2} Intra oral radiography is an established technique for diagnosis of caries especially non cavitated proximal lesions.^{1,2} If diagnosed early the non cavitated proximal lesions can be managed with minimal intervention.^{3,4} The introduction of digital radiographic systems has reduced radiation doses as these digital sensors are more sensitive to radiation than film.^{1,2} The detecting ability of charged coupled device (CCD) and complementary metal oxide semiconductor (CMOS) based digital radiographic systems were com-

pared by several authors and observed that the two modalities are comparable in detecting caries.^{1,2} CCD is now days not so common in the sensor technique. The CMOS technique is the major system by the majority of vendors. CMOS require less system power, longer life span, cheaper & easier to manufacture.⁵ CMOS and photo stimulable phosphor (PSP) (storage phosphor plates) are the system currently in use for digital imaging. Storage phosphor plates has the advantage of being similar in size to conventional film there by enabling easy and similar positioning with position indicating device.⁶ Studies on capability of storage phosphor plates over conventional films in detecting proximal caries are not in plenty.⁶ Stereomicroscopy allows a three dimensional view of teeth in a large examination field which is useful to appreciate the depth and width of progressing carious process.⁷ This study was conducted to compare diagnostic ability of storage phosphor plates with gold standard direct measurements of teeth sections with stereomicroscope in detecting proximal caries.

Materials and Methods

The study was carried out on 50 extracted human posterior teeth (100 dental surfaces) out of which 46 were carious teeth. The teeth were visually inspected for the presence or absence of caries on proximal surfaces. Exclusion criteria included those with extensive buccal or lingual caries and presence of fracture or anomalies. These teeth numbered serially from no. 1 to 100 (Figure 1A) were embedded in plaster of Paris from apex to cemento-enamel junction, with their approximal surfaces in contact. The teeth were radiographed under standardized condition with GNATUS dental radiographic unit (RAIOS X TIMEX 70C) 70 kVp, and 7mA. The image receptor used was 1 durrdental storage phosphor plate (size 2) at 0.4 s (Figure 1B). The exposed phosphor plates were scanned in the Vista scanner (Figure 1C).

Radiographic evaluation

Digital images were examined by a MDS qualified examiner with a 14-year experience. Digital images were viewed on a 15-inch monitor (view sonic) with a resolution of 1366×768 in a well-illuminated room. Radiographs were interpreted and carious lesion were classified based on a 4 point scale (Table 1) ranging from R₀ to R₃.⁸

Histological examination

Direct measurement using stereomicroscope was considered as gold standard of

Correspondence: Velayudhannair Vivek, Depart Department of Oral Medicine & Radiology, PMS College of Dental Science & Research, Golden Hills, Vattappara, Venkode PO, Trivandrum, Pin 695028, Kerala, India.
Tel.: 9447341035.
E-mail vivekv@rediffmail.com

Key words: Proximal caries; intra oral radiography; storage phosphor plate; stereomicroscope; sensitivity.

Conflict of interest: the authors declare no potential conflict of interest.

Contributions: VV, concept, study design, guidance, final correction and approval, X ray analysis; ST, study design, preparation of tabular forms, manuscript correction; BJN, stereomicroscopic evaluation; ADV, JT, PR, manuscript correction; AKV, collection of specimen, mounting, X ray exposure, section preparation and mounting, DTP.

Received for publication: 12 February 2015.

Revision received: 11 May 2015.

Accepted for publication: 23 June 2015.

This work is licensed under a Creative Commons Attribution NonCommercial 3.0 License (CC BY-NC 3.0).

©Copyright V. Vivek *et al.*, 2015
Licensee PAGEPress, Italy
Clinics and Practice 2015; 5:763
doi:10.4081/cp.2015.763

assessment of proximal caries. The previously radiographed teeth were sectioned using a diamond disc mounted in a low speed saw in a mesio-distal direction adjacent to approximal lesions (Figure 2). The sections were subsequently examined under a stereomicroscope with 20x magnification. The caries lesions were classified based on a 4-point scale⁸ ranging from R₀-R₃ by a qualified oral pathologist with 22 years of experience (Figure 3).

Statistical analysis

Analysis was performed to detect all lesions in approximal surfaces in which scale R₀⁸ in the stereomicroscope was considered as negative and scale R₁, R₂ and R₃⁸ in the stereomicroscope were considered as positive. True negative, true positive, false negative and false positive values were calculated from these so that sensitivity, specificity, accuracy, positive predictive value, negative predictive value, positive likelihood ratio, negative likelihood ratio was calculated (Table 2). ROC analysis done and the area under the curve for PSP were found to be 0.850 with a standard error of 0.039 (Figure 4).

Results

Radiographic images captured in PSP plate were evaluated and the results were tabulated along with that obtained from stereomicroscopic readings of the same teeth. PSP evaluation of 100 dental surfaces showed that 42 surfaces were noncarious (R_0), 12 surfaces confined to enamel (R_1), 7 surfaces extended into dentino-enamel junction and outer half of dentin (R_2) and 34 surfaces into inner half of dentin (R_3). Histological examination of 100 dental surfaces showed that 42 surfaces were noncarious (R_0), 16 surfaces confined to enamel (R_1), 7 surfaces extended into dentino-enamel junction and outer half of dentin (R_2) and 35 surfaces into the inner half of dentin (R_3). Comparison of results of PSP plate and stereomicroscope observation of 100 surfaces (50 mesial and 50 distal) revealed that the values were comparable in 78 surfaces, showing that diagnostic accuracy of PSP images are equally good in detecting proximal caries as direct measurements using stereomicroscope which is the gold standard. Results obtained are summarized in Table 3.

Discussion

In this *in vitro* study we compared PSP images of proximal caries with direct measurement using stereomicroscope, which was considered as gold standard in detecting proximal caries. Visual examination was done prior to radiographic and histological examination. Visual examination has the disadvantage of missing hidden caries which is large and demineralized enough to be detected by radiographic and microscopic examination.⁹ Stereomicroscopy allows a three dimensional view of teeth in a large examination field which is useful to appreciate the depth and width of progressing carious process.⁷ The microscopic observations were evaluated

based on the four point scale.⁸ The analysis was performed to detect all lesions in proximal caries. In the present study major samples were having deeper lesions that confined to inner half of dentin (Table 3). The sensitivity of storage phosphor plate in detecting proximal caries in our study, which compared PSP and stereomicroscope, was 80.7% meaning that system was effective in detecting all proximal lesions. In this study where we compared PSP images with direct measurements using stereomicroscope which is the gold standard in detecting proximal caries we found that the diagnostic accuracy of PSP were comparable

with that of stereomicroscope. In detecting approximal caries the diagnostic accuracy of X-ray films, CCD based digital systems and phosphor plates based digital systems with gold standard stereomicroscope were compared by Syriopoulos *et al.* and revealed that there was no difference in the capability of the studied systems.¹ Castro *et al.* in 2007 compared the diagnostic accuracy of conventional film and CMOS (complementary metal oxide semiconductor) with gold standard stereomicroscope and found the two modalities were comparable.² The author discussed that 40% demineralization of hard tissue is required before

Table 1. Scale for assessing caries depth on a 4 point scale from R_0 to R_3 .

Point	Description
R_0	Sound surface
R_1	Caries restricted to enamel
R_2	Caries reaching dentino-enamel junction and outer half of dentin
R_3	Caries reaching inner half of dentin

Table 2. Comparison of result in photo stimulable phosphor and stereomicroscope.

Result	Total number of teeth surfaces	PSP	Stereomicroscope
R_0	84	42	42
R_1	28	12	16
R_2	14	7	7
R_3	69	34	35

PSP, photo stimulable phosphor.

Table 3. Results showing measures of accuracy for all proximal caries.

Indices of diagnostic test accuracy	Results
Sensitivity	80.7%
Specificity	74.4%
Positive predictive value	80.7%
Negative predictive value	74.41%
Accuracy	78%
Positive likelihood ratio	3.15
Negative likelihood ratio	0.256




Figure 1. A) Teeth serially numbered; B) Storage phosphor plate; C) Photo stimulable phosphor images of block with embedded teeth and values.

lesions are identified on radiographs. The present study was in accordance with Castro *et al.* and Syriopoulos *et al.* which revealed that deeper caries lesions were easier to detect by radiographic modalities rather than superficial ones.

In a comparative study by Abesi *et al.*, authors reported a low range of sensitivity 15-38% for enamel caries and a sensitivity of 55-65% for all proximal lesions in their study comparing the diagnostic accuracy of charged couple devices, PSP, and film radiography with gold standard stereomicroscope in detection of proximal caries.⁸ The authors demonstrated that detecting ability of the three radiographic modalities improved more with depth of lesions. Pontual *et al.*, Hintze *et al.* and Farmen *et al.* found that both PSP and conventional film have low sensitivity (14 to 16%) in detecting enamel approximal caries in a study comparing these radiographic modalities with gold standard histological measurements using stereomicroscope.¹⁰⁻¹² The authors were of opinion that the low sensitivity suggests failure of radiographic modalities to detect enamel approximal caries efficiently. In a comparative study by Haiter Neto *et al.* using older and newer versions of PSP and CMOS with gold standard stereomicroscope the authors found a low sensitivity ranging from 15 to 23% in detecting small initial lesions.¹³ This finding is in accordance with the results of earlier studies of detection of proximal lesions by Hintze *et al.*¹⁴ In our study the sensitivity of 80.7% could be explained by the depth of caries lesions as majority of the teeth studied had R₃ lesions.^{1,2}

In a study by Versteeg *et al.* he was of opinion that conventional film was better than PSP in detecting proximal caries.¹⁵ Huda *et al.* observed that PSP was better than conventional film in detecting approximal caries,¹⁶ in spite of conventional film having more spatial resolution. However in both these studies comparison were made based on function of radiation exposure and not stereomicroscope. Pontual *et al.*, Hintze *et al.* and Farmen *et al.* found that both PSP and conventional film have low sensitivity in detecting enamel approximal caries in a study comparing these radiographic modalities with gold standard histological measurements using stereomicroscope.¹⁰⁻¹² This low sensitivity suggests that radiographic modalities failed to detect enamel approximal caries. In a comparative study by Haiter Neto *et al.* using older and newer versions of PSP and CMOS with gold standard stereomicroscope the authors reported a low sensitivity in detecting small initial lesions.¹¹ This finding is in accordance with the results of earlier studies of detection of proximal lesions by Hintze *et al.*¹⁴ who compared conventional film, Radiovisography and PSP systems with gold standard stereomicroscope.

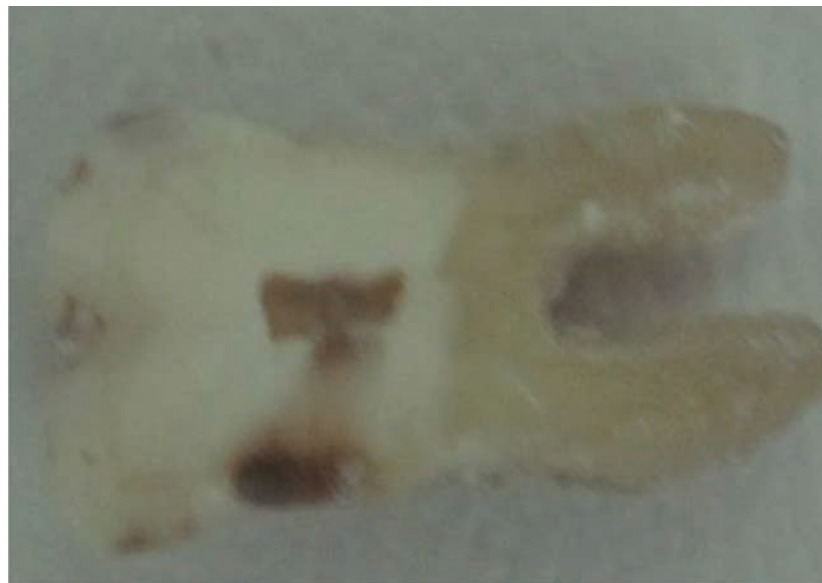

Figure 2. Sectioned teeth.

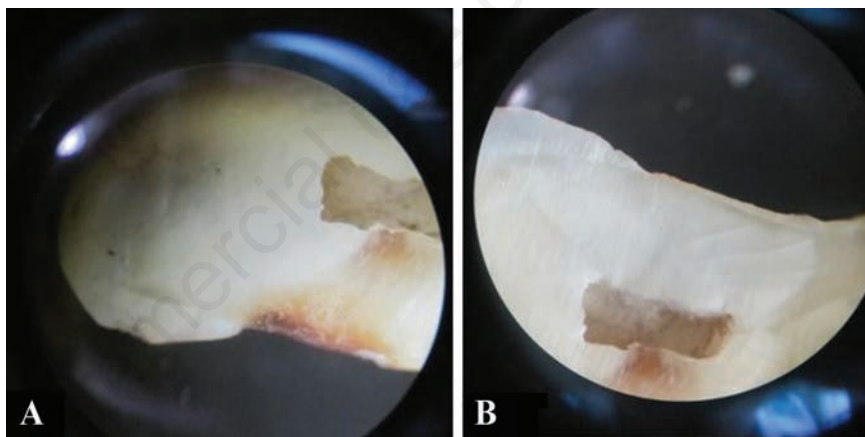


Figure 3. A) Stereomicroscopic section showing caries reaching inner half of dentin R3; B) Stereomicroscopic section showing sound surface R0.

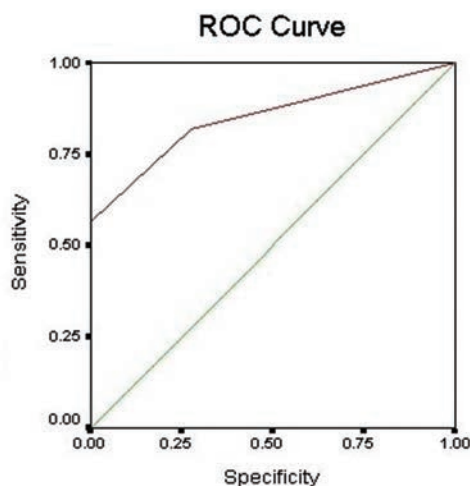


Figure 4. ROC curve.

Zhang *et al.* 2011 compared the accuracy of cone beam computed tomography (CBCT), conventional film and storage phosphor plates in detection of non cavitated proximal caries and found that the accuracy of CBCT in non cavitated proximal caries was similar to that with phosphor plate and film based intra oral images.⁶

The present study is limited by the fact that it was a single observer study where X rays were examined by a single observer and subsequently the stereomicroscope was also examined by a single observer. The sample size was small and most of the samples were having R₃ lesions.

Conclusions

In the present study the result of proximal caries obtained from PSP images were comparable with that of direct measurements using stereomicroscope, which was considered as the gold standard. This showed that digital radiographic method using PSP was equally good as stereomicroscope in detecting proximal caries. In our study most of the studied sample was R₃ lesions. However keeping in view the limitation of our studies further study with more number of observer/evaluator and large sample size may probably establish our results.

References

1. Syriopoulos K, Sanderink GCH, Velders XL, Van der Stelt PF. Radiographic detection of approximal caries: A comparison of dental films and digital imaging systems. *Dento Maxillofac Radiology* 2000;29:312-8.
2. Castro VM, Katz JO, Hardman PK, et al. In vitro comparison of conventional film and direct digital imaging in detection of approximal caries. *Dento Maxillofac Radiology* 2007;36:138-42.
3. Behere RR, Lele SM. Reliability of Logicon caries detector in the detection and depth assessment of dental caries: an in-vitro study. *Indian J Dent Res* 2011;22:362.
4. Bottenberg P, Jacquet W, Stachniss V, et al. Detection of cavitated or non-cavitated approximal enamel caries lesions using CMOS and CCD digital X-ray sensors and conventional D and F-speed films at different exposure conditions. *Am J Dent* 2011;24:74-8.
5. Paurazas SB, Geist JR, Pink FE, et al. Comparison of diagnostic accuracy of digital imaging by using CCD and CMOS-APS sensors with E-speed film in the detection of Periapical bony lesions. *Oral Surg Oral Med Oral Pathol Oral Radiol Endod* 2000;89:356-62.
6. Zhang Z, Qu X, Li G, et al. The detection accuracies for proximal caries by cone-beam computerized tomography, film and phosphor plates. *Oral Surg Oral Med Oral Radiol Endod* 2011;111:103-8.
7. Oancea R, Vasile L, Marchese C, Savarosianu R. Stereomicroscopic study of human tooth caries: clinical morphological correlation. *Proc. SPIE 8427, Biophotonics: Photonic Solutions for Better Health Care III*, 842740 (8 May 2012). Available from: <http://spie.org/Publications/Proceedings/Paper/10.1117/12.923352>
8. Abesi F, Mirshekar A, Moudi E et al. Diagnostic accuracy of digital and conventional radiography in the detection of non cavitated approximal dental caries. *Iran J Radiol* 2012;9:17-21.
9. ertoli FMP, Marques da Silva B, Dalledone M, Losso EM. Hidden caries' challenge diagnosis: case report. *RSBO J* 2013;10:188-92.
10. Hintze H, Wenzel A. Influence of the validation method on diagnostic accuracy for caries. A comparison of six digital and two conventional radiographic systems. *Dentomaxillofac Radiol* 2002;31:44-9.
11. Farman AG, Farman TT. A comparison of 18 different x-ray detectors currently used in dentistry. *Oral Surg Oral Med Oral Pathol Oral Radiol Endod* 2005;99:485-9.
12. Pontual AA, de Melo DP, de Almeida SM, et al. Comparison of digital systems and conventional dental film for the detection of approximal enamel caries. *Dentomaxillofac Radiol*. 2010;39:431-6.
13. Haiter Neto F, dos Anjos Pontual A, Frydenberg M, et al. A comparison of older and newer versions of intraoral digital radiography systems: diagnosing noncavitated proximal carious lesions. *J Am Dent Assoc* 2007;138:1353-9; quiz 82-3.
14. Hintze H, Wenzel A, Jones C. In vitro comparison of D- and E speed film radiography, RVG, and visualix digital radiography for the detection of enamel approximal and dentinal occlusal caries lesions. *Caries Res* 1994;28:363-7.
15. Versteeg KH, Sanderink GC, Velders XL, et al. In vivo study of approximal caries depth on storage phosphor plate images compared with dental x ray film. *Oral Surg Oral Med Oral Pathol Oral Radiol Endod* 1997;84:210-3.
16. Huda W, Rill LN, Benn DK, Pettigrew JC. Comparison of a photostimulable phosphor system with film for dental radiology. *Oral Surg Oral Med Oral Pathol Oral Radiol Endod* 1997;83:725-31.