

Paraspinal arterio-venous fistula in children: two more cases of an exceptional malformation

Nesrine Farhat,¹ Brigitte Desprechins,²
Bernard Otto,² Vincent Ramaekers,¹
Marie-Christine Seghaye¹

Departments of ¹Pediatrics and ²Radiology,
University Hospital Liège, Belgium

Abstract

We report on the case of two toddlers who presented in the last 2 years with heart and vascular murmur, respectively, and in whom the diagnosis of paraspinal arterio-venous fistula was made. Paraspinal arterio-venous fistulae in children are extremely rare congenital or post-traumatic vascular malformations. In the rare case of connection with the spinal venous system, they might affect spinal vascularization due to potential venous congestion. Interventional embolization rather than surgery is the treatment of choice for such lesions. Up to now, there is no consensus about the indication of prophylactic closure of asymptomatic fistulae. However, close clinical follow-up with repeated spinal magnetic resonance imaging to exclude venous congestion is mandatory for young asymptomatic patients until treatment.

Introduction

Paraspinal arterio-venous fistulae in children are exceptional vascular malformations that are diagnosed either incidentally or in the context of neurological complications.

Due to the potential of venous congestion, these fistulae might impair spinal vascularization and must therefore be closed. Interventional embolization rather than surgery is nowadays the treatment of choice.

To the best of our knowledge, only 17 cases of paraspinal arterio-venous fistulae have been reported worldwide in children (Table 1).^{1,2}

We here describe the case of two more toddlers for whom we diagnosed paraspinal arterio-venous fistulae. We discuss etiology, clinical manifestations and treatment of this exceptional malformation.

Case Reports

Case I

An 11-month old boy was addressed to our

cardiological outpatient clinic for investigation of a heart murmur recently discovered by his pediatrician.

Personal and familial history was uneventful. He was born by elective caesarian section and had normal post-natal adaptation. He showed excellent development without any sign of cardiac failure or neurological alteration.

Clinical examination: a 2/6 systolo-diastolic murmur with punctum maximum over the 2nd left intercostal space and the left supra-clavicular region was auscultated. The neurological examination was completely normal.

Complementary examinations:

Echocardiography: ventricular size and function were normal as were flow patterns over AV- and semi-lunar valves. A patent ductus arteriosus could not be identified. Instead of that, a small collateral vessel arising from the distal aortic arch was detected but could not be identified further.

Cervico-thoracic angio-computer tomogram and angio-magnetic resonance imaging (MRI) demonstrated the presence of a vascular malformation. It consisted of an abnormal dilated left cervico-vertebral artery originating from the proximal segment of the descending aorta and feeding a cervico-thoracic paravertebral vascular network which further extended through a slightly dilated intervertebral foramen and connected with slightly dilated veins belonging to the anterior epidural venous plexus. No further dural or subdural vascular abnormalities were objectivized as well as no bone erosion (Figures 1 and 2).

On follow-up MRI's, the stability of the vascular malformation was demonstrated as well as the strict epidural extension. MRI indeed established the absence of intradural venous congestion, medullary compression or edema. Angio-MRI was repeated at 24 and 36 months of age.

Interventional fistula embolization is scheduled.

Case II

A 16-month-old boy was addressed to our consultation because of the presence of a vascular murmur in the right paravertebral lower thoracic area.

Personal and familial history was uneventful.

Clinical examination: 2/6 systolo-diastolic murmur with punctum maximum over the left para-vertebral area of the dorso-lumbar region. Besides that, clinical examination was normal, in particular there was no pulse amplitude difference between upper and lower extremities. There was no sign of cardiac failure or neurological symptoms.

Complementary examinations:

Echocardiography: The cardiac structure and function were normal, in particular, aortic arch and descending aorta showed normal size and flow pattern.

Correspondence: Nesrine Farhat, Department of Pediatrics, University Hospital Liège, Rue de Gaillarmont 600, B. 4032 Liège, Belgium.
Tel.: +32.4.367.92.75 - Fax: +32.4.367.94.29.
E-mail: nesrine_farhat@hotmail.com

Key words: Arterio-venous malformation; paraspinal arterio-venous fistula; children.

Contributions: NF, VR, conception, design, analysis, drafting the manuscript and final approval; BD, BO, conception, design, analysis and interpretation, drafting/revising the manuscript and final approval; M-CS, conception, design, analysis, revising the manuscript and final approval.

Conflict of interest: the authors declare no conflict of interest.

Received for publication: 9 September 2014.

Revision received: 13 December 2014.

Accepted for publication: 17 December 2014.

This work is licensed under a Creative Commons Attribution NonCommercial 3.0 License (CC BY-NC 3.0).

©Copyright N. Farhat et al., 2015

Licensee PAGEPress, Italy

Clinics and Practice 2015; 5:707

doi:10.4081/cp.2015.707

Angio-MRI objectivized the presence of a dorsal paraspinal vascular malformation mainly fed by a right enlarged 10th intercostal artery prolonged by an ectasic intra-foraminal periradicular branch connected with enlarged epidural veins. Less enlarged 9th and 11th intercostal arteries seemed to feed the malformation as well (Figure 3). The absence of dural or epidural vascular anomalies as well as the absence of medullary compression or edema was obvious.

Owing to the young age of the child, fistula embolization is deferred under close follow-up examinations.

Discussion

Paraspinal arterio-venous (AV) fistulas are extremely rare congenital and/or acquired vascular malformations.¹⁻⁵ In contrast to arterio-venous malformations in- and around the spinal cord, they are not associated with a nidus within the spinal canal.³⁻⁶ They are localized outside the Dura but are drained into the epidural veins.^{1,3-7}

A female predominance is reported and the lesions are mostly located in the thoracic region.⁶⁻⁸ They can implicate the paravertebral musculature, nerve root foramina, the paravertebral region and the spinal canal.^{2,4} Their

diagnosis can be difficult^{1,2} but can be strongly suspected by the angio MRI that can show serpiginous or tubular structure located outside the spinal canal and connecting the arterial and venous system.⁶ The proposed diagnosis of paravertebral arterio-venous fistula with strict epidural extension needs however a definitive confirmation with conventional angiography which is the gold standard.^{2,5,6}

The presence of a pulsatile mass, a neurological deficit, signs of heart failure or a mur-

mur discovered incidentally, the latter being the case for both children reported here, are the leading clinical signs.^{4,5,8} These lesions are exceptionally associated with hemorrhagic complications.^{1,2}

Spine lesions are the result of venous congestion.^{1,4,8} The reasons of this congestion are not well known but one of the hypotheses is that there could be an anomaly in the protective venous valvular mechanism allowing a communication between the high flow AV fistula and

the spinal veins.^{2,4,7} Long standing high flow due to the malformation, when it is situated anterior to the vertebra, may lead to osseous erosion with time and may therefore cause orthopedic problems.⁶ Also the dilatation of the epidural venous plexus can lead to compression of neural elements, in particular the exiting nerve roots and, in rare cases, even the cord.⁶

Due to the rarity of this malformation, natural history of such fistulas in young children is unknown. In particular, information about the

Table 1. Summary of reported cases of paraspinous arterio-venous fistulae in children.

Authors, year	Age (y, m), gender	Presentation	Angiographic findings	Treatment	FU (m)	Outcome
Cognard <i>et al.</i> , 1995	17 y, F	Lower back pain	L4 5, L5 S1 AVM	Embolization (balloon)	7	Complete obliteration
Fotso <i>et al.</i> , 2006	3 y, M	Paravertebral murmur	r T-11 AVM	Embolization (coils)	32	Complete obliteration
Goyal <i>et al.</i> , 1999	7 y, M	Scapular murmur	l T-5, l costocervical AVM	Embolization (not precised)	UK	Complete obliteration
	13 y, F	Back pain	l T11-12, r T-11 AVM	Embolization (not precised)	UK	Complete obliteration
	17 y, F	Paraparesis	Multiple intercostal and lumbar AVM	Embolization (not precised)	UK	UK
Hui <i>et al.</i> , 1994	10 y, F	Paraparesis	r C6-7 paraspinous AVM	Embolization (venous platinum coils and arterial NBCA)	8	Complete obliteration
	9 m, M	Congestive heart failure	l T6-7 AVM	Embolization (pure glue)	24	Complete obliteration
	7 m, F	Dysphagia	r ascending and pst cervical AVM	Embolization (67% NBCA and 33% lipiodol)	6	Complete obliteration
Meisel <i>et al.</i> , 1995	1 y, M	Spastic paraparesis	UK	Embolization (not precised)	UK	Complete obliteration
	3 y, M	Spastic paraparesis	UK	Embolization (not precised)	UK	Complete obliteration
	12 y, F	Spastic paraparesis	UK	Embolization (not precised)	UK	Complete obliteration
Niimi <i>et al.</i> , 2005	3 y, M	Paraspinal murmur	l L-3 AVM	Embolization (coils)	115	Complete obliteration
	3 y, F	Interscapular murmur	l T-6 AVM	Embolization (NBCA)	26	Complete obliteration
	2 y, M	Parasternal murmur	l T-7 AVM	Embolization (coils and NBCA)	159	Complete obliteration
	3 y, M	Upper back murmur	r T-7 AVM	Embolization (NBCA)	12	Complete obliteration
	2 y, M	Scapular murmur	l T-5 AVM	Embolization (coils and NBCA)	6	Complete obliteration
Kitagawa <i>et al.</i> , 2009	12 y, F	Acute paraplegia	r T-2 paraspinous AVM	Embolization (Onyx)	12	Complete obliteration
Radiologic findings						
Our cases	11 m, M	Supra-clavicular murmur	l cervico-thoracic paravertebral AVM	/	36	Embolization scheduled
	16 m, M	Paravertebral murmur	r T-10 paraspinous AVM	/	9	Embolization scheduled

y, year; m, month; AVM, arteriovenous malformation; FU, follow-up; pst, posterior; UK, unknown; r, right; l, left; NBCA, N-butyl-cyanocrylate. Adapted from: Kitagawa RS, Mawad ME, Whitehead W, *et al.* Paraspinal arte-

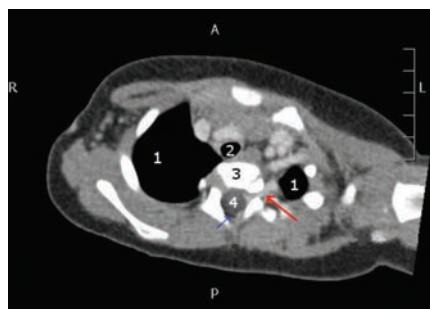


Figure 1. Computed tomography scanner after intra-venous injection of iodinated contrast medium showing a left enhanced and dilated paravertebral vascular structure with intraforaminal, intraspinal and extradural extension (red arrow). 1: Lung; 2: aorta; 3: vertebra; 4: medulla; blue arrow: epidural space.

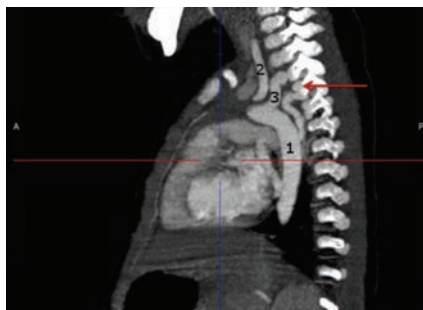

Figure 2. Angio-magnetic resonance imaging: abnormal dilated serpiginous vascular structure (red arrow) originating from the descending aorta with intraforaminal extension. 1: Descending aorta; 2: left vertebral artery; 3: subclavian artery.

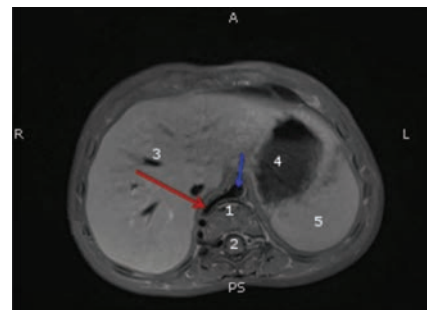


Figure 3. T2 axial image showing abnormally enlarged paravertebral vascular structure (red arrow) with signal void and intraforaminal and intraspinal extradural extension. 1: Vertebra; 2: medulla; 3: liver; 4: stomach; 5: spleen; blue arrow: aorta.

evolution over time of spinal vascularization deficit is lacking.⁷ Thus, the time point of prophylactic closure in asymptomatic patients is not established.

Patients with symptomatic paravertebral AV fistulae were previously treated by surgery but a high probability of recurrent lesions was reported.¹ Nowadays, percutaneous interventional embolization using liquid preparations such as N-butyl-cyanocrylate, glue or a mixture of both is the treatment of choice.^{1,2,4-6,8} Although described to be generally safe, interventional embolization might lead to significant complications such as an incidental venous obstruction of a spinal perimedullary vein with subsequent venous infarction.²

To the best of our knowledge, 17 cases of paraspinal arterio-venous malformation in children have been reported until now. Interestingly, children under 4 years of age are mainly asymptomatic or poorly symptomatic but all older than 10 years of age have neurological manifestations.

Although large series are lacking to permit a consensus about the best time point for arteriography and concomitant embolization of asymptomatic paraspinal arterio-venous fistula in children, it seems reasonable not to delay the procedure beyond the age of 4.

Conclusions

Paraspinal arterio-venous fistulae in children are extremely rare vascular malformations that might impair spinal vascularization due to potential venous congestion. Interventional embolization rather than surgery is the treatment of choice.

Although there is no consensus about the indication of prophylactic closure of asymptomatic fistulae, previous reports and our own 2 cases suggest that patients younger than 4 years old remain asymptomatic but the murmur auscultation. However, close clinical follow-up with repeated spinal MRI to exclude venous congestion is mandatory until invasive treatment.

References

1. Hui E, Trosselo MP, Meisel HJ, et al. Paraspinal arteriovenous shunts in children. *Neuroradiology* 1993;36:69-73.
2. Kitagawa RS, Mawad ME, Whitehead W, et al. Paraspinal arteriovenous malformations in children: case report. *J Neuros-*

Pediatr 2009;3:425-8.

3. Cognard C, Semaan H, Bakchine S, et al. Paraspinal arteriovenous fistula with perimedullary venous drainage. *Am J Neuroradiol* 1995;16:2044-8.
4. Chen C-J, Huang C-C, Hsu Y-Y, Hsu W-C. Small isolated paraspinal arteriovenous fistula. *Am J Neuroradiol* 1997;18:359-61.
5. Fotso A, Aubert D, Saltoun K, et al. Congenital paravertebral arteriovenous fistula: a case report. *J Pediatr Surg* 2006; 41:21-3.
6. Rodesch G, Lasjaunias P. Spinal cord arteriovenous shunts: from imaging to management. *Eur J Radiol* 2003;46:221-32.
7. Goyal M, Willinsky R, Montanera W, TerBrugg K. Paravertebral arteriovenous malformations with epidural drainage: clinical spectrum, imaging features, and results of treatment. *Am J Neuroradiol* 1999;20:749-55.
8. Niimi Y, Berenstein A, Fernandez PM, et al. Pediatric thoraco-lumbar paraspinal arteriovenous fistulas along the segmental nerve diagnosis and endovascular treatment. *J Neuros-Pediatr* 2005;103:156-62.