

# Rare, potentially fatal, poorly understood propofol infusion syndrome

Eva Annen, Thierry Girard,  
Albert Urwyler

Department of Anesthesia and Intensive  
Care Medicine, University Hospital Basel,  
Switzerland

## Abstract

We present the case of a 7-year old boy with traumatic brain injury who received propofol during 38 h. Thirty-six hours after cessation of propofol infusion asystole occurred. After immediate mechanical and medical resuscitation, unreactive dilated pupils were observed. The following computed tomography scan revealed a generalized brain edema with transtentorial herniation. Prolonged bradycardia, rhabdomyolysis, and peracute renal failure were observed. Despite immediate craniectomy, barbiturate treatment, hemofiltration, and recovery of appropriate cardiac function, the patient died four days after discontinuation of propofol. In this case, metabolic acidosis, cardiac failure, rhabdomyolysis, and renal failure are in accordance with the symptoms of propofol infusion syndrome (PRIS), while seizure, brain edema, and transtentorial herniation could be caused by traumatic brain injury. However, it may be assumed that the entire clinical picture was caused by PRIS. This view could be explained by a common loss of function of ryanodine receptors in patients presenting with PRIS.

## Introduction

Propofol infusion syndrome (PRIS) was initially described in 1992 as a syndrome with fatal outcome in critically ill children.<sup>1</sup> Further investigation showed that critically ill adults suffer from identical symptoms after administration of propofol.<sup>2,3</sup> The syndrome was defined by Bray in 1998, describing a *sudden onset of bradycardia, resistant to treatment and progression to asystole plus one of the following: hyperlipidemia, fatty infiltration of the liver, severe metabolic acidosis or muscle involvement with rhabdomyolysis and myoglobinuria*.<sup>4</sup>

The incidence of PRIS is not known. The findings of a multicenter study with 1017 medical and neurosurgical adult patients was published in 2009.<sup>5</sup> This was the first prospective study of incidence of PRIS. Incidence slightly

exceeded 1%, but the short exposure of a maximum 24 h in this study has to be taken into account.

A previous retrospective study of 55 patients receiving propofol for sedation during catheter radiofrequency ablation suggests a higher incidence: 24% (13 of 55) of the patients showed a metabolic acidosis (base excess (BE)  $\leq -2$ ) which was interpreted as the initial indicator of the syndrome.<sup>6</sup>

## Case Report

An alert and well-oriented 7-year old boy presented after being involved in a road traffic accident. He had been hit on the head and right arm by a metal bar. Trauma screening revealed a depressed skull fracture and a fractured distal forearm. The computed tomography (CT) scan of the brain showed a depression of the os parietale with small subcortical contusions, perifocal edema, little intracranial air, but no midline shift.

The patient underwent craniectomy with elevation and fixation of the depressed bone. Intracranial pressure (ICP) monitoring was installed with a combined liquor drain. At the same time, osteosynthesis was performed on the forearm fracture.

Elevated ICP (25 mm Hg) called for a postoperative CT scan; results were unchanged. After surgery, the intubated patient was sedated with propofol (12 mg/kg/h) and transferred to the intensive care unit. pH and serum lactate levels were monitored several times daily, and creatine kinase levels once daily. During sedation with propofol, inotropic support with low-dose norepinephrine was necessary to reach the goal of 60 mm Hg cranial perfusion pressure. A CT scan 36 h later was unchanged. Thereafter, the ICP monitoring was removed. During the same day, metabolic acidosis was observed: pH 7.26, BE -11.1, lactate 2 mmol/L. Hyperchloremic acidosis following 0.9% NaCl infusion and fluid deficiency were assumed and treated.

Propofol infusion was stopped after 39 h. Eight hours later, the patient had a Glasgow coma score of 10, and his trachea was extubated. At that time, generalized muscle weakness and slow awakening were observed. The patient was febrile (39.6°C) without other signs of infection.

Two hours after successful weaning and extubation, the patient was in respiratory distress with aggravating metabolic acidosis (pH 7.19, BE -13.2, lactate 1.6 mmol/L,  $\text{pCO}_2$  5.1 kPa) and was reintubated using succinylcholine. Sedation with propofol was reinstalled for another 11 h (7.3 mg/kg/h) after which the regimen was changed to midazolam and nalbuphine. On the following day, blood tests

Correspondence: Eva Annen, Department of Anesthesia and Intensive Care Medicine, University Hospital Basel, Spitalstrasse 21, CH-4031 Basel, Switzerland.  
E-mail: annene@uhbs.ch

Key words: propofol infusion syndrome, conduction abnormalities, seizure, rhabdomyolysis, ryanodine receptor.

Funding: Departement of Anesthesia and Intensive Care Medicine, University Hospital Basel, Switzerland.

Conflict of interests: the authors declare no potential conflict of interests.

Received for publication: 8 March 2012.

Revision received: 8 March 2012.

Accepted for publication: 30 July 2012.

This work is licensed under a Creative Commons Attribution NonCommercial 3.0 License (CC BY-NC 3.0).

©Copyright E. Annen et al., 2012  
Licensee PAGEPress, Italy  
Clinics and Practice 2012; 2:e79  
doi:10.4081/cp.2012.e79

showed decreasing metabolic acidosis (pH 7.31, BE -6.6, lactate 1.8 mmol/L) but elevated creatine kinase (1023 U/L, reference range 38-157 U/L) and mildly elevated liver enzymes (ASAT 179 U/L, reference range 11-34 U/L, ALAT 174 U/L, reference range 10-37 U/L). Twenty hours after cessation of propofol, generalized seizure was observed under sedation with midazolam and nalbuphine, which was successfully treated with intravenous thiopentone. No change was observed in another CT brain scan performed immediately afterwards.

During the following 6 h, cardiac instability with supraventricular tachycardia up to 180 bpm and peracute renal failure developed. The cardiac conduction abnormalities progressed to bradycardia and asystole. After immediate mechanical and medical resuscitation, the patient presented with unreactive and bilateral dilated pupils and bradycardia that were resistant to therapy. A further CT brain scan (10 h after the previous scan) showed a generalized edema of the brain with obliteration of the basal cisterns and transtentorial herniation. A bilateral decompressive craniectomy was performed immediately. Despite this procedure, intracranial pressure rose and cerebral perfusion pressure could not be maintained.

Nevertheless, renal replacement therapy was installed and cardiac performance improved, and metabolic acidosis could be normalized. Due to persistent rhabdomyolysis (creatinine kinase >100,000 U/L), an open muscle biopsy of the M. quadriceps followed by *in*

*vitro* muscle contracture testing (IVCT) and histological analysis were performed. These investigations were carried out because the clinical signs involved skeletal muscle dysfunctions and because the patient was intubated using succinylcholine, a known trigger agent for malignant hyperthermia (MH). While histology revealed completely normal values, the muscle could not be stimulated electrically for IVCT but presented with spontaneous muscle contracture (Figure 1). These findings are in accordance with a severe dysfunction of excitation-contraction coupling. A blood sample was taken to isolate genomic DNA and investigate for mutations in the gene encoding for the skeletal muscle type 1 ryanodine receptor (*RyR1*) using molecular genetic investigations,<sup>7</sup> but no *RyR1* variant was identified.

Despite high doses of inotropic support, the patient developed progressive cardiac and pulmonary failure. He progressed to liver failure (ASAT >20,000 U/L), rhabdomyolysis (creatinine kinase >100,000 U/L), and coagulopathy (thrombin time >120 s, prothrombin time 48%). The boy died of brain death and multiple organ failure four days and 6 h after discontinuation of the propofol infusion.

## Discussion

The pathophysiology of PRIS is still unclear. Although millions of patients worldwide are sedated with propofol, there have been only a few reports of PRIS. This implies a particular susceptibility of some patients and is, therefore, highly suggestive of a pharmacogenetic disease.

Congenital errors of mitochondrial fatty acid oxidation have been associated with PRIS.<sup>8</sup> Vasile *et al.* hypothesize that the key pathogenetic mechanism is an imbalance between energy demand and utilization through the impairment of free fatty acid utilization and mitochondrial activity, which is generated in the presence of propofol.<sup>3</sup>

Propofol seems to produce a cytochrome oxidase deficiency in muscle tissue, as observed in a child after prolonged high-dose infusion.<sup>9</sup>

The link between free fatty acid metabolism and myocytolysis was found after plasma analysis of a 2-year old boy which showed raised concentrations of malonyl carnitine and C5 acylcarnitine; these returned to normal after recovery.<sup>8</sup> Vasile *et al.* state that these findings indicate that altered long-chain free fatty acid entry into the mitochondrion and uncoupling of beta-oxidation and respiratory chain at complex II are the critical events in PRIS.

Bray and Vasile *et al.* defined the triggering factors to be catecholamines, steroids, cytokine production, and metabolic stress; all

these are present or administered for conditions including polytrauma, multiple organ failure, and severe brain or burn injury. Another suspected risk factor is the method of propofol administration. Cremer *et al.* showed a greater risk with high-dose propofol ( $\geq 5$  mg/kg/h) or prolonged sedation ( $>48$  h).<sup>10</sup>

The postulated risk factors in our patient are young age, brain injury, norepinephrine application, high-dose propofol and a total of 49 h of therapy.<sup>2,3,4</sup>

The hypermetabolic state, rhabdomyolysis, and muscle weakness of our patient suggested some parallels to episodes of MH.<sup>11</sup> Therefore, a muscle sample was taken after obtaining written informed consent from his parents. This muscle sample did not twitch *in vitro* following supramaximal electrical stimulation, but showed spontaneous contracture (Figure 1). These results are suggestive of a disturbance in myoplasmatic calcium homeostasis. Full-length sequencing of the *RyR1* gene did not reveal any DNA variants.

Histological examination of the muscle did not show any abnormal results. In particular, there were no signs of muscle fiber necrosis or rhabdomyolysis. The enzyme-histochemical examination showed neither a structural congenital myopathy nor an abnormal accumulation of mitochondria.

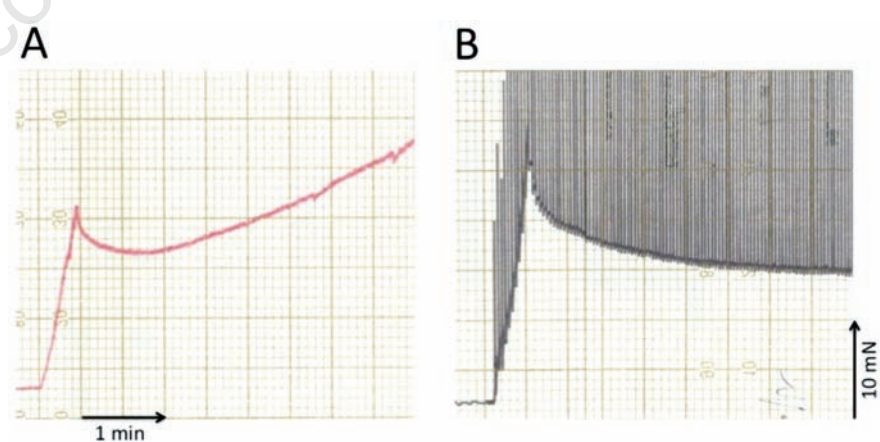
As the involved organs included the brain, heart, and skeletal muscle, and the main symptoms of our patient were metabolic acidosis, seizure, cardiac conduction abnormalities and rhabdomyolysis, we postulate that the key mechanism for the observed dysfunctions in

all three organs involves calcium regulation and, therefore, ryanodine receptors. As a different isoform of the ryanodine receptor (RyR1, RyR2, and RyR3) is involved for each of the organs mentioned above (brain, heart, and skeletal muscle), a common modulator of each of these subtypes of receptors could be the missing link. This view is supported by the fact that RyR1 is present in all 3 organs and that all 3 isoforms of ryanodine receptors are very similar.

Whether the common final pathway of an altered intracellular calcium regulation via a dysfunction of ryanodine receptors is the result of a decreased energy supply due to impaired oxidation in the mitochondria or by alternative direct or indirect effect(s) of propofol on the function of ryanodine receptors are factors in patients presenting with PRIS remains to be clarified.

Metabolic acidosis and rhabdomyolysis lead us to MH, another anesthesia-related disease. The basis for this disorder is the triggering of a sustained rise in intracellular  $\text{Ca}^{2+}$  in skeletal muscle due to hyperactivation of mutated RyR1 channels.<sup>11</sup>

The variability of the clinical presentation and the time differences between the first laboratory findings in published cases with PRIS, as well as the fact that only a small number of individuals in all age groups developed PRIS after anesthesia or sedation using propofol, support the view of PRIS being a pharmacogenetic disorder. The involvement of an altered calcium regulation in PRIS may be an interesting and attractive approach for identifying



**Figure 1.** Original recordings from freshly biopsied skeletal muscle were obtained from the vastus medialis of the quadriceps muscle. Muscle strips approximately 2.5 cm long and approximately 3 mm wide were mounted in a tissue bath and slowly stretched to a pre-load force of approximately 25 mN. The tissue bath, containing Krebs-Ringer solution, was bubbled with carbogen at 37°C. Muscle strips were stimulated electrically in order to produce repeated muscle contractions (*twitches*). (A) A muscle strip of the patient showing a continuously increasing muscle contracture with absolutely no response to electrical stimulation, resulting from the loss of function of excitation-contraction coupling. (B) A muscle strip from a healthy subject. Note the stabilization of the baseline as well as the muscle contractions upon electrical stimulation.

potential genetic alterations in patients presenting with PRIS. PRIS could well be an entity of disorders with an identical common pathway caused by a variety of causative genetic mutations.

## References

1. Parke TJ, Stevens JE, Rice AS, et al. Metabolic acidosis and fatal myocardial failure after propofol infusion in children: five case reports. *BMJ* 1992;102:613-6.
2. Fudickar A, Bein B, Tonner PH. Propofol infusion syndrome in anaesthesia and intensive care medicine. *Curr Opin Anaesthesiol* 2006;19:404-10.
3. Vasile B, Rasulo F, Candiani A, et al. The pathophysiology of propofol infusion syndrome: A simple name for a complex syndrome. *Intensive Care Med* 2003;29:1417-25.
4. Bray RJ. Propofol infusion syndrome in children. *Paed Anaesth* 1998;8:491-9.
5. Roberts RJ, Barletta JF, Fong JJ, et al. Incidence of propofol-related infusion syndrome in critically ill adults: a prospective, multicenter study. *Crit Care* 2009;13:R169.
6. Cravens GT, Packer DL, Johnson ME. Incidence of propofol infusion syndrome during non-invasive radiofrequency ablation for atrial flutter or fibrillation. *Anaesthesiology* 2007;102:1134-8.
7. Levano S, Vukcevic M, Singer M, et al. Increasing the number of diagnostic mutations in malignant hyperthermia. *Hum Mutat* 2009;30:590-8.
8. Wolf A, Weir P, Segar P, et al. Impaired fatty acid oxidation in propofol infusion syndrome. *Lancet* 2001;357:606-7.
9. Cray SH, Robinson BH, Cox PN. Lactic acidemia and bradyarrhythmia in a child sedated with propofol. *Crit Care Med* 1998;26:2089-92.
10. Cremer OL, Moons KG, Bouman EA, et al. Long-term propofol infusion and cardiac failure in adult head injured patients. *Lancet* 2001; 357:117-8.
11. Mickelson JR, Louis CF. Malignant hyperthermia: excitation-contraction coupling, Ca<sup>2+</sup> release channel and Ca<sup>2+</sup> regulation defects. *Physiol Rev* 1996;76:537-92.