

Waugh's syndrome in an adult: report of a very rare disease

Poras Chaudhary, Meenakshi Rao,
Moninder P. Arora

Department of General Surgery, Lady
Hardinge Medical College
and Associated Dr. Ram Manohar Lohia
Hospital, New Delhi, India

Abstract

The authors report a case of Waugh's syndrome in an adult. Waugh's syndrome is rare in adults as most of the cases present in paediatric age group. We have discussed treatment options and it is suggested that the possibility of Waugh's syndrome should always be kept in mind when a case of intussusception is being treated by either operative or non-operative method.

Introduction

Waugh's syndrome commonly presents in infants and children but a rarity in adults. The objective of this report is to document the combination of intussusception and malrotation in an adult and to discuss clinical features and the treatment used in this case.

Case Report

A 25-years-old female patient presented in surgical emergency with complaints of diffuse pain abdomen, associated with vomiting, inability to pass feces and flatus, and distension of abdomen of 4 days duration. General physical examination revealed tachycardia with a pulse rate of 110/min, BP of 106/68 mmHg, dry, coated tongue and temperature of 101 F. Abdomen examination showed distension and features of frank peritonitis and absent bowel sounds. On rectal examination there was currant jelly stools and no growth or mass felt. After resuscitation with crystalloids, x-ray abdomen erect was done which showed multiple air fluid levels, and ultrasonography showed target like mass, dilated fluid filled a peristaltic bowel loops. In view of features of peritonitis, after resuscitation patient was taken up for emergency laparotomy with a probable diagnosis of acute intestinal obstruction secondary to

intussusceptions. Intraoperatively, there were ileocolic intussusceptions. The intussusceptum reached up to mid ascending colon. The involved intestine was discolored from congestion, edema, and haemorrhage into the wall. Duodeno-jejunal flexure was found in an abnormal position,¹ it was lying onto the right of midline. Ileocaecal junction, ascending colon and hepatic flexure were lying in the midline with unfixed caecum and ascending colon (Figures 1-3). In view of gangrenous changes in distal small bowel, resection of distal ileum, caecum and proximal half of ascending colon with end-to-end anastomosis was done. Postoperative period was uneventful and patient was discharged on postoperative day 6.

Discussion

Intussusception in adults originates in distal small bowel near ileocaecal valve secondary a variety of pathologies, which serve as a lead point, but in some cases there may not be a lead point. In Waugh's syndrome, there is no lead point and it is the presence of an abnormally placed gut loops along with unfixed and mobile caecum and ascending colon which might be a precursor for intussusception. Brereton *et al.*¹ who named this association of intussusceptions and malrotation as Waugh's syndrome, after George E. Waugh, suggested that malrotation by its nature is associated with mobile right hemi-colon which may be a predisposing factor for intussusceptions.² Breckon and Hadley reported 6 cases with Waugh's syndrome among 12 intussusception patients.³ Abdominal radiographs and ultrasonography are the primary adjuncts to careful clinical examination. Patients with intussusceptions are optimally managed by air insufflation or hydrostatic enema⁴ in paediatric age group but recommendation in adults is operation.⁵ Surgical intervention becomes necessary when a patient presents with unequivocal peritonitis when the intussusceptions cannot be reduced manually, this generally implies necrosis and a resection and anastomosis is performed. In our case a manual reduction by compression of the colon was not possible because the intussusception was irreducible and resection and end-to-end anastomosis was performed. It is concluded that we should remember that lack of normal rotation and fixation of the intestine and its mesentery is an important factor in the etiology of idiopathic intussusceptions, and failure and recurrence chances are more with non-operative methods.⁶

Correspondence: Poras Chaudhary, Department of General Surgery, Lady Hardinge Medical College and associated Dr. Ram Manohar Lohia Hospital, New Delhi, India.
Tel. +91.9891447358.
E-mail: drporaschaudhary@yahoo.com

Key words: Waugh's syndrome, intussusception, malrotation.

Received for publication: 10 May 2012.
Revision received: 18 June 2012.
Accepted for publication: 5 July 2012.

This work is licensed under a Creative Commons Attribution NonCommercial 3.0 License (CC BY-NC 3.0).

©Copyright P. Chaudhary *et al.*, 2012
Licensee PAGEPress, Italy
Clinics and Practice 2012; 2:e78
doi:10.4081/cp.2012.e78

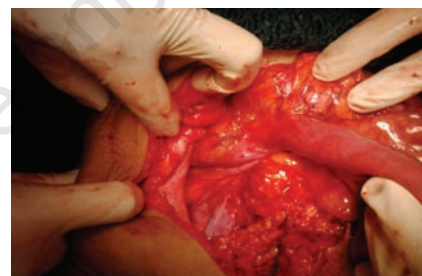

Figure 1. Intraoperative image showing hepatic flexure in the midline.

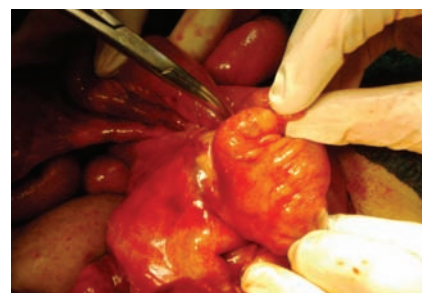

Figure 2. Pointer showing intussusception.

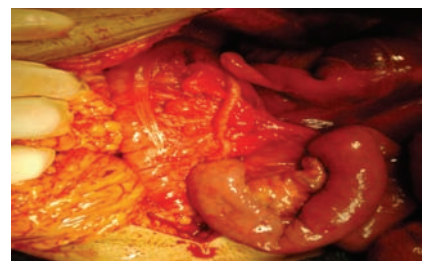


Figure 3. Intraoperative image showing duodeno-jejunal flexure lying onto the right of midline.

References

1. Brereton RJ, Taylor B, Hall CM. Intussusception and intestinal malrotation in infants: Waugh's syndrome. *Br J Surg* 1986;73:55-7.
2. Inan M, Basaran UN, Ayvaz S, Pul M. Waugh's syndrome: report of two cases. *J Pediatric Surg* 2004;39:110-1.
3. Breckon VM, Hadley GP. Waugh's syndrome: a report of six patients. *Pediatr Surg Int* 2000;16:370-3.
4. O'Neill JA Jr (ed). *Pediatric surgery*, 5th ed. St. Louis, MO: Mosby-Year Book. Inc; 1998. pp 1193-1194.
5. Azar T, Berger DL. Adult intussusception. *Ann Surg* 1997;226:134-8.
6. Maoate K, Beasley SW. Perforation during gas reduction of intussusception. *Pediatr Surg Int* 1998;14:168-70.

Non-commercial use only