

Expression of matrix metalloproteinases (MMP-2 and MMP-9) in vocal fold polyps

Vaiva Lesauskaitė, Virgilijus Uloza¹, Vyktas Liutkevičius¹, Dalia Pangonytė

Laboratory of Cardiac Pathology, Institute of Cardiology,

¹Department Otorhinolaryngology, Kaunas University of Medicine, Lithuania

Key words: vocal fold polyps; matrix metalloproteinases; expression; epithelium; stroma cells.

Summary. *Objective.* Vocal fold polyps are the most common benign laryngeal lesions. Matrix metalloproteinases (MMP) play an important role in the physiological and pathological remodeling of tissues. The most important subgroup of MMP family consists of gelatinases A and B (MMP-2 and MMP-9).

The objective of this study was investigation of the expression of MMP-2 and MMP-9 in vocal fold polyps and normal tissue of vocal folds.

Material and methods. The immunohistochemical expression of MMP-2 and MMP-9 was investigated in specimens taken by endolaryngeal microsurgery from vocal fold polyps (n=30) and normal tissue of vocal fold (n=13, control group). Expression of MMP-2 and MMP-9, both in epithelium and stroma cells, was graded on a semiquantitative scale, ranging from 0 (no expression) to 6 points (high expression).

Results. A statistically significant increase was observed in the expression of MMP-2 in stroma cells ($P=0.0176$) of vocal fold polyps compared to control vocal fold group, whereas no significant difference in the expression of MMP-2 was found in epithelium cells ($P=0.1487$). Comparison of expression of MMP-2 and MMP-9 in epithelium cells revealed a statistically significant increase in MMP-9 expression ($P<0.01$) in both groups. However, there was no statistically significant difference in the expression of MMP-9 between groups of vocal fold polyps and control vocal folds.

Conclusion. Expression of MMP-2 in stroma was significantly higher in polyps than in normal tissue of vocal folds. Our data draw attention to the role of MMP-2 in the development of vocal fold polyps and necessity of further investigations to define its function in morphogenesis of laryngeal benign, premalignant, and malignant lesions.

Introduction

Laryngeal polyps are the most common benign lesions of the vocal folds. They account for approximately 39 to 70% of all nodular laryngeal lesions (1–5). Polyps occur only in the vocal fold area, most often on one side. Often the first step to the disease is phonotrauma (brusque movements of vocal fold membrane during phonation). It could be possible that latter leads to the injury of the vessels, hemorrhage, leakage of fibrin, thrombosis, and proliferation of capillaries (6). This pathology can be caused by aggravated tension of vocal folds and by some other factors (dust, smoke, etc.), which affect the mucous membrane of the vocal folds, thus damaging the walls of blood vessel (1).

Recent studies indicate that matrix metallopro-

teinases (MMPs) play an important role in the physiological and pathological remodeling of tissues (7). MMPs are a family of proteolytic zinc- and calcium-containing enzymes, which are responsible for degrading most components of extracellular matrix and basement membrane. There are six subgroups of MMP described; however, the most important subgroup includes gelatinases A and B (MMP-2 and MMP-9) (8, 9). These gelatinases have the capacity to degrade the triple helix type IV and V collagen of basal lamina of the basement membrane (10), thus leading to tissue edema and cell migration through vascular basement membrane (11, 12). MMP-2 and MMP-9 can be produced by keratinocytes, endothelial cells, fibroblasts, osteoblasts, inflammatory, tumor, and other cells (8). Most studies have focused on the prognostic value of

MMP expression in laryngeal cancer growth and spreading to the lymph nodes (9, 13, 14). However, until now just several studies investigated expression of MMP in benign vocal fold lesions (10, 15). To our knowledge, only one study was devoted to investigate expression of MMP-2 and MMP-9 in vocal fold polyps (VFPs), so far (15).

In the present study, we compared the expression of MMP-2 and MMP-9 in VFPs and normal tissue of vocal folds – control vocal folds (CVFs).

Materials and methods

Patients and samples

The VFP group consisted of 30 patients who underwent removal of vocal fold polyps by endolaryngeal microsurgery at the Department of Otorhinolaryngology, Kaunas University of Medicine Hospital (KUMH). The age of the patients ranged from 21 to 69 years (median age, 42 years). There were 18 (60%) males and 12 (40%) females in the VFP group.

Only the cases with typical clinical and histological findings were included in the VFP group. Clinically, nodular lesions localized on the free margin or upper surface of the vocal fold, visually appearing as single lesion of various sizes with a smooth, regular surface, grayish-red to dark-red in color, and distinct margins surrounded by a normal tissue of the vocal fold were considered as a polyp (1–5). Small blood vessels and hemorrhages sometimes were seen through the thin epithelial layer (Fig. 1). Pathohistological diagnosis of VFPs was made at the Department of Pathological Anatomy, KUMH.

Formalin-fixed and paraffin-embedded samples of normal tissues from vocal folds were retrieved from the archives of the Department of Pathological

Anatomy, KUMH. They served as a CVF group. This group consisted of 13 women which age ranged from 23 to 71 years (median, 38 years).

Protocol of the study was approved by Ethics Committee for Biomedical Research of Kaunas region.

Immunohistochemical detection of MMP

Immunohistochemical detection of MMPs was carried out at the Institute of Cardiology, KUMH. Three-micrometer-thick sections were deparaffinized and rehydrated by slide stainer Varistain Gemini (ThermoShandon). Then sections were washed with distilled water and heated in TRIS/EDTA buffer (pH 9.0) for 8 min at 110°C in Microwave Histoprocessor RHS-1 (Milestone, Microwave Laboratory Systems). Shandon Coverplate system was used for immunohistochemical labeling. After blocking the activity of endogenous peroxidases, all slides were incubated in the primary antibody buffer for 1 h at a dilution of 1:100 for MMP-2 (clone 17B11, Novocastra) and MMP-9 (clone 15W2, Novocastra) in antibody diluent (DakoCytomation), followed by sequential 30-min incubations with Advance™ HRP Link and Advance™ HRP Enzyme (DakoCytomation). The binding of antibodies was detected by Liquid DAB+ Substrate-Chromogen System (DakoCytomation). Finally, the sections were counterstained with Mayer's hematoxylin (J. T. Baker) and mounted using xylene-based mounting medium Consul-Mount™ (Shandon).

Expression of MMP-2 and MMP-9 was graded on a semiquantitative scale, ranging from 0 (which represented no expression) to 3 points (which represented the highest expression). Two investigators independently of each other carried out grading, and expression of MMPs was calculated as a score composed of the sum of grades defined by both investigators. Final score ranged from 0 to 6 points: 0, no expression; 1–2, low; 3–4, moderate; and 5–6, high expression (16). The expression of MMP-2 and MMP-9 was graded in epithelium and stroma.

Statistical analysis

The nonparametric Kruskal-Wallis test was used for comparison between VFP and CVF groups. The nonparametric sign test was used to compare measurements in the VFP or CVF group. The results were considered statistically significant when $P \leq 0.05$.

Results

Immunostaining for MMP-9 was detected in all VFP and CVF specimens (100%), both in epithelium and stroma. Nearly two-thirds of the specimens (19




Fig. 1. Polyp of the right vocal fold (direct microlaryngoscopy)

of the 30 cases, 63.3%) taken from VFPs showed cytoplasmic immunostaining for MMP-2 in epithelium. It did not differ ($P=0.0585$) from the prevalence of immunostaining for MMP-2 in the epithelium of CVF specimens (12 of the 13 specimens, 92.3%). All specimens (100%) from VFP showed immunostaining for MMP-2 in stroma. Its prevalence in VFPs was higher ($P=0.0335$) in comparison to CVF group (11 of the 13 cases, 84.6%).

Expression of MMP-2 and MMP-9 in specimens from VFPs and CVFs is presented in Table 1. According to the semiquantitative grading, expression of MMP-9 in epithelial cells of VFPs (range 4 to 6, median score 5) was much higher than MMP-2 (range 0 to 2, median score 1.5; $P=0.000001$) (Fig. 2). The same regularity was valid for expression of MMP-9 and MMP-2 in an epithelium covering normal vocal folds (range 3 to 6, median score 5 and range 0 to 2, median score 2, respectively; $P<0.0015$). However, there was no significant difference in epithelial expression of MMP-9 and MMP-2 between VFP and CVF samples (Table 2). Expression of MMP-2 in stroma was significantly higher in samples from VFPs (range 1 to 6, median 3) than from CVFs (range 0 to 4, median 2, $P=0.0176$) (Fig. 3). Expression of MMP-9 in stroma did not differ between VFP and control groups.

Discussion

In the present study, we compared expression of MMP-2 and MMP-9 in VFPs and normal vocal folds. VFPs have been attributed to vocal abuse that has resulted in a hemorrhagic event or increased vascular permeability (1, 6, 17). The combination of the presence of fibrin, iron pigment in macrophages and signs of recent hemorrhage appeared mostly in vocal fold polyps (6). All these pathological factors can lead to edema and hyaline degeneration of VFP stroma. On the other hand, such area can undergo some organization, including neovascularization and following growth of the polyp (4).

Numerous studies were dedicated to investigate the multiple actions of MMPs in the physiological and pathological remodeling of tissues (10, 11, 14, 18–20, 23). Majority of them analyzed the role of MMPs in morphogenesis of tumors (10, 11, 13, 14, 23). The review dedicated to the mechanisms of invasion and metastatic development of malignant tumors showed that MMPs had ability to degrade extracellular matrices, basement membranes, and other proteins, as well as to decrease cellular immunity (7). Only several studies investigated MMP-2 and MMP-9 expression in laryngeal carcinoma (9, 10, 21–23). It was demonstrated that high expression of MMP-2 in

Table 1. Number of samples that immunostained for MMP-2 and MMP-9 in VFP and CVF groups

Scores of expression	VFP MMP-2 expression		CVF MMP-2 expression		VFP MMP-9 expression		CVF MMP-9 expression	
	epithelium	stroma	epithelium	stroma	epithelium	stroma	epithelium	stroma
0	12	0	1	2	0	0	0	0
1–2	18	11	12	7	0	10	0	6
3–4	0	13	0	4	13	13	3	6
5–6	0	6	0	0	17	7	10	1

Expression is presented as the number of cases with final scores representing the sum of the grades of two investigators (0, none; 1–2, low; 3–4, medium; 5–6, high).

VFP – vocal fold polyp; CVF – control vocal fold; MMP – matrix metalloproteinases.

Table 2. Minimal, maximal, and median scores of the expression of MMP-2 and MMP-9 in VFP and CVF groups

Expression of	VFP			CVF			P
	min	max	median	min	max	median	
MMP-2 epithelium	0	2	1.5	0	2	2	0.1487
MMP-2 stroma	1	6	3	0	4	2	0.0176*
MMP-9 epithelium	4	6	5	3	6	5	0.3002
MMP-9 stroma	2	5	3	1	5	3	0.2317

VFP – vocal fold polyps; CVF – control vocal folds; MMP – matrix metalloproteinases.

*Significant P value (Kruskal–Walis test).

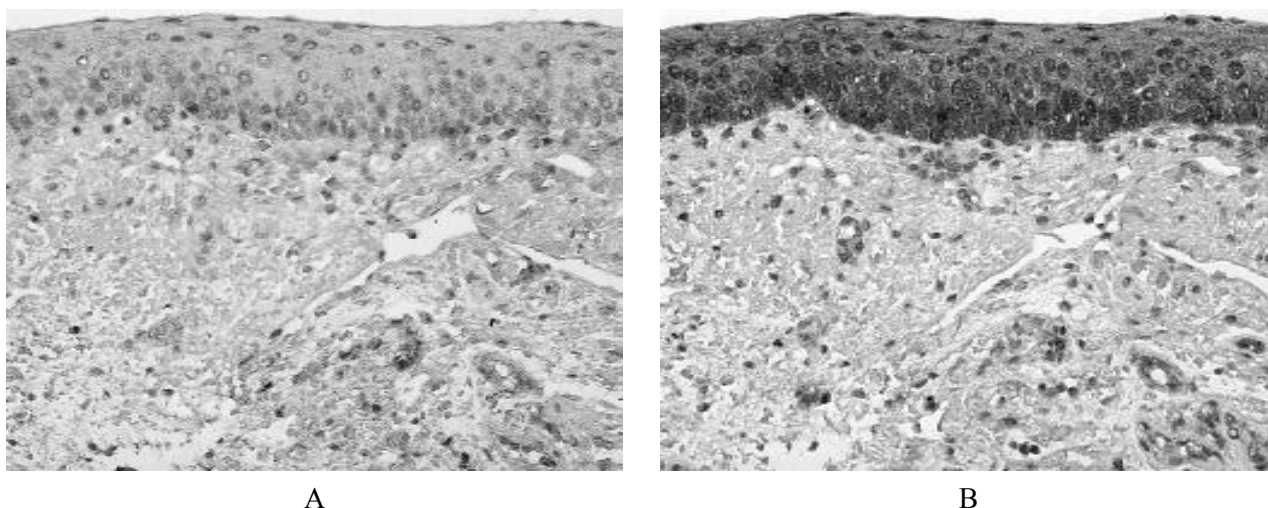


Fig. 2. Immunohistochemical expression of MMP-2, MMP-9 in samples from vocal fold polyps (original magnification, $\times 20$)

Epithelial cells demonstrate a slight expression for MMP-2 (A) and high expression for MMP-9 (B).

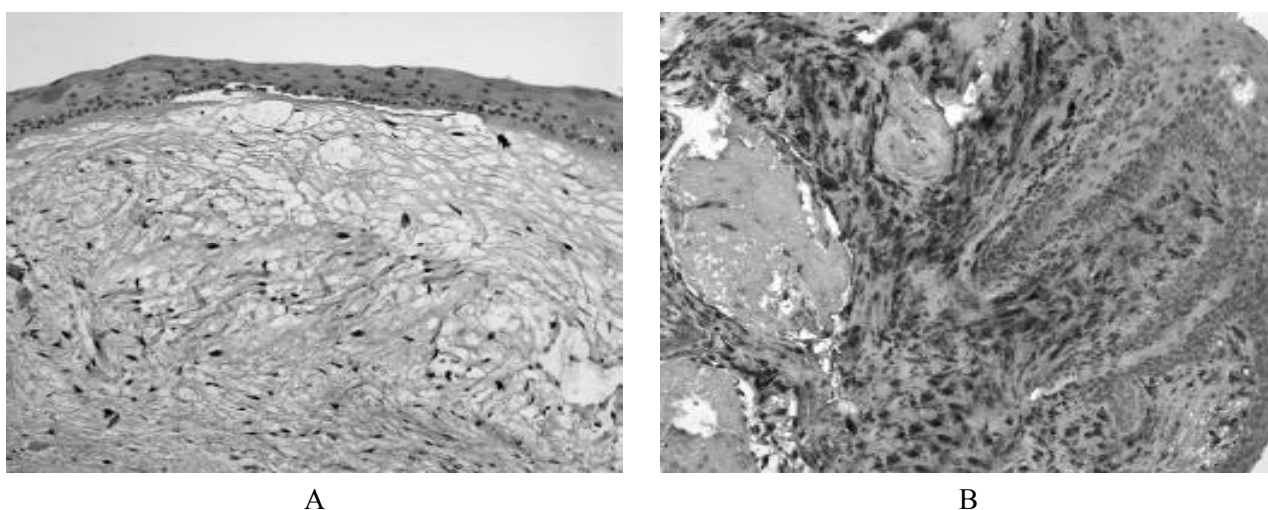


Fig. 3. Immunohistochemical expression of MMP-2 in samples from normal tissue of vocal folds (A) and vocal fold polyps (B) (original magnification, $\times 10$)

Stroma of vocal fold polyps (B) demonstrates a high expression for MMP-2, whereas subepithelial connective tissue from normal vocal folds showed only a weak expression for MMP-2.

laryngeal squamous cell carcinoma indicated poor survival prognosis for patients (9, 23). According to Christopoulos *et al.* (21), immunostaining for MMP-2 and MMP-9 in the tumor cells from laryngeal carcinoma was decreased with increasing stage of cancer. It is of interest that expression level of mRNR of both gelatinases increased as the stage of cancer increased.

Only few studies have been performed to investigate the role of MMPs in morphogenesis of benign tumors in nasopharynx or larynx (15, 18, 19). Chen *et al.* (18) found that MMP-9 was associated with the development of nasal polyps, while other study (19) indicated that MMP-2 might play an important role

in the remodeling of nasal polyps. Bhandari *et al.* (19) observed no MMP-9-positive cells in nasal polyps; however, MMP-2 positivity was present in basal cells in the surface epithelium and in subepithelial tissues (19). These data are in agreement with the results presented in our study. We observed a statistically significant increase in the expression of MMP-2 in stroma cells of VFP as compared to the CVF group. This may suggest an impact of MMP-2 on remodeling and neovascularization in VFP stroma tissue. Similar data were presented by Karahan *et al.* (15). To our knowledge, until now, the latter study was the first to investigate MMP-2 and MMP-9 expression in VFPs and

normal tissue of vocal folds.

Peschos *et al.* (10) draw attention to the expression of MMP-9 in epithelial cells of the larynx. They showed that expression of MMP-9 in carcinoma *in situ* was lower than in invasive carcinoma, although this difference was not statistically significant (10). Our results indicate that expression of MMP-9 in epithelial cells is significantly higher than the expression of MMP-2 both in VFP and CVF groups. However, there was no significant difference in epithelial expression of MMP-2 and MMP-9 between VFP and CVF samples. It can be explained by the fact that in most cases VFP is covered by normal epithelium. Andrian *et al.* (20) showed that normal human oral epithelial cells had a higher expression of MMP-9 mRNA than MMP-2 mRNA.

Conclusions

Expression of MMP-2 in stroma was significant higher in polyps than in normal tissue of the vocal folds. Our data draw attention to the role of MMP-2 in the development of vocal fold polyps and necessity of further investigations to define its function in morphogenesis of benign, premalignant, and malignant lesions.

Acknowledgement

We acknowledge the Department of Pathological Anatomy, KUMH, for histopathological evaluation of tissue samples.

This study was supported by joint-stock company Lietuvos Geležinkeliai.

Matrikso metalo proteinazių (MMP-2 ir MMP-9) ekspresija balso klosčių polipuose

Vaiva Lesauskaitė, Virgilijus Uloza¹, Vyktas Liutkevičius¹, Dalia Pangonytė

Kauno medicinos universiteto Kardiologijos instituto Kardialinės patologijos laboratorija,

¹Ausu, nosies ir gerklės ligų klinika

Raktažodžiai: balso klosčių polipai, matrikso metalo proteinazės, ekspresija, epitelis, stromos ląstelės.

Santrauka. *Tyrimo tikslas.* Balso klosčių polipai – vieni dažniausiai pasitaikančių nepiktybinių gerklų darinių. Matrikso metalo proteinazės (MMP) – tai proteazės, dalyvaujančios fiziologiniuose ir patologiniuose audinių remodeliacijos procesuose. Vienos svarbiausių yra želatinazės A ir B (MMP-2 ir MMP-9). Šio tyrimo tikslas – ištirti MMP-2 ir MMP-9 ekspresijas balso klosčių polipuose ir patologiškai nepakitusiuose balso klosčių audiniuose.

Medžiaga ir metodai. MMP-2 ir MMP-9 ekspresijos tirtos imunohistocheminiu būdu operacijos metu pašalintų 30 balso klosčių polipų grupės histologiniuose preparatuose ir 13 balso klosčių audinių preparatų, kuriuose histologinio tyrimo metu pataloginių pokyčių nepastebėta (kontrolinė grupė). MMP-2 ir MMP-9 ekspresija vertinta pusiau kiekybiniu metodu epitelio ir stromos ląstelėse, balais nuo 0 (nėra ekspresijos) iki 6 (didelė ekspresija).

Rezultatai. MMP-2 ekspresijos padidėjimas stromos ląstelėse buvo statistiškai reikšmingas balso klosčių polipų grupėje lyginant su kontroline grupe ($p=0,0176$), tačiau MMP-2 ekspresija tarp grupių statistiškai reikšmingai nesiskyrė epitelio ląstelėse ($p=0,1487$). MMP-9 ekspresijos padidėjimas epitelyje buvo statistiškai reikšmingas lyginant su MMP-2 ekspresija balso klosčių polipų ir kontrolinėje grupėje ($p<0,01$). Statistiškai reikšmingai MMP-9 ekspresijos padidėjimo balso klosčių polipuose, lyginant su kontroline grupe, nenustatyta.

Išvados. Atlikto tyrimo duomenys patvirtina statistiškai reikšmingai didesnę MMP-2 ekspresiją balso klosčių polipų stromos ląstelėse lyginant su patologiškai nepakitusiais balso klosčių audiniais. Remiantis gautais duomenimis, galima daryti prielaidą apie galimą MMP-2 įtaką balso klosčių polipų formavimuisi bei patvirtina tolesnių tyrimų, skirtų nustatyti MMP reikšmę gerklų nepiktybinių navikų, ikivėžinių ir vėžinių procesų vystymuisi, aktualumą.

Adresas susirašinėti: V. Liutkevičius, KMU ANG ligų klinika, Eivenių 2, 50009 Kaunas

El. paštas: vikisl@yahoo.com

References

1. Uloza V. Atlas of laryngeal diseases. Vilnius: Mokslas; 1986. p. 55-64.
2. Kleinsasser O. Mikrolaryngoskopie und endolaryngeale Mikrochirurgie. Dritte auflage. (Microlaryngoscopy and endolaryngeal microsurgery. 3rd ed.) Stuttgart-New York: Schattauer; 1991. p. 34-8.
3. Lehman W, Pidoux JM, Widmann JJ. Larynx: microlaryn-

- gосcopy and histopathology. Cadempino: Impharzam SA; 1981. p. 68.
4. Tucker HM. The larynx. 2nd ed. New York: Thieme Medical Publishers; 1993. p. 40-43.
 5. Zeitels SM. Atlas of phonosurgery and other endolaryngeal procedures for benign and malignant disease. Delmar: Singular; 2001. p. 37.
 6. Dikkers FG, Nikkels PG. Lamina propria of the mucosa of benign lesions of the vocal folds. *Laryngoscope* 1999;109(10):1684-9.
 7. Švagždy S, Lesauskaitė V. Matrikso metalo proteinazės: piktybinių navikų augimo ir plitimo mechanizmai. (Matrix metalloproteinases: the mechanisms of invasion and metastatic development of malignant tumours.) *Medicinos teorija ir praktika* 2007;13(2):132-8.
 8. Stančiūtė D, Didžiapetrienė J, Kadziauskas J. Matrikso metalo proteinazės sergant piktybiniais navikais. (Matrix metalloproteinases in malignant tumours.) *Medicina (Kaunas)* 2004;40(12):1143-50.
 9. Danilewicz M, Sikorska B, Wagrowska-Danilewicz M. Prognostic significance of the immunoexpression of matrix metalloproteinase MMP2 and this inhibitor TIMP2 in laryngeal cancer. *Med Sci Monit* 2003;9(3):42-7.
 10. Peschos D, Damala C, Stefanou D, Tsanou E, Assimakopoulos D, Vougiouklakis T, et al. Expression of matrix metalloproteinase-9 (gelatinase B) in benign, premalignant and malignant laryngeal lesions. *Histol Histopathol* 2006;21(6):603-8.
 11. Liotta L, Steetler-Stevenson W. Metalloproteinases and cancer invasion. *Semin Cancer Biol* 1990;1:99-106.
 12. Shimizu T, Kanai K, Asano K, Hisamitsu T, Suzaki H. Suppression of matrix metalloproteinase production in nasal fibroblasts by an antiallergic agent, *in vitro*. *Mediators Inflamm* 2005;3:150-9.
 13. Franchi A, Santucci M, Masini E, Sardi I, Paglierani M, Gallo O. Expression of matrix metalloproteinase 1, matrix metalloproteinase 2, and matrix metalloproteinase 9 in carcinoma of the head and neck. *Cancer* 2002;95(9):1902-10.
 14. Görögh T, Beier UH, Bäumken J, Meyer JE, Hoffmann M, Gottschlich S, et al. Metalloproteinases and their inhibitors: influence on tumor invasiveness and metastasis formation in head and neck squamous cell carcinomas. *Head Neck* 2006;28(1):31-9.
 15. Karahan N, Baspinar S, Yarikas M, Kapucuoglu N. Matrix metalloproteinases (MMP-2 and MMP-9) and cyclooxygenase-2 (COX-2) expressions in vocal cord polyps. *J Voice*. 2007 Jul 9 [Epub ahead of print].
 16. Lesauskaitė V, Epistolato MC, Castagnini M, Urbonavicius S, Tanganelli P. Expression of matrix metalloproteinases, their tissue inhibitors, and osteopontin in the wall of thoracic and abdominal aortas with dilatative pathology. *Hum Pathol* 2006;37(8):1076-84.
 17. Gray SD, Hammond E, Hanson DF. Benign pathologic responses of the larynx. *Ann Otol Rhinol Laryngol* 1995;104(1):13-8.
 18. Chen YS, Langhammer T, Westhofen M, Lorenzen J. Relationship between matrix metalloproteinases MMP-2, MMP-9, tissue inhibitor of matrix metalloproteinases-1 and IL-5, IL-8 in nasal polyps. *Allergy* 2007;62(1):66-72.
 19. Bhandari A, Takeuchi K, Suzuki S, Harada T, Hayashi S, Imanaka-Yoshida K, et al. Increased expression of matrix metalloproteinase-2 in nasal polyps. *Acta Otolaryngol* 2004;124:1165-70.
 20. Andrian E, Mostefaoui Y, Rouabhi M, Grenier D. Regulation of matrix metalloproteinases and tissue inhibitors of matrix metalloproteinases by *Porphyromonas gingivalis* in an engineered human oral mucosa model. *J Cell Physiol* 2007;211(1):56-62.
 21. Christopoulos TA, Papageorgakopoulou N, Ravazoula P, Mastronikolis NS, Papadas TA, Theocharis DA, et al. Expression of metalloproteinases and their tissue inhibitors in squamous cell laryngeal carcinoma. *Oncol Rep* 2007;18(4):855-60.
 22. Xu YP, Zhao XQ, Moubayed P. Correlation of matrix metalloproteinase-2, -9, tissue inhibitor-1 of matrix metalloproteinase and CD44 variant 6 in head and neck cancer metastasis. *J Zhejiang Univ Sci* 2003;4(4):491-501.
 23. Liu WW, Zeng ZY, Wu QL, Hou JH, Chen YY. Overexpression of MMP-2 in laryngeal squamous cell carcinoma: a potential indicator for poor prognosis. *Otolaryngol Head Neck Surg* 2005;132(3):395-400.

Received 27 February 2008, accepted 15 April 2008

Straipsnis gautas 2008 02 27, priimtas 2008 04 15