

## Diagnostic sensitivity and specificity of laryngoscopic signs of reflux laryngitis

Rūta Pribuišienė, Virgilijus Uloza, Limas Kupčinskas<sup>1</sup>

Department of Otorhinolaryngology,

<sup>1</sup>Department of Gastroenterology, Kaunas University of Medicine, Lithuania

**Key words:** reflux laryngitis; laryngoscopy; diagnostics; sensitivity; specificity.

**Summary.** *Objective.* To assess the diagnostic sensitivity and specificity of the laryngoscopic signs of reflux laryngitis.

*Material and methods.* Using original quantitative evaluation system, the laryngoscopic signs of 108 patients with reflux laryngitis and 90 healthy people were subjected to comparative analysis in this study. Summing up all evaluations of laryngeal changes, laryngoscopic reflux index was proposed.

*Results.* Mucosal lesions and edema of vocal cords along with mucosal lesions of the interarytenoid notch were found to be most significant for diagnostics of reflux laryngitis. Presence of mucosal lesions of the interarytenoid notch (roughness, hypertrophy, keratosis, granuloma) increases the odds ratio to attribute the patient to the reflux laryngitis patient group 21 times (OR=21.32, 95% CI 4.38–103.93;  $P<0.001$ ). Mucosal lesions (hypertrophy, keratosis, granuloma) and edema of vocal cords were determined as the most sensitive and rather specific laryngoscopic signs. Roughness and grade II hypertrophy of interarytenoid notch were found to be the most specific (98%) and sensitive (56%) laryngoscopic signs of reflux laryngitis. Abnormal values of laryngoscopic reflux index (higher than 5 points) reflect a diagnostic sensitivity of 96% and specificity of 97% differentiating patients with reflux laryngitis from healthy persons.

*Conclusions.* Mucosal lesions and edema of vocal cords along with mucosal lesions of the interarytenoid notch are found to be the most significant laryngoscopic signs for diagnostics of reflux laryngitis. Laryngoscopic reflux index was found to be the most sensitive and specific diagnostic criterion for reflux laryngitis.

### Introduction

Patients with typical and atypical symptoms of gastroesophageal disease (GERD) appeal both, to the gastroenterologist as well as to the ear, nose, and throat specialists. However, less than 50% of the patients present typical complaints of GERD: heartburn or regurgitation (1, 2). Most of atypical GERD patients suffer from laryngopharyngeal symptoms (hoarseness, throat cleaning, cough, “globus” sensation), accompanied with various GERD-related laryngeal findings that are called reflux laryngitis (RL) (2–4).

GERD-related laryngopharyngeal signs are often established after laryngoscopy, because the most distinct pathological findings occur in the larynx. It depends on physiological and topographical relation between larynx and esophagus (1, 3–6). The entirety of GERD-related pathological findings in the larynx (reflux laryngitis) and concomitant laryngopharyngeal symptoms are considered as laryngopharyngeal form

of GERD (LF GERD) (5).

Reflux laryngitis is acknowledged as one of the most common manifestations of LF GERD (1, 4, 5, 7). However, the data in the literature regarding the diagnostic criteria of RL are rather controversial because of low specificity of laryngoscopic signs and poor correlation between RL and pharyngeal pH-metry findings (8–10). Therefore, the actual scientific and practical needs require to revise the significance of laryngeal findings in order to evaluate the sensitivity and specificity of laryngoscopic signs in diagnostics of RL and to avoid over-diagnosis of the disease.

The aim of this study was to assess the diagnostic sensitivity and specificity of the laryngoscopic signs of reflux laryngitis.

### Patients

The study was carried out at the Departments of Otorhinolaryngology and Gastroenterology, Kaunas

University of Medicine Hospital, Lithuania. A total of 127 consecutive patients who appealed to otorhinolaryngologist because of atypical GERD symptoms (hoarseness, throat clearing, "globus" sensation, throat itching, cough), which lasted more than 3 months, were examined.

After complete examination (video laryngoscopy, esophagoscopy, biopsy taken from the lower third of the esophagus), 108 patients (40 males, 68 females; mean age,  $40.1 \pm 12.9$  years) were diagnosed as GERD-related reflux laryngitis patients. Diagnostic criteria for RL were as follows: 1) complaints mentioned above (other possible reasons of complaints excluded); 2) edema, erythema, hypertrophy of the posterior glottis (arytenoids and interarytenoid notch), vestibular folds and vocal cords; and 3) reflux esophagitis (proven endoscopically and/or histologically).

Reflux esophagitis (RE) according to Los Angeles (1994) classification (11) was proved endoscopically only in 36 of the 108 RL patients (33.3%). However, histologically RE was diagnosed in all 108 cases as the histological signs of RE (12) were found in all biopsy specimens. Nonerosive esophagitis was detected in 107 cases (99%), and erosive esophagitis was diagnosed in 1 case.

In the group of endoscopically proved esophagitis, grade A esophagitis was diagnosed in 72.2% of patients ( $n=26$ ). Grade B esophagitis was not so prevalent and accounted for 27.8% of cases ( $P<0.001$ ) (10).

Consequently, 19 patients without endoscopically and/or histologically proven RE were excluded from the study group despite some laryngoscopic signs of RL were found in these cases.

The control group consisted of 90 randomly selected healthy subjects (36 males, 54 females; mean age,  $36.9 \pm 11.5$  years). They had neither chronic laryngeal diseases nor any other long-lasting voice disorders, and none of them had ever consulted an otolaryngologist concerning the voice problems. In this respect, these persons considered themselves as healthy and therefore they could serve as controls.

The groups of the patients and the controls were dominated by people of 20–60 years of age, who had never undergone any voice training, and who were mostly office workers. The proportions of subjects in these groups did not differ significantly in respect to gender, voice training, social status, and smoking habits ( $P<0.05$ ).

## Methods

The laryngoscopic signs of 108 RL patients and

90 healthy people of the control group were subjected to comparative analysis in this study.

Laryngoscopic examination was carried out during video laryngostroboscopy (VLS) using Kay Elemetrics RLS (model 9100) device with  $70^\circ$  rigid telescope. Mucosal changes in four laryngeal regions – 1) arytenoids (A), 2) the interarytenoid notch (IN), 3) vestibular folds (VF), 4) vocal cords (VC) – were evaluated according to the original quantitative evaluation system of the GERD-related laryngeal findings (13). Three types of mucosal changes were evaluated: 1) mucosal lesions/alteration of the epithelium (reduced mucosal light reflex, hypertrophy, roughness, keratosis, and granuloma), 2) erythema, and 3) edema (Table 1). According to this system, overall 12 laryngoscopic parameters were assessed. For the quantification of the evaluation, the following indices of laryngoscopic signs have been established: arytenoid index (AI), interarytenoid notch index (INI), vestibular fold index (VFI), vocal cord index (VCI). Each index was expressed in appropriate points (Table 1). Summing up all evaluations (indices) of mucosal changes in different laryngeal regions, laryngoscopic reflux index (LRI) was proposed. The possible scores of LRI were from 0 to 20 points.

*Data analysis.* Statistical analysis of the data was performed using SPSS (Statistical Package for Social Sciences) 10.0 for Windows. Nonparametric statistics Mann-Whitney  $U$  test, chi-square and two-tailed  $t$  tests as well as parametric analysis of variance were used. Differences between variables were considered to be reliable if the level of significance  $p$  or  $\alpha$  (type I error) was  $<0.05$  and  $\beta$  (type II error) was  $\leq 0.2$ . When performing analysis of receiver operating characteristics (ROC) curves as presented in the SPSS program, limit (normal/abnormal) values of LRI were established making it possible to differentiate RL patients from healthy persons. Parametric values that were found to be larger than the limiting values were considered as pathological.

Diagnostic specificity and sensitivity of laryngoscopic signs and LRI were calculated. For determination of the most important laryngological signs in the diagnostics of RL, a binary logistic regression was carried out.

## Results

### *Laryngoscopic findings*

When assessing the rate of laryngoscopic findings, it was found that signs of erythema and edema of mucosa of the entire larynx were statistically significantly ( $P<0.001$ ) more common in the group of RL

**Table 1. Evaluation of laryngoscopic findings and calculation of laryngoscopic reflux index (LRI)**

Laryngeal region	Mucosal lesions 0 – no changes 1 – reduced mu- cosa light reflex 2 – hypertrophy 3 – roughness, keratosis 4 – granuloma	Erythema 0 – absent 1 – present	Edema 0 – absent 1 – present	Indices (sum of points)
Arytenoids (A)				Arytenoid index (AI)=(0–4)
Interarytenoid notch (IN) +1, if grade II edema* +2, if grade III edema**				Interarytenoid notch index (INI)=(0–6)
Vestibular folds (VF)				Vestibular fold index (VFI)=(0–4)
Vocal cords (VC)				Vocal cord index (VCI)=(0–6)
				<b>LRI=AI+INI+VFI+VCI (0–20)</b>

\*Tissue fills whole interarytenoid notch.

\*\*Tissue fills interarytenoid notch and prolapses to the vocal gap (according to Koufman, 1994 (14)).

patients to compare with the controls. The same statement applies to the signs of reduced mucosal light reflex of arytenoids (A), vestibular folds (VF), vocal cords (VC) as well as to hypertrophy, roughness, and granuloma of the mucosa of interarytenoid notch (IN), VF, and VC. Mucosal roughness, keratosis, and grade

II–III hypertrophy of IN (14) was found only in the RL patients' group (Table 2). The laryngoscopic findings did not depend on age of the patients ( $P>0.05$ ).

The mean LRI ( $11.78\pm 3.64$  points) of RL patients was found to be significantly greater than the mean LRI in the control group ( $1.70\pm 1.96$  points) ( $\alpha<0.01$ ,

**Table 2. Comparison of the laryngoscopic findings between RL patients (n=108) and controls (n= 90)**

Parameter	Rate of the laryngoscopic findings (abs./%)							
	arytenoids		interarytenoid notch		vestibular folds		vocal cords	
	P	C	P	C	P	C	P	C
Mucosal lesions								
Absent	5/4	72/80*	0/0	65/72*	56/52	90/100*	7/6	83/92*
Reduced mucosa light reflex	47/44	18/20*	18/17	23/26	37/34	0/0*	73/68	7/8*
Grade I hypertrophy of IN**	54/50	0/0*	24/22	2/2*	15/14	0/0*	16/15	0/0*
Roughness, keratosis, grade II hypertrophy of IN*	2/2	0/0	61/56	0/0*	0/0	0/0*	7/6	0/0*
Granuloma/grade III hypertrophy of IN**	0/0	0/0	5/5	0/0*	0/0	0/0*	5/5	0/0*
Erythema								
absent	28/26	73/81*	36/33	86/96*	69/64	90/100*	41/38	84/93*
present	80/74	17/19*	72/67	4/4*	39/36	0/0*	67/62	6/7*
Edema								
absent	9/8	57/63*	0/0	61/68*	73/68	90/100*	13/12	83/92*
present	99/92	33/37*	108/100	29/32*	35/32	0/0*	95/88	7/8*

P – patients, C – controls.

\*Statistically significant difference.

\*\*Hypertrophy of interarytenoid notch (IN) (according to Koufman, 1994 (14)).

**Table 3. Comparison of mean scores of laryngoscopic indices of reflux laryngitis patients and the controls (in points)**

Laryngoscopic index	Patients (N=108)		Controls (N=90)	
	$\bar{x}$	$\pm$ SD	$\bar{x}$	$\pm$ SD
Arytenoid index	3.14*	1.02	0.76	0.89
Interarytenoid notch index	4.28*	1.02	0.67	0.94
Vestibular fold index	1.44*	1.43	0.00	0.00
Vocal cord index	3.01*	1.15	0.26	0.54
Laryngoscopic reflux index	<b>11.78*</b>	3.64	<b>1.70</b>	1.96

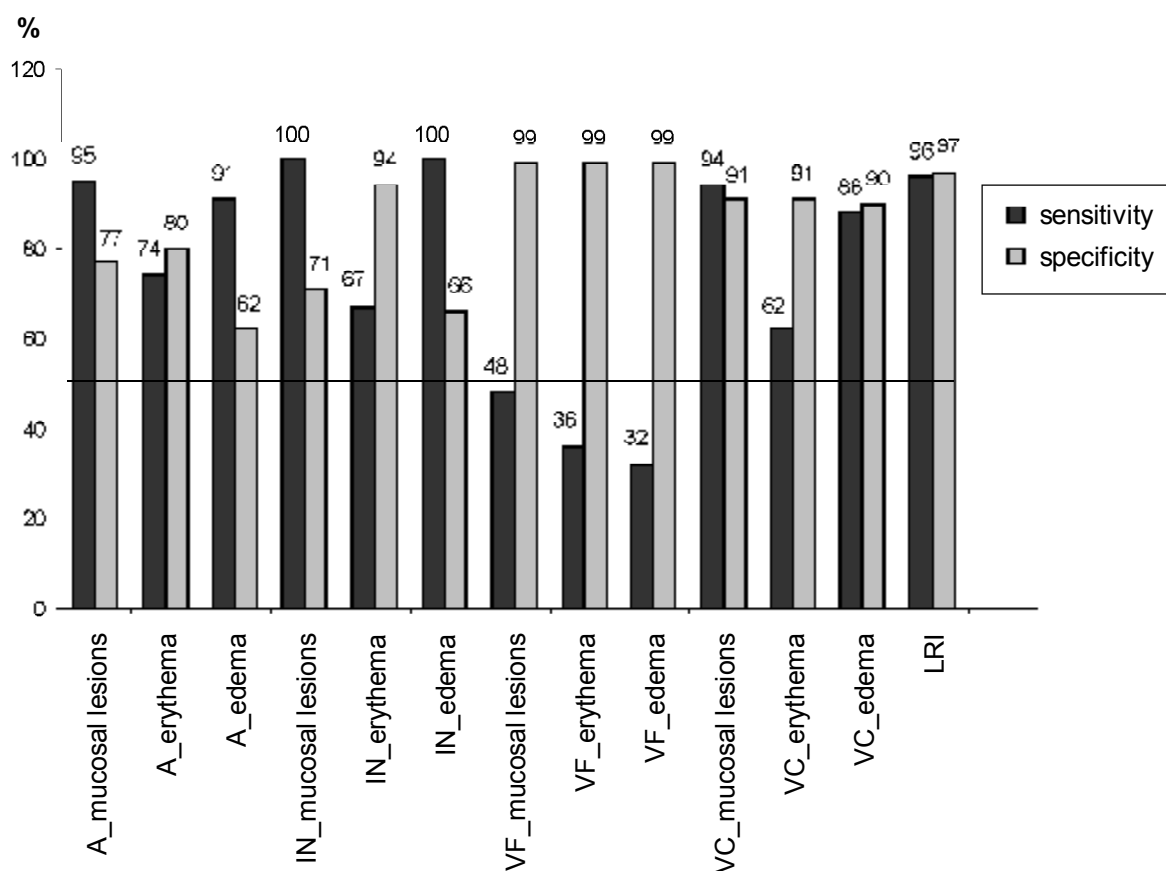
\*Statistically significant difference ( $P < 0.001$ ).

$\beta < 0.05$ ). The mean values of separate laryngoscopic indices reflecting mucosal changes of different laryngeal areas (AI, INI, VFI, and VCI) in the patients' group were statistically significantly higher ( $P < 0.001$ ) to compare with the mean values of these indices in the control group, respectively (Table 3).

The limit LRI value of 5 points differentiating RL patients from healthy persons was determined following analysis of receiver operating characteristics (ROC) curves.

#### The diagnostic sensitivity and specificity of the laryngoscopic signs

As follows from Fig. 1, the diagnostic sensitivity and specificity of 9 out of 12 laryngoscopic signs tested was higher than 50%. Mucosal lesions (reduced mucosal light reflex, hypertrophy, keratosis, granuloma) and edema of VCs were determined as the most sensitive and rather specific laryngoscopic signs, *i.e.* diagnostic specificity of these signs was 90–91%. Mucosal lesions and edema of interarytenoid notch

**Fig. 1. Diagnostic sensitivity and specificity of the laryngoscopic signs of reflux laryngitis**

A – arytenoids; IN – interarytenoid notch; VF – vestibular folds; VC – vocal cords;  
LRI – laryngoscopic reflux index.

(IN) were the most sensitive laryngoscopic findings. However, the limits of diagnostic specificity of these signs varied from 66% (edema) to 71% (mucosal lesions). According to the statistical analysis data, roughness and grade II hypertrophy of IN (14) were found to be the most specific (98%) and sensitive (56%) laryngoscopic signs of RL.

However, from the diagnostic point of view, the LRI itself as the resumptive of all laryngoscopic signs was found to be the most sensitive and specific. Abnormal values of LRI (higher than 5 points) corresponded to a diagnostic sensitivity of 96% and specificity of 97%.

***The most important laryngoscopic signs for diagnosing reflux laryngitis established by logistic regression analysis***

Logistic regression analysis revealed the following three laryngoscopic signs that were the most significant for diagnosing of GERD-related reflux laryngitis:

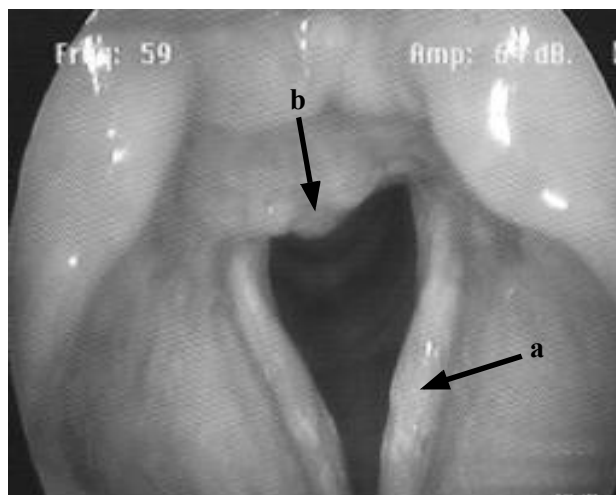1. Mucosal lesions of vocal cords: reduced mucosa light reflex, hypertrophy, roughness, keratosis, granuloma,
2. Edema of vocal cord,
3. Mucosal lesions of the interarytenoid notch: reduced mucosa light reflex, roughness, hypertrophy, granuloma (Fig. 2).

The combination of these three laryngoscopic signs separates reliably ( $P < 0.05$ ) the RL patients from healthy persons in 95.9% of cases.

As the result of analysis of the data, it was established that mucosal lesions of the interarytenoid notch (hypertrophy, roughness, granuloma) have the highest diagnostic value among the investigated laryngoscopic signs diagnosing RL (Table 4). Presence of mucosal lesions of the IN increases the odds ratio to attribute the patient to the RL patients' group 21 times ( $OR = 21.32$ , 95% CI 4.38–103.93;  $P < 0.001$ ).

### Discussion

It has been reported in the literature that among the patients seeking help for otolaryngologist, up to



**Fig. 2. The most significant laryngoscopic signs of RL**

- a – reduced mucosa light reflex, hypertrophy, roughness, keratosis, and edema of vocal cords;  
b – reduced mucosa light reflex, roughness, hypertrophy of interarytenoid notch.

10% of persons were found to have reflux-related symptoms, *i.e.* possible LF GERD (3, 15). Therefore, diagnostics of LF GERD remains a rather complicated clinical problem. Despite the attempts to use contemporary, sophisticated, and “objective” methods of diagnostics, the result is quite disappointing.

Many studies have clearly showed that 24-h esophageal pH monitoring unfortunately is not a perfect “gold standard” for diagnosing atypical GERD (16–18). Overall, only 54% of patients with suspected GERD and related laryngoscopic signs present abnormal esophageal acid exposure, irrespective of the location of the pH probe (distal, proximal esophagus or hypopharyngeal) (18). Majority of the patients (60–70%) with laryngeal symptoms related to suspected GERD have normal esophageal endoscopies (1, 7, 13, 19). Therefore, an empirical treatment with proton pump inhibitors is not always successful in cases of atypical GERD unresponsive to treatment (8, 20, 21).

As reflux laryngitis (RL) is considered as one of the most common manifestations of LF GERD, diagnostics of that clinical entity appears as one of “key

**Table 4. The most important laryngoscopic signs of GERD-related reflux laryngitis**

Parameter	P	Odds ratio	95% CI
Edema of vocal cords	0.011	10.393	1.695–63.707
Mucosal lesions of the interarytenoid notch	<0.001	21.324	4.375–103.929
Mucosal lesions of vocal cord	0.004	13.299	2.234–79.181

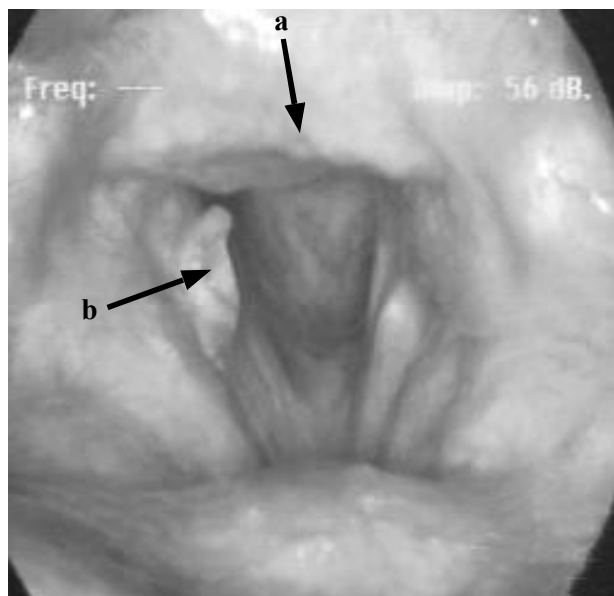
stones” solving the problem. However, controversy in the literature regarding the diagnostic criteria of RL makes the task even more complicated (8–10). Some studies resume the mucus stasis, erythema, edema, hypertrophy, ulceration, and granulation of the posterior larynx (arytenoids, interarytenoid notch) as sufficient for diagnostics of RL (22, 23). However, Koufman (1991) postulates that RL may present as erythema, edema, and epithelial changes in all parts of the larynx while rather subjectively evaluated signs as mucosal edema and erythema (89% and 87%, respectively) are predominant (1). On the other hand, pathological changes in posterior larynx typical for RL may present also among persons without GERD (10, 24, 25). According to Reulbach study (n=100), signs of RL were determined in 64% of the community-based cohort of adults over 40 years of age. Only 12% of examined persons had a completely normal laryngeal examination (25). Moreover, some laryngoscopic signs of RL (laryngeal tissue irritation) were found in 85–87% healthy volunteers in Hicks’ (n=105) and Vavricka’s (n=132) studies (10, 24).

There could be several reasons explaining discrepancy among the laryngoscopic findings mentioned above: different patients’ inclusion and exclusion criteria, distinction in assessment of the laryngoscopic findings, different laryngoscopic techniques used (flexible or rigid laryngoscope). Milstein *et al.* (2005) revealed that laryngeal signs of RL were more likely to be detected using flexible than rigid laryngoscopy in the same individual (75% vs. 54%) (26).

Data of the present study stress on completeness of assessment of laryngoscopic signs of RL. Despite the fact that roughness and grade II hypertrophy of IN (Fig. 3) were found to be specific (98%) and sensitive (56%) laryngoscopic signs of RL, only the LRI was found to be the most sensitive and specific from the diagnostic point of view. Abnormal values of LRI (higher than 5 points) corresponded to a diagnostic sensitivity of 96% and specificity of 97%.

According to the data of logistic regression analysis, the following three laryngoscopic signs were found to be the most significant for diagnostics of GERD related RL: a) mucosal lesions of vocal cords (reduced mucosa light reflex, hypertrophy, roughness, keratosis, granuloma), b) edema of vocal cords, and c) mucosal lesions of the interarytenoid notch (reduced mucosa light reflex, roughness, hypertrophy, granuloma). Combination of these three laryngoscopic signs separates reliably the RL patients from healthy persons in 95.9% of cases.

On the other hand, data of the present study confirmed the highest diagnostic value of mucosal lesions



**Fig. 3. Reflux laryngitis**

a – mucosal roughness and grade II hypertrophy of interarytenoid notch; b – vocal cord granuloma.

of the interarytenoid notch (hypertrophy, roughness, granuloma) among the investigated laryngoscopic signs diagnosing RL. The odds ratio to attribute the patient to the RL patients group increases 21 times in case of presence of mucosal lesions of the interarytenoid notch.

To increase the reliability of diagnostics of RL, we should be more careful and incredulous evaluating sensitive but less specific laryngeal and rather “subjective” signs such as mucosal edema and erythema and rely on more evident and “objective” signs such as mucosal lesions (hypertrophy, roughness, keratosis, granuloma) like it was done by gastroenterologists turning away from Hetzel’s to Los Angeles classification of the esophagitis (27).

## Conclusions

1. Laryngoscopic reflux index is sensitive and specific tool for the diagnostics of reflux laryngitis. Abnormal values of laryngoscopic reflux index (higher than limiting laryngoscopic reflux index value of 5 points) reflect a diagnostic sensitivity of 96% and specificity of 97% differentiating patients with reflux laryngitis from healthy persons.

2. Mucosal lesions and edema of vocal cords along with mucosal lesions of the interarytenoid notch are found to be the most significant for diagnostics of gastroesophageal reflux disease-related reflux laryngitis. Presence of mucosal lesions of the interarytenoid notch increases the odds ratio to attribute the patient to the reflux laryngitis patients’ group 21 times.

## Refliuksinio laringito laringoskopinių požymių diagnostinis jautrumas ir specifiškumas

Rūta Pribuišienė, Virgilijus Uloza, Limas Kupčinskas<sup>1</sup>

Kauno medicinos universiteto Ausų, nosies ir gerklės ligų klinika, <sup>1</sup>Gastroenterologijos klinika

**Raktažodžiai:** refliuksinis laringitas, laringoskopija, diagnostika, jautrumas, specifiškumas.

**Santrauka.** *Tyrimo tikslas.* Įvertinti refliuksinio laringito laringoskopinių požymių diagnostinį jautrumą ir specifiškumą.

*Tyrimo medžiaga ir metodai.* Naudojant originaliai sukurta kiekybinę sistemą, išanalizuoti ir palyginti 108 pacientų, sergančių refliuksiniu laringitu, ir 90 sveikų kontrolinės grupės tiriamųjų laringoskopiniai požymiai. Susumavus visus gerklų gleivinės pokyčius, apskaičiuotas laringoskopinis reflukso indeksas.

*Rezultatai.* Refliuksinio laringito diagnostikai reikšmingiausi balso klosčių ir tarpvedeginės išpjovos gleivinės pokyčiai bei balso klosčių edema. Tarpvedeginės išpjovos gleivinės pokyčiai (grublėtumas, hipertrofija, keratozė, granuloma) šansų santykį sirgti refliuksiniu laringitu didina 21 kartą ( $\bar{S}S=21,32$ , 95 proc. PI 4,38–103,93;  $p<0,001$ ). Jautriausi ir specifiskiausi laringoskopiniai požymiai buvo balso klosčių gleivinės pokyčiai (hipertrofija, keratozė, granuloma) ir edema. Patys specifiskiausi (98 proc.) ir jautriausi (56 proc.) buvo tarpvedeginės išpjovos gleivinės grublėtumas ir antrojo laipsnio hipertrofija. Patologinės laringoskopinio reflukso indekso reikšmės (daugiau kaip 5 balai) pasižymėjo 96 proc. diagnostiniu jautrumu ir 97 proc. specifiškumu atskiriant sergančiuosius refliuksiniu laringitu nuo sveikų tiriamųjų.

*Išvados.* Balso klosčių ir tarpvedeginės išpjovos gleivinės pokyčiai ir balso klosčių edema yra svarbiausi refliuksinio laringito diagnostiniai požymiai. Laringoskopinis reflukso indeksas yra jautriausias ir specifiskiausias refliuksinio laringito diagnostinis kriterijus.

Adresas susirašinėti: R. Pribuišienė, KMU Ausų, nosies ir gerklės ligų klinika, Eivenių 2, 50009 Kaunas  
El. paštas: ruta-prib@takas.lt

### References

1. Koufman JA. The otolaryngologic manifestations of gastroesophageal reflux disease (GERD): a clinical investigation of 225 patients using ambulatory 24-hour pH monitoring and an experimental investigation of the role of acid and pepsin in the development of laryngeal injury. *Laryngoscope* 1991;101 (Pt 2 Suppl 53):1-78.
2. Vaezi MF. Atypical manifestations of gastroesophageal reflux disease. *MedGenMed* 2005;7(4):25.
3. Farrokhi F, Vaezi MF. Laryngeal disorders in patients with gastroesophageal reflux disease. *Minerva Gastroenterol Dietol* 2007;53(2):181-7.
4. Pribuišienė R, Uloza V, Kupčinskas L, Jonaitis L. Perceptual and acoustic characteristics of voice changes in reflux laryngitis patients. *J Voice* 2006;20(1):128-36.
5. Pribuišienė R, Uloza V, Šiupšinskienė N, Butkus E, Kupčinskas L. Suaugusių žmonių gastroezofaginio reflukso ligos laringofaringinės formos diagnostika (klinikinės praktinės nuorodos). (Diagnostics of laryngopharyngeal form of gastroesophageal reflux disease for adults (Lithuanian clinical practice guidelines).) *Medicina (Kaunas)* 2007;43(6): 508-15.
6. Jailwala JA, Shaker R. Reflux laryngitis. Online e-medicine "Otolaryngology and facial plastics surgery" textbook. Available from: URL: [www.emedicine.com](http://www.emedicine.com)
7. Jonaitis L, Pribuišienė R, Kupčinskas L, Uloza V. Laryngeal examination is superior to endoscopy in the diagnosis of the laryngopharyngeal form of gastroesophageal reflux disease. *Scand J Gastroenterol* 2006;41(2):131-7.
8. Vaezi MF. Are there specific laryngeal signs for gastroesophageal reflux disease? *Am J Gastroenterol* 2007;102(4): 723-4.
9. Joniau S, Bradshaw A, Esterman A, Carney AS. Reflux and laryngitis: a systematic review. *Otolaryngol Head Neck Surg* 2007;136(5):686-92.
10. Vavricka SR, Storck CA, Wildi SM, Tutuian R, Wiegand N, Rousson V, et al. Limited diagnostic value of laryngopharyngeal lesions in patients with gastroesophageal reflux during routine upper gastrointestinal endoscopy. *Am J Gastroenterol* 2007;102(4):716-22.
11. Dent J, Brun J, Fendrick AM, Fennerty MB, Janssens J, Kahrilas PJ, et al. An evidence-based appraisal of reflux disease management – the Genval Workshop Report. *Gut* 1999; 44(Suppl 2):S1-16.
12. Haggitt RC. Histopathology of reflux-induced esophageal and supraesophageal injuries. *Am J Med* 2000;6(108 Suppl 4a):109S-11S.
13. Pribuišienė R. Laringologinių tyrimų reikšmė diagnozuojant gastroezofaginio reflukso ligos laringofaringinę formą. (The importance of laryngological examination diagnosing laryngopharyngeal form of gastroesophageal reflux disease.) [dissertation]. Kaunas: KMU; 2003.
14. Koufman JA, Cummins MM. The prevalence and spectrum of reflux in laryngology: a prospective study of 132 consecutive patients with laryngeal and voice disorders. 1994. Available from: URL: [http://www.bgsmd.edu/voice/reflux\\_prev\\_study.html](http://www.bgsmd.edu/voice/reflux_prev_study.html)
15. Hopkins C, Yousaf U, Pedersen M. Acid reflux treatment for

- hoarseness. Cochrane Database Syst Rev 2006;(1):CD005054.
16. Vaezi MF. Review article: the role of pH monitoring in extraesophageal gastro-oesophageal reflux disease. *Aliment Pharmacol Ther* 2006;23 Suppl 1:40-9.
  17. Ahmed T, Vaezi MF. The role of pH monitoring in extraesophageal gastroesophageal reflux disease. *Gastrointest Endosc Clin N Am* 2005;15(2):319-31.
  18. Vaezi MF, Hicks DM, Abelson TI, Richter JE. Laryngeal signs and symptoms and gastroesophageal reflux disease (GERD): a critical assessment of cause and effect association. *Clin Gastroenterol Hepatol* 2003;1(5):333-44.
  19. Vaezi MF. Laryngitis and gastroesophageal reflux disease: increasing prevalence or poor diagnostic tests? *Am J Gastroenterol* 2004;99(5):786-8.
  20. Swoger J, Ponsky J, Hicks DM, Richter JE, Abelson TI, Milstein C, et al. Surgical fundoplication in laryngopharyngeal reflux unresponsive to aggressive acid suppression: a controlled study. *Clin Gastroenterol Hepatol* 2006;4(4):433-41.
  21. Qadeer MA, Swoger J, Milstein C, Hicks DM, Ponsky J, Richter JE, et al. Correlation between symptoms and laryngeal signs in laryngopharyngeal reflux. *Laryngoscope* 2005;115(11):1947-52.
  22. Rodríguez-Téllez M, Galera-Ruiz H, Argüelles-Arias F, Carmona I, Muñoz-Borje F, Herrerías JM. Posterior laryngitis: effects of treatment with omeprazole alone. *Rev Esp Enferm Dig* 2002;94(3):123-30.
  23. Ylitalo R, Lindestad PA, Ramel S. Symptoms, laryngeal findings, and 24-hour pH monitoring in patients with suspected gastroesophago-pharyngeal reflux. *Laryngoscope* 2001;111(10):1735-41.
  24. Hicks DM, Ours TM, Abelson TI, Vaezi MF, Richter JE. The prevalence of hypopharynx findings associated with gastroesophageal reflux in normal volunteers. *J Voice* 2002;16(4):564-79.
  25. Reulbach TR, Belafsky PC, Blalock PD, Koufman JA, Postma GN. Occult laryngeal pathology in a community-based cohort. *Otolaryngol Head Neck Surg* 2001;124(4):448-50.
  26. Milstein CF, Charbel S, Hicks DM, Abelson TI, Richter JE, Vaezi MF. Prevalence of laryngeal irritation signs associated with reflux in asymptomatic volunteers: impact of endoscopic technique (rigid vs. flexible laryngoscope). *Laryngoscope* 2005;115(12):2256-61.
  27. Ford CN. Evaluation and management of laryngopharyngeal reflux. *JAMA* 2005;294(12):1534-40.

*Received 21 January 2008, accepted 18 April 2008*

*Straipsnis gautas 2008 01 21, priimtas 2008 04 18*